



HAL
open science

Spectral domain optical coherence tomography detects early stages of chloroquine retinopathy similar to multifocal electroretinography, fundus autofluorescence and near-infrared autofluorescence

Simone Kellner, Silke Weinitz, Ulrich Kellner

► **To cite this version:**

Simone Kellner, Silke Weinitz, Ulrich Kellner. Spectral domain optical coherence tomography detects early stages of chloroquine retinopathy similar to multifocal electroretinography, fundus autofluorescence and near-infrared autofluorescence. *British Journal of Ophthalmology*, 2009, 93 (11), pp.1444-n/a. 10.1136/bjo.2008.157198 . hal-00477846

HAL Id: hal-00477846

<https://hal.science/hal-00477846>

Submitted on 30 Apr 2010

HAL is a multi-disciplinary open access archive for the deposit and dissemination of scientific research documents, whether they are published or not. The documents may come from teaching and research institutions in France or abroad, or from public or private research centers.

L'archive ouverte pluridisciplinaire **HAL**, est destinée au dépôt et à la diffusion de documents scientifiques de niveau recherche, publiés ou non, émanant des établissements d'enseignement et de recherche français ou étrangers, des laboratoires publics ou privés.

Spectral domain optical coherence tomography detects early stages of chloroquine retinopathy similar to multifocal electroretinography, fundus autofluorescence and near-infrared autofluorescence

Simone Kellner^{1,2}, Silke Weinitz¹, Ulrich Kellner^{1,2}

¹AugenZentrum Siegburg, Europaplatz 3, 53721 Siegburg, Germany;

²RetinaScience, PostCode 301212, 53192 Bonn, Germany;

Key words: retina, electrophysiology, imaging, drugs

Financial relationship: none for all authors

Word count: 1357

Correspondence:

S. Kellner, M.D,

AugenZentrum Siegburg

RetinaScience

Europaplatz 3

53721 Siegburg

Germany

T: +49 2241 844050

F: +49 228 4224367

E: simonekellner@mac.com

Abstract

Aims: To compare spectral domain optical coherence tomography (sdOCT) to melanin-related near-infrared fundus autofluorescence (NIA, excitation 787nm, emission >800nm), lipofuscin-related fundus autofluorescence (FAF, excitation 488nm, emission >500nm) and multifocal electroretinography (mfERG) in patients with long-term chloroquin (CQ) treatment.

Methods: Eight patients with 5.5-22 years of CQ treatment underwent clinical examination, mfERG recording, FAF and NIA imaging using a confocal scanning laser ophthalmoscope (Heidelberg Retina Angiograph 2) and sdOCT imaging (Spectralis OCT Heidelberg Retina Angiograph).

Results: In three patients all test results were normal after 5.5-16 years of CQ treatment. Five patients presented with variably progressed CQ retinopathy (10-22 years of treatment) and abnormalities in all tests. In the mildest case, pericentral reduction of mfERG amplitudes corresponded to increased pericentral FAF, reduced pericentral NIA and pericentral interruption of the photoreceptor inner/outer segment junction in the sdOCT. In all sdOCT scans outer nuclear layer thickness was reduced. More severe cases showed preserved subfoveal photoreceptors and function with marked changes in all examinations towards the periphery. The most severe case presented with additional loss of subfoveal photoreceptors.

Conclusion: MfERG, FAF, NIA and sdOCT detect early stages of CQ retinopathy. Loss of outer nuclear layer thickness might be the earliest indicator of CQ retinopathy.

Abbreviations:

CQ: chloroquine, FAF: fundus autofluorescence, HCQ: hydroxychloroquine, mfERG: multifocal electroretinography, NIA: near-infrared fundus autofluorescence, sdOCT: spectral domain optical coherence tomography

INTRODUCTION

Chloroquine (CQ) and hydroxychloroquine (HCQ) play an important role in the treatment of systemic autoimmune disorders due to their limited side effects. Their major disadvantage is the induction of an irreversible retinal degeneration, which may lead to severe loss of visual fields and visual acuity and subsequent loss of drivers license and occupation. Although the risk of retinal degeneration increases with the duration of treatment, recent findings show that many patients may take CQ or HCQ for many years without problems, whereas few patients develop retinal photoreceptor dysfunction at very low cumulative doses [1]. The reason for this variability remains to be established.

In animal experiments earliest abnormalities were detected in retinal ganglion cells, but in both animal experiments and histology of human retinas paracentral photoreceptors showed the most severe damage. [2-4] In recent years, retinal dysfunction or retinal structural abnormalities have been identified sometimes prior to ophthalmoscopically visible alterations using multifocal electroretinography (mfERG), [5-7] fundus autofluorescence (FAF), [5] near-infrared autofluorescence (NIA), [8] time domain optical coherence tomography (OCT) [8] and a prototype of high speed ultra-high-resolution OCT. [9]

Screening for the onset of CQ/HCQ retinopathy is difficult due to the huge number of patients under treatment, unspecific early symptoms (e.g. reading difficulties) and limited availability and high costs for sophisticated diagnostic methods. In the present study we compare commercially available spectral domain OCT (sdOCT) with mfERG, FAF and NIA in different stages of long-term CQ retinopathy and demonstrate that all methods may detect early stages of CQ retinopathy.

PATIENTS AND METHODS

Eight female patients with long-term CQ treatment examined at the Augenzentrum Siegburg were included in this study. All patients were of normal weight at the time of presentation. Results of previous examinations have been reported [5, 8] in some patients that were asked to return for repeated examination including sdOCT (Table 1). Three patients were asymptomatic

undergoing regular screening for CQ therapy, whereas five patients had subjective symptoms of visual dysfunction. In these patients, the diagnosis of CQ retinopathy was established based on patient and family history, ophthalmoscopy, visual field testing and mfERG recording according to the standards of the International Society for Clinical Electrophysiology of Vision as reported previously. [5, 10, 11] All patients gave informed consent after detailed explanation about the background of the study. The study was performed in adherence to the tenets of the Declaration of Helsinki and approved by the local ethics committee.

FAF and NIA images were obtained as reported previously using a confocal scanning laser ophthalmoscope (Heidelberg Retina Angiograph 2, Heidelberg Engineering, Heidelberg, Germany)[5, 8, 12, 13]. Spectral domain OCT (sdOCT) was performed with the Spectralis OCT HRA (Heidelberg Engineering, Heidelberg, Germany) according to the manufacturers guidelines using single line mode as well as with 18 scans from the posterior pole using 3D mode.

FAF, NIA and sdOCT images were evaluated in comparison to normal images. MfERG recordings were judged based on age-matched laboratory normal values. [5]

RESULTS

Patients without CQ retinopathy

In three patients (#2587, 2596, 2702) with CQ treatment over a period of 6 – 16 years (Table 1) the structure of all retinal layers appeared normal in all regions in the sdOCT on both eyes (Fig. 1). FAF and NIA imaging as well as visual acuity, visual fields and the multifocal ERG were also normal bilaterally in all three patients.

Table 1

Patient ID	Age at examination [years]	Duration CQ [years]	Estimated cumulative Dose [g]	Visual acuity OD / OS
Normal				
2702 ¹	31	16	1460	1.0 / 1.0
2587	59	6	548	1.0 / 1.0
2596 ¹	50	5.5	502	1.0 / 1.0
CQ retinopathy				
3108	51	22 ⁺	1350 ⁺	1.0 / 1.0
2771 ²	53	20	1825	0.7 / 0.8
2688 ^{1*}	60	14	1278	1.0 / 1.0
2858 ²	47	10	912	0.5 / 0.5
3033	68	10	912	0.1 / 0.2

¹Previous findings reported in [5]

²Previous findings reported in [8]

⁺treatment was partly interrupted in some years

*Patient developed CQ retinopathy since the previously reported normal findings

Patients with CQ retinopathy

In five patients (#2688, 2771, 2858, 3033, 3108) with CQ treatment over a period of 3 – 20 years (Table 1) marked retinal structural abnormalities were detected using sdOCT. These patients had noted subjective signs of CQ retinopathy prior to the first detailed examination using retinal imaging. In the patient with the mildest sdOCT changes (#3108, 22 years of interrupted CQ treatment) parafoveal discontinuity of the photoreceptor inner / outer segment junction was observed (Fig. 1). In the three patients (#2688, 2771, 2858) with more advanced CQ retinopathy the foveal photoreceptors were preserved, whereas towards the periphery the layers of the outer segments, the photoreceptor inner / outer segment junction and the outer nuclear layer could no longer be distinguished (Fig. 1). The alterations were most severe in patient #2858 with 10 years of CQ treatment, less severe in patient #2771 with 20 years of treatment and even lesser in patient #2688 with 14 years of treatment. In the patient with the most severe sdOCT abnormalities (#3033, 10 years CQ

treatment) the foveal and parafoveal region showed severe loss of photoreceptor associated layers.

All patients with retinal structural abnormalities in the sdOCT showed also alterations of FAF, NIA and mfERG (Fig. 1). The severity corresponded to the severity of sdOCT changes.

An additional sdOCT finding in patient #3108 was the general reduction of outer nuclear layer thickness (Fig. 2). Throughout the complete scan series the thickness of the outer nuclear layer was reduced compared to a group of 7 age-related female probands (e.g. most superior scan: #3108: 46.7 μm (mean \pm 1 standard deviation: 59.8 \pm 7.1 μm), most inferior scan: #3108: 38.3 μm (51.7 \pm 5.2 μm). This is of interest as the most superior and inferior sdOCT scans correspond to retinal areas which appeared normal on ophthalmoscopy, FAF, NIA and showed normal amplitudes in the mfERG.

DISCUSSION

Patients usually tolerate CQ or HCQ treatment well and often have to change to drugs with more frequent side effects when CQ/HCQ therapy has to be discontinued. Therefore it is important to reliably diagnose early stages of CQ/HCQ retinopathy. The present study shows that in our patients with CQ treatment mfERG, FAF, NIA and sdOCT were either normal or all tests showed at least mild abnormalities. In patients with CQ retinopathy the alterations of the photoreceptor layers documented with the sdOCT included loss of photoreceptor inner segments indicated by the reduced outer nuclear layer thickness and the interruption or absence of the photoreceptor inner/outer segment junction. These findings are in agreement with a previous report using a research type of high-definition OCT. [9] These structural retinal alterations correspond to photoreceptor dysfunction demonstrated with the mfERG and an increase of the lipofuscin concentration and a decrease of the melanin concentration in the RPE as seen in FAF and NIA images [14], which have been reported previously. [8]

It is of importance to note that in the sdOCT the outer nuclear layer shows the most severe changes. Similar changes could be seen on a previous report of OCT alterations.[9] At present, all of the patients examined in both of these studies

who presented with sdOCT abnormalities had already visual problems. It is of interest, that even in the patient with the mildest sdOCT changes the outer nuclear layer thickness was reduced in all scans of the 3D series. These changes were detectable in areas where ophthalmoscopy, FAF and NIA appeared normal and mfERG responses were normal as well. Prospective evaluation of outer nuclear layer thickness during CQ/HCQ treatment might provide even earlier suspicion of the onset of retinal degeneration.

Based on this limited comparative series, each of the methods appears to detect already milder changes of CQ retinopathy. Similar changes have been reported in HCQ retinopathy using mfERG, FAF and high resolution OCT, it can be concluded that these methods also facilitate early diagnosis of HCQ retinopathy. This is of importance, because not all diagnostic techniques are easily accessible everywhere. As there is no obvious diagnostic advantage of one of the four methods, each might be used when CQ retinopathy is suspected. Characteristic findings confirm the diagnosis, whereas in cases of doubt the other methods can be used to clarify the diagnosis.

The Corresponding Author has the right to grant on behalf of all authors and does grant on behalf of all authors, an exclusive licence (or non-exclusive for government employees) on a worldwide basis to the BMJ Publishing Group Ltd and its Licensees to permit this article (if accepted) to be published in British Journal of Ophthalmology and any other BMJ PGL products to exploit all subsidiary rights, as set out in our licence

REFERENCES

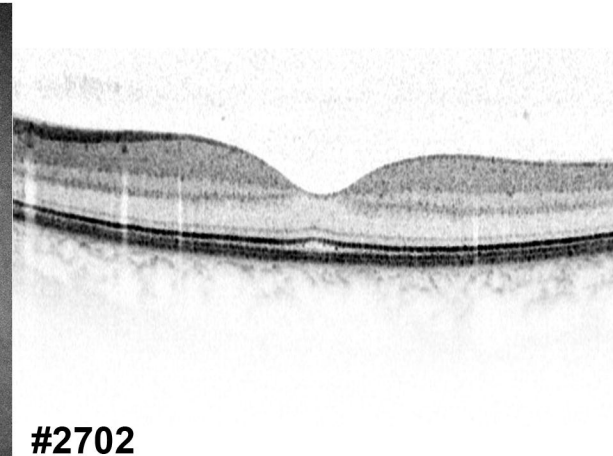
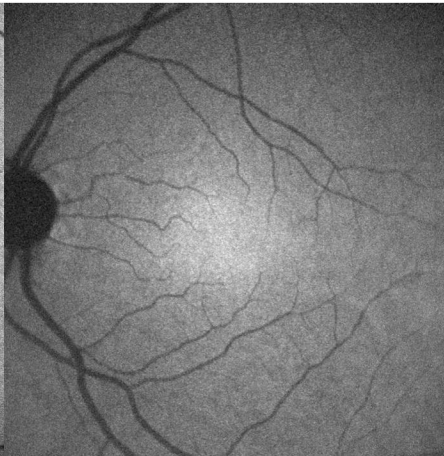
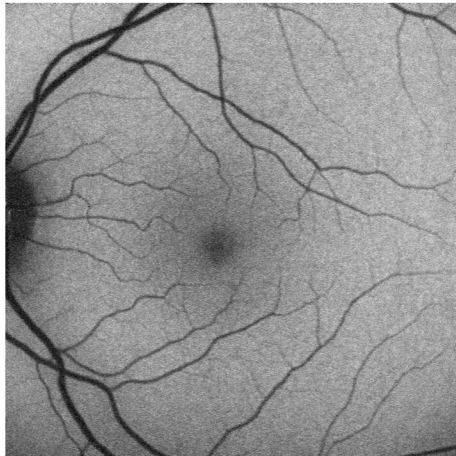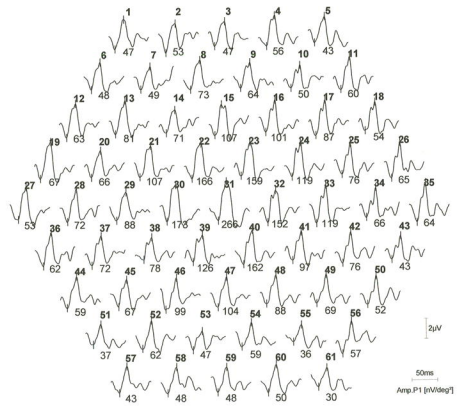
1. Ruther K, Foerster J, Berndt S, Schroeter J: **Variabilität der retinotoxischen Gesamtdosis Chloroquin/Hydroxychloroquin.** *Ophthalmologe* 2007, **104**:875-879.
2. Bernstein HN, Ginsberg J: **The Pathology of Chloroquine Retinopathy.** *Arch Ophthalmol* 1964, **71**:238-245.
3. Wetterholm DH, Winter FC: **Histopathology of Chloroquine Retinal Toxicity.** *Arch Ophthalmol* 1964, **71**:82-87.
4. Rosenthal AR, Kolb H, Bergsma D, Huxsoll D, Hopkins JL: **Chloroquine retinopathy in the rhesus monkey.** *Invest Ophthalmol Vis Sci* 1978, **17**(12):1158-1175.
5. Kellner U, Renner AB, Tillack H: **Fundus autofluorescence and mfERG for early detection of retinal alterations in patients using chloroquine/hydroxychloroquine.** *Invest Ophthalmol Vis Sci* 2006, **47**(8):3531-3538.
6. Penrose PJ, Tzekov RT, Sutter EE, Fu AD, Allen AW, Jr., Fung WE, Oxford KW: **Multifocal electroretinography evaluation for early detection of retinal dysfunction in patients taking hydroxychloroquine.** *Retina* 2003, **23**(4):503-512.
7. Lai TY, Chan WM, Li H, Lai RY, Lam DS: **Multifocal electroretinographic changes in patients receiving hydroxychloroquine therapy.** *Am J Ophthalmol* 2005, **140**(5):794-807.
8. Kellner U, Kellner S, Weinitz S: **Chloroquine retinopathy: lipofuscin- and melanin-related fundus autofluorescence, optical coherence tomography and multifocal electroretinography.** *Doc Ophthalmol* 2008, **116**(2):119-127.
9. Rodriguez-Padilla JA, Hedges TR, 3rd, Monson B, Srinivasan V, Wojtkowski M, Reichel E, Duker JS, Schuman JS, Fujimoto JG: **High-speed ultra-high-resolution optical coherence tomography findings in hydroxychloroquine retinopathy.** *Arch Ophthalmol* 2007, **125**(6):775-780.
10. Marmor MF, Holder GE, Seeliger MW, Yamamoto S: **Standard for clinical electroretinography (2004 update).** *Doc Ophthalmol* 2004, **108**(2):107-114.
11. Marmor MF, Hood DC, Keating D, Kondo M, Seeliger MW, Miyake Y: **Guidelines for basic multifocal electroretinography (mfERG).** *Doc Ophthalmol* 2003, **106**(2):105-115.
12. Renner AB, Tillack H, Kraus H, Kohl S, Wissinger B, Mohr N, Weber BH, Kellner U, Foerster MH: **Morphology and functional characteristics in adult vitelliform macular dystrophy.** *Retina* 2004, **24**(6):929-939.
13. Kellner U, Kellner S, Weber BH, Fiebig B, Weinitz S, Ruether K: **Lipofuscin- and melanin-related fundus autofluorescence visualize different retinal pigment epithelial alterations in patients with retinitis pigmentosa.** *Eye* 2008:Epub ahead of print.
14. Gibbs D, Cideciyan AV, Jacobson SG, Williams DS: **Retinal pigment epithelium defects in humans and mice with mutations in MYO7A: imaging melanosome-specific autofluorescence.** *Invest Ophthalmol Vis Sci* 2009:Epub ahead of print

Legends

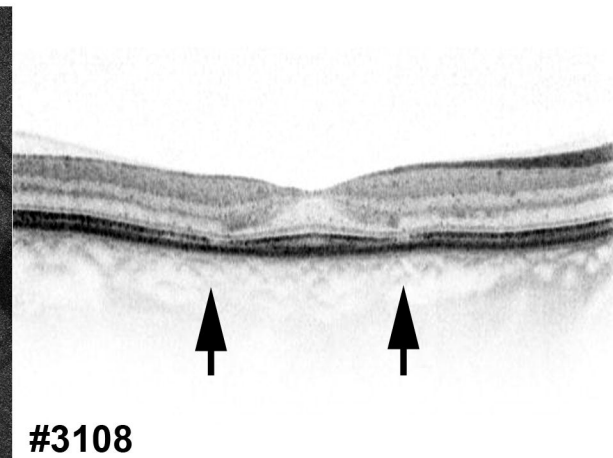
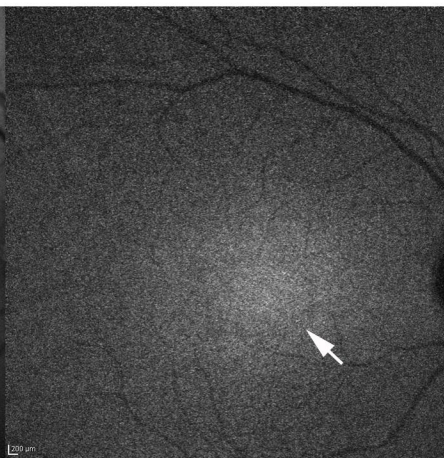
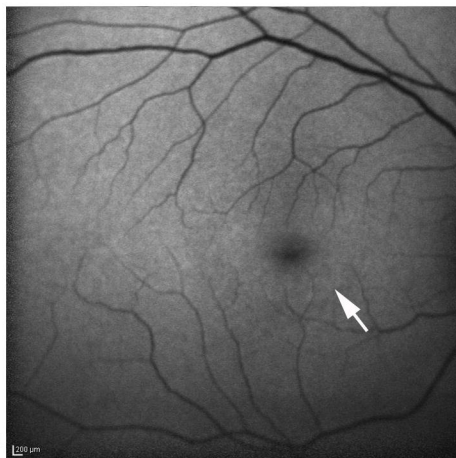
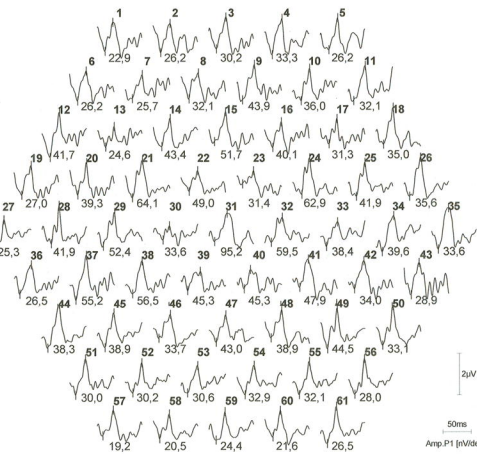
Figure 1: Multifocal ERG (mfERG), fundus autofluorescence (FAF), near-infrared autofluorescence (NIA) and central spectral domain OCT (sdOCT) scans in different stages of CQ retinopathy. Upper row (patient #2702 with long duration CQ therapy without retinopathy): Normal mfERG amplitudes, normal FAF distribution with low central FAF intensity, normal NIA distribution with high central NIA intensity and normal structure of retinal layers in the sdOCT. Middle row (patient #3108 with mild CQ retinopathy): Pericentral mfERG amplitude reduction (ring 2), pericentral increase of FAF intensity (arrow), pericentral fine reduction of NIA intensity (arrow) and pericentral interruption of photoreceptor inner /outer segment junction (arrows). Lower row (patient #2688 with advanced CQ retinopathy): Marked mfERG amplitude reduction, broad pericentral area of increased FAF (between arrows), marked reduction of NIA intensity and preservation of subfoveal photoreceptors and loss of pericentral and more peripheral photoreceptor layers in the sdOCT in.

Figure 2: Fundus reflectance image and upper sdOCT scan of patient #3108 compared to normal sdOCT. The sdOCT shows reduced outer nuclear layer thickness (black bars indicate the outer nuclear layer) in CQ retinopathy compared to two scans of age-matched normal female eyes in the same area.

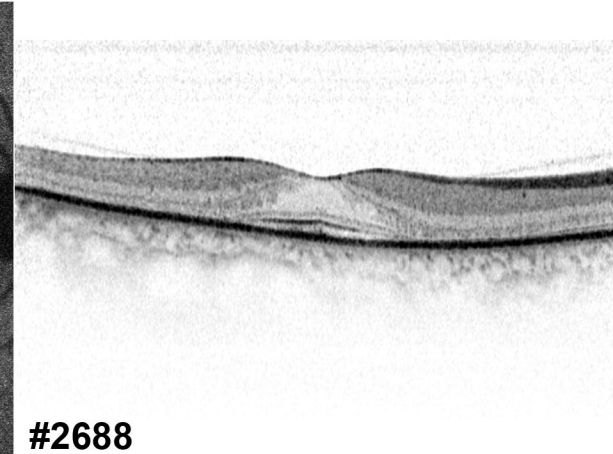
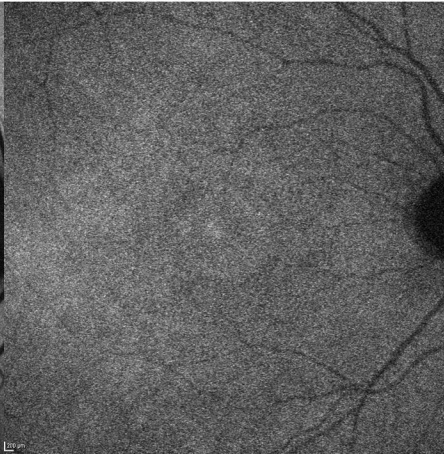
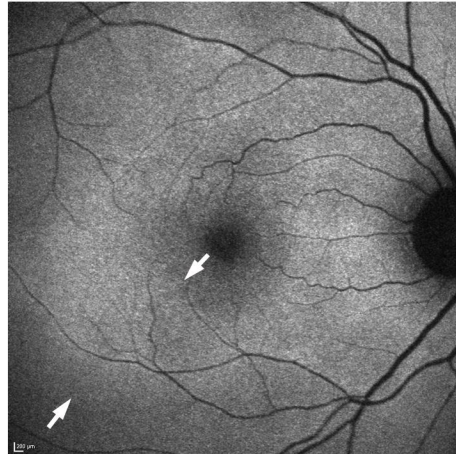
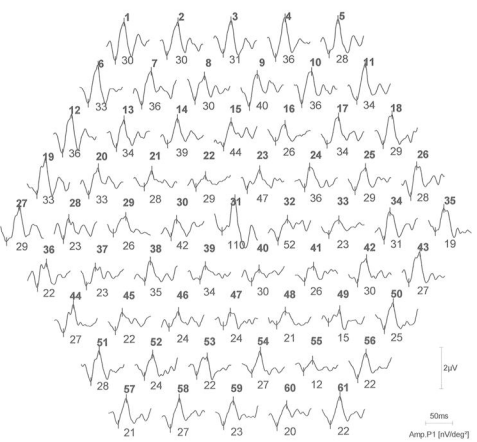
mfERG



#2702



#3108



#2688

