HAL
open science

Penetration of topical and sub-conjunctival corticosteroids into human aqueous humour and its therapeutic significance

Muhammad Amer Awan, Pankaj Kumar Agarwal, D G Watson, Charles N J Mcghee, Gordon N Dutton

To cite this version:

Muhammad Amer Awan, Pankaj Kumar Agarwal, D G Watson, Charles N J Mcghee, Gordon N Dutton. Penetration of topical and sub-conjunctival corticosteroids into human aqueous humour and its therapeutic significance. British Journal of Ophthalmology, 2009, 93 (6), pp.708-n/a. 10.1136/bjo.2008.154906 . hal-00477841

HAL Id: hal-00477841

https://hal.science/hal-00477841v1

Submitted on 30 Apr 2010

HAL is a multi-disciplinary open access archive for the deposit and dissemination of scientific research documents, whether they are published or not. The documents may come from teaching and research institutions in France or abroad, or from public or private research centers.

L'archive ouverte pluridisciplinaire **HAL**, est destinée au dépôt et à la diffusion de documents scientifiques de niveau recherche, publiés ou non, émanant des établissements d'enseignement et de recherche français ou étrangers, des laboratoires publics ou privés.

Penetration of topical and sub-conjunctival corticosteroids into human aqueous humour and its therapeutic significance

Corresponding author:

MA Awan

Ophthalmology Dept

Tennent Institute of Ophthalmology, Gartnavel General Hospital

1053 Great Western Rd, Glasgow G12 0YN. United Kingdom

E-mail: dramer_awan@yahoo.co.uk

Tel No. +44 141 2112934

Fax No. +44 14 1 211 2054

Co authors:

PK Agarwal

Tennent Institute of Ophthalmology, Glasgow. UK

DG Watson

Strathclyde Institute of Pharmacy and Biomedical Sciences (SIPBS), University of Strathclyde, Glasgow. UK

Charles NJ McGhee

Dept of Ophthalmology, University of Auckland, Auckland. New Zealand

GN Dutton

1) Tennent Institute of Ophthalmology, Glasgow. UK
2) Department of Vision Sciences, Glasgow Caledonian University, Glasgow. UK
3) The Royal Hospital for Sick Children, Yorkhill, Glasgow.UK

Key words: Corticosteroids, aqueous penetration, topical steroids, subconjunctival injection, hydrophilic compounds, hydrophobic compounds.

Word Count: 3092 including the table

Competing interests: none declared

Licence for Publication

The Corresponding Author has the right to grant on behalf of all authors and does grant on behalf of all authors, an exclusive licence (or non exclusive for government employees) on a worldwide basis to the BMJ Publishing Group Ltd to permit this article (if accepted) to be published in BJO and any other BMJPGL products and sublicences such use and exploit all subsidiary rights, as set out in our licence
(http://bjo.bmj.com/ifora/licence.pdf).

Abstract:

Topical and subconjunctival corticosteroids are one of the most effective and compelling treatment options in ocular inflammatory diseases. A systematic review of literature indexed by Ovid MEDLINE & EMBASE was performed up to December 2008. There are few studies on their aqueous penetration in human subjects. In this review article we discussed the penetration of different ocular corticosteroids into human aqueous humour along with the therapeutic implications on management of ocular surface diseases, immune related corneal diseases, anterior uveitis and postoperative anti inflammatory use. In the context of the paucity of well-constructed, prospective clinical trials comparing the efficacy of different corticosteroids, it provides guiding principles for the use of topical corticosteroids. Dexamethasone alcohol 1% and prednisolone acetate 1% are potent corticosteroids but the latter achieves the highest aqueous concentration within 2 hours and maintains higher levels for 24 hours. Subconjunctival corticosteroids provide very high concentrations in the aqueous which maintain higher concentrations for longer periods.

Introduction:

Corticosteroids, used cautiously, are one of the most potent and effective modalities of treatment available for ocular inflammation.[1] Systemic corticosteroids were introduced into ophthalmic clinical practice in the 1950s as a major advance in the control of ocular inflammation.[2] However, within a few years, a number of ophthalmic adverse effects, such as cataract and elevated intraocular pressure (IOP), had been reported.[3-7] In order to optimize ocular drug delivery, while minimizing systemic adverse events, a diverse range of topical drops, ointments, delayed-release topical vehicles, intraocular, periocular and oral corticosteroid preparations have been developed over the last 65 years.[8] However, despite the continuing development of techniques and vehicles for local administration of corticosteroids, both systemic and ocular adverse events continue to be reported with dermatological, inhaled and ocular corticosteroid preparations.[9-14] Although non-steroidal anti-inflammatory drugs have been shown to challenge the therapeutic efficacy of corticosteroids in a number of ophthalmic conditions without the associated risk of elevated IOP, decreased wound strength or predisposition to infection,[15-17] topical corticosteroids remain a fundamental component of the ophthalmic therapeutic armamentarium.

Most topically applied corticosteroids penetrate the eye via the cornea.[18] Corneal penetration studies conducted in un-anaesthetized albino rabbits have described transfer through the epithelium as the rate limiting step for drug absorption for hydrophilic compounds, whereas transfer through the stroma is rate limiting for hydrophobic compounds. However, very low molecular weight compounds demonstrate rapid uptake into the aqueous humour despite the lipid-like barrier imposed by the corneal epithelium. These results parallel the findings of similar *in vivo* studies and are consistent with a currently proposed 'pore' model for the penetration of drugs through the cornea which demonstrates both a partition coefficient and molecular weight dependency on the permeability of the cornea to transported compounds.[19] This view can be supported by *in vitro* observations of the penetration of hydrocortisone, conjugated to polyethylene glycols of increasing chain length, through bovine cornea.[20] In a rabbit model study corneal penetration of dexamethasone was increased after photorefractive surgery[21] whereas in another animal study there was no difference in penetration after photorefractive keratectomy.[22]

The clinical benefits and adverse events associated with corticosteroid preparations have been well documented but their basic pharmacokinetics in the human eye have yet to be fully elucidated. An increasing amount of literature has addressed this issue, particularly over the last 20 years.[8,23-31] Much of the knowledge of these drugs has been gained by obtaining data from rabbit models,[32-48] but on account of differences in anatomy, and technical aspects of experimental studies, animal results can vary significantly from human studies. Such differences include the thinner rabbit cornea, lower rabbit blink rate, the effect of general anaesthetic, the effect of upright or recumbent position, the vascularity of the rabbit orbital plexus and the small rabbit body mass.[45,49-51] It has also been demonstrated that the rabbit cornea becomes significantly less permeable with age, particularly for large hydrophilic compounds,[52] suggesting that direct extrapolation from data on young laboratory animals to the elderly human cornea is of limited value. In general, measurements of corticosteroid concentration in rabbit eyes [32, 36, 40, 53-56] tend to be significantly higher than those recorded in humans.[23-29]

In relation to systemic administration, the local administration of ocular corticosteroids theoretically enables the use of smaller doses for equivalent or greater local corticosteroid concentration, more target-specific drug application, and reduced risk of systemic adverse events. The minimal effective concentration of corticosteroid for treating different ocular inflammatory conditions has not been established for the commonly used corticosteroid formulations but the highest concentrations in human aqueous humour (1130 ng/ml maximal level) have been recorded following topical application of 1% prednisolone acetate.[27] This review article discusses the penetration of different ocular corticosteroids into human aqueous humour along with the therapeutic implications of these findings. A systematic review of literature indexed by Ovid MEDLINE & EMBASE was performed up to December 2008.

Penetration of topical ocular corticosteroids into human aqueous humour: (see table and figure)

Dexamethasone alcohol 0.1%

Dexamethasone alcohol 0.1% *[Maxidex, Alcon]* is an effective topical corticosteroid and its penetration into the aqueous humour of human subjects has been evaluated by using gas

chromatography combined with mass spectrometry (GCMS). Dexamethasone achieved its peak concentration in aqueous humour between 91 and 120 minutes following instillation (mean concentration, 31 ng/ml) and was still detectable in the aqueous 12 hours after instillation.[23]

Dexamethasone-cyclodextrin-polymer co-complex 0.32%:

In another human study an aqueous drop containing dexamethasone-cyclodextrin-polymer co-complexes 0.32% *[Dexamethasone, Sigma Chemical; 2-hydroxypropyl-β- cyclodextrin, Wacker-Chemie; hydroxypropyl methylcellulose, Mecobenzon]* was used in the patients undergoing cataract surgery. By performing liquid chromatography, it was demonstrated that this formulation improved the aqueous humour penetration of dexamethasone (mean concentration of 140 ng/ml in 150 minutes) approximately 2.6 fold, when compared with dexamethasone alcohol 0.1% (Maxidex, Alcon), by enhancing both solubility in the formulation vehicle and permeability through the cornea.[24]

Dexamethasone disodium phosphate 0.1%:

Weijtens et al measured dexamethasone disodium phosphate 0.1% *[brand name not given]* concentration in aqueous humour, vitreous and serum by means of radioimmunoassay. The mean dexamethasone concentrations in the aqueous humor, vitreous, and serum were 30.5 ng/ml (range, 7.1-57.7 ng/ml), 1.1 ng/ml (range, 0.0-1.6 ng/ml), and 0.7 ng/ml (range, 0.0-1.2 ng/ml), respectively.[25] Interestingly in spite of being a hydrophilic preparation it performs as well as the preceding dexamethasone preparation which is lipophilic. These results indicated that the penetration of dexamethasone into vitreous humor after repeated drop application was small in comparison to sub-conjunctival administration, which was 72.5 ng/ml.[57] Despite frequent instillation the dexamethasone concentration in the aqueous humor was far lower than after a subconjunctival injection with dexamethasone disodium phosphate.[25]

Prednisolone acetate 1%:

McGhee et al utilised GCMS to measure the intra-ocular penetration of prednisolone acetate 1% *[Predforte, Allergen]* into the aqueous humour of human volunteers undergoing routine cataract extraction.[26] A mean peak concentration of 669.9 ng/ml was attained within two hours of

application and levels of 28.6 ng/ml were still detected more than 24 hours after instillation of one drop. Acetate was largely converted to prednisolone alcohol during passage through the cornea.[26] In a separate study, a single standardized drop of 1.0% prednisolone acetate *[Econopred plus, Alcon]* labeled with tritiated thymidine was administered topically to one eye of 58 patients shortly before elective cataract extraction. By using scintillation spectrometer, peak drug concentration in aqueous humor was 1130 ng/ml, which occurred 30 to 45 minutes after instillation of the medication.[27]

Prednisolone sodium phosphate 0.5%:

GCMS has also been utilised to determine the penetration of topically applied prednisolone sodium phosphate 0.5% *[Predsol, Glaxo]* into human aqueous humour. Detectable levels of prednisolone were measured in the aqueous humour within 15 minutes of administration. Peak aqueous concentrations of 25.6 ng/ml were much lower than those achieved by topical prednisolone acetate 1.0% and occurred between 90 and 240 minutes. The corticosteroid could not be detected in samples taken 10 hours or more after topical administration.[28]

Betamethasone sodium phosphate 0.1%:

Watson et al also used GCMS to determine the absorption of topically applied betamethasone sodium phosphate 0.1% *[Betnesol, Glaxo]* into the aqueous humour of human subjects undergoing routine intraocular surgery. The betamethasone concentration was greatest in the interval 91-120 minutes following topical administration (mean peak concentration = 7.7 ng/ml). However, at 12 hours post instillation the mean concentration of betamethasone was 2.5 ng/ml and detectable levels were still measureable in the aqueous humour 24 hours after application (mean concentration 0.4 ng/ml).[29]

Fluorometholone alcohol 0.1%:

The penetration of fluorometholone alcohol 0.1% *[FML, Allergan]* into aqueous humour was determined using the GCMS. The peak aqueous humour level of fluorometholone was 5.1 ng/ml between 31 -60 minutes and significant concentrations of fluorometholone (mean level 4.3 ng/ml) were detected between 181 – 240 minutes.[26] These levels are very low when compared

with the levels resulting from application of the equivalent strength 0.1% dexamethasone drops. There are no further studies to inform of its concentration after 10 hours.

Loteprednol etabonate 0.2% & 0.5%:

Loteprednol, is a so called 'soft' steroid, belongs to a unique class of corticosteroids with a metabolically labile 17β-chloromethyl ester, which is designed to be hydrolysed to a metabolically inactive carboxylic acid moiety.[58] In a rabbit eye study, concentrations of loteprednol etabonate and its metabolites were highest in the cornea, and so was the ratio of metabolites to unchanged drug, suggesting that the primary site of deactivation of the topically applied drug is the corneal tissue. A substantial amount of metabolites was also detected in the iris-ciliary body, although these were lower than in the cornea. The amount of drug and metabolites in the aqueous humour was low.[58] Unfortunately, to date no published human studies have determined its aqueous humour concentration following topical application.

Clobetasone butyrate 0.1% & betamethasone phosphate ointment 0.1%:

The concentrations of clobetasone butyrate 0.1% *[Eumovate, Glaxo]* and betamethasone phosphate 0.1% *[Betnesol, Glaxo]* have been measured by a radioimmunoassay technique in aqueous humour of patients undergoing cataract extraction 12.5 to 18.5 hours after application into the lower conjunctival sac of an ointment of the respective corticosteroid. Samples were assayed from 10 patients receiving clobetasone butyrate and 13 patients receiving betamethasone phosphate. There were measurable concentrations in only 2 aqueous samples in the former group, and both were 0.1 ng/ml. In the betamethasone group measurable aqueous concentrations were identified in 11 samples, the concentration ranged from 0.5 to 20.3 ng/ml and the highest concentration was found between 12.5 and 13.5 hours after application.[31]

Hydrocortisone acetate 2.5% & dexamethasone sodium phosphate 0.4%:

The concentration of corticosteroids in aqueous humour was measured at various intervals after sub-conjunctival injection in a series of 130 patients undergoing cataract extraction by utilizing by spectro-colorimeter. Hydrocortisone acetate *[Wycort, 0.5 ml of 2.5 per cent solution]* and dexamethasone sodium phosphate *[Dexona, 0.5 ml of 0.4 per cent solution]* attained peak concentrations in the aqueous of 214.4 and 268.0 µg/ml respectively within 10 minutes.

Dexamethasone showed a uniformly higher penetration up to 24 hours (123 µg/ml) but the hydrocortisone effect lasted longer (20.5 µg/ml) for up to 7 days.[30]

Table: Comparison of human aqueous humour concentration of corticosteroids following topical and subconjunctival application:

Drug	**Route**	**Dose (No. of drops)**	**No. Of subjects**	**Mean Peak Aqueous Concentration (ng/ml)**	**Time to Peak (min)**	**At 12 hours (ng/ml)**	**At 24 hours (ng/ml)**	**Reference**
Dexamethasone Alcohol	Drops	0.1% (1)	64	31	90 to 120	3.1	N/A†	23
Dexamethasone-cyclodextrin-polymer co-complex	Drops	0.32% (1)	47	140	150	N/A†	N/A†	24
Dexamethasone disodium phosphate	Drops	0.1%(10)	10	30.5	55	N/A†	N/A†	25
Prednisolone Acetate	Drops	1% (1)	66	669.9	120	99.5	28.4	26
Prednisolone Acetate	Drops	1% (1)	58	1130	30-45	N/A†	N/A†	27
Prednisolone Sodium Phosphate	Drops	0.5% (1)	93	25.6	90-240	0	N/A†	28
Betamethasone Phosphate	Drops	0.5% (1)	66	7.7	90-120	2.5	0.4	29
Fluorometholone Alcohol	Drops	0.1% (1)	22	5.1	31-60	N/A†	N/A†	26
Clobetasone Butyrate	Ointment	0.1% (1)	10	0.1	810	0.1	N/A†	31
Betamethasone Phosphate	Ointment	0.1% (1)	13	20.3	810	20.3	N/A†	31
Hydrocortisone Acetate 2.5%	Subconjunctival	0.5ml (1)	130	214×10^3	10	N/A†	103×10^3	30
Dexamethasone Sodium Phosphate 0.4%	Subconjunctival	0.5ml (1)	130	268×10^3	10	N/A†	123×10^3	30

†N/A: not available

Therapeutic implications in the management of anterior segment diseases:

It is important, when comparing data concerning penetration of corticosteroids into aqueous humour to consider that systemic anti-inflammatory effect of both betamethasone and dexamethasone is five to seven times that of prednisolone. [59, 60] The local anti-inflammatory potency of ocular corticosteroids has yet to be fully investigated, and while early work suggested that prednisolone acetate 1% had the greatest anti-inflammatory effect in experimental keratitis,[44] subsequent studies demonstrated that fluorometholone acetate in a 1% formulation was equally efficacious in the same model.[61] No data are yet available to determine the optimal corticosteroid concentrations required in various ocular inflammatory diseases. In the context of the paucity of well-constructed, prospective clinical trials comparing the efficacy of different corticosteroids, the above studies can be employed to provide guiding principles for the use of topical corticosteroids and for future trial design. To our knowledge there is no literature which compares relative efficacy of generic with branded topical steroids.

Ocular surface use:

Ocular surface diseases require corticosteroids to control inflammation and various types of topical corticosteroids are used. Fluorometholone alcohol 0.1% and loteprednol etabonate 0.5% are mild corticosteroids with low intraocular penetration.[26, 58] It has been established that fluorometholone alcohol, which has a low likelihood of elevating IOP and penetrates into human aqueous humour to a lesser extent than prednisolone or dexamethasone, [8]undergoes local ocular metabolism and consequent inactivation in the cornea.[62] According to corticosteroid penetration studies, fluorometholone alcohol 0.1%, loteprednol etabonate 0.5% , betamethasone phosphate 0.5% and prednisolone sodium phosphate 0.5% can be used for ocular surface diseases. In two different randomized controlled trial (RCT) loteprednol etabonate has shown excellent results in seasonal allergic and giant papillary conjunctivitis with minimal risk of transient intraocular pressure rise.[63, 64] Dexamethasone alcohol 0.1% and prednisolone sodium phosphate 0.5% are also used in allergic and atopic conjunctivitis depending on its severity but there are no trials so far to compare these preparations.

Eyelid margin disease with secondary conjunctival and corneal involvement is well characterised in adults and is termed blepharokeratoconjunctivitis. It has been treated with topical antibiotics

along with flouromethalone alcohol 0.1%, or prednisolone sodium phosphate 0.5% but there is no clinical evidence to show comparative effectiveness.[65]

Episcleritis is idiopathic in the majority of cases, however very rarely there is an association with an underlying systemic disease like rheumatoid arthritis. Jab et al has described in a case series that fluorometholone 0.1% worked well in most of cases and if there was no response to treatment, then prednisolone acetate 1% was recommended.[66]

The role of topical corticosteroids in the management of ocular alkali burns remains controversial. Alkaline chemical burns vary in intensity and may be treated with preservative free prednisolone disodium phosphate 0.5% or dexamethasone sodium phosphate 0.1% along with other standardized treatment regimes during the first week following trauma. In an animal study Donshick *et al* found that topical corticosteroids if used from day 6 to day 21 following the injury were associated with an increase in number and severity of corneal ulceration.[67] Although in the case series by Davis et al have reported a study in which topical corticosteroids were used for longer duration with improved outcomes but oral vitamin C was used as an adjunct. [68]

Dry eye is a multifactorial ocular surface disease with various manifestations and degrees of severity. Some individuals manifest mild or episodic symptoms that are easily controlled with an ocular lubricant. Others present with severe complications from keratoconjunctivitis sicca. Although not without associated risks, Avunduk et al [69] have reported a randomised controlled trial that primarily surface active topical corticosteroids such as fluorometholone alcohol 0.1% have a clear beneficial effect both on the subjective and objective clinical parameters of moderate-to-severe dry eye patients. These effects were associated with the reduction of the inflammation markers of conjunctival epithelial cells. [69]

Immune mediated corneal diseases and anterior uveitis:

According to the above drug penetration studies, prednisolone acetate 0.1% and dexamethasone alcohol 0.1% have good aqueous penetration and can be used in immune related corneal diseases and anterior uveitis.

The exact aetiology of disciform keratitis is controversial but it may be an infection of associated keratocytes and endothelium or an exaggerated hypersensitivity response to viral antigen (herpes simplex/ zoster). In double masked randomized trial Power et al have shown that the cumulative rate of healing was better and quicker in the steroid group (betamethasone 0.1%) when compared with the placebo group.[70] However; it is not known how this affects the recurrence rate of active herpetic disease.

In anterior uveitis steroids are used to quell the inflammatory response. This is achieved by using a topical corticosteroid and a frequency depending on the severity of inflammation. Prednisolone acetate 1% or dexamethasone 0.1% is often the drug of first choice. Corticosteroid ointments such as betamethasone 0.1% or dexamethasone 0.1% are helpful at night. In very severe anterior uveitis, subconjunctival injection of dexamethasone sodium phosphate 0.4% is useful as it can attain and maintain high aqueous concentration for 24 hours.[30] The corticosteroids with poor aqueous penetration are not very effective for the control of intraocular inflammation. Loteprednol etabonate 0.5% has been compared to prednisolone acetate 1% and was less effective than prednisolone acetate. However, the more favourable profile of loteprednol etabonate with respect to IOP increase may make it useful in many patients.[71] Rimexolone 1% ophthalmic suspension was almost as effective as prednisolone acetate in the patients with anterior uveitis but prednisolone acetate was more likely to cause increase in IOP.[72]

Postoperative use:

Prednisolone acetate 1% and dexamethasone alcohol 0.1% are the common topical corticosteroids which are used to control inflammation postoperatively. Prednisolone acetate 1% achieves its highest aqueous level (669.9 ng/ml) within 120 minutes and maintains a significant level throughout 24 hours. Whereas dexamethasone alcohol 0.1% and dexamethasone phosphate 0.1% attain peak aqueous levels (30.5 - 31 ng/ml; 20 times less than that of prednisolone acetate) within 55 to 120 minutes and detectable levels are seen at 12 hours.

Although dexamethasone is a more potent anti -inflammatory steroid than prednisolone with a greater binding affinity for glucocorticoid receptors, using non-invasive anterior chamber

fluorophotometry in RCT, it was not possible to demonstrate any significant difference in its efficacy in protecting the blood-aqueous barrier after cataract extraction and posterior chamber lens implantation when compared to prednisolone acetate.[73] Thus twice daily application of prednisolone acetate 1% may be suitable for uncomplicated postoperative cataract cases. In another randomized study 0.7% dexamethasone-cyclodextrin aqueous eye drops applied once daily was a more effective postoperative anti-inflammatory medication than 0.1% dexamethasone sodium phosphate applied three times a day.[74]

Conclusion:

Ocular corticosteroids are widely used to control inflammation in different ocular conditions. The corneal penetration and resultant aqueous humour concentrations are well known for the most of ocular corticosteroids in humans, and in the absence of clinical trials, this knowledge can be used to provide further guidance. However, we still do not know the degree of penetration of these steroids into the aqueous humour in the inflamed eye. Unfortunately corticosteroid induced glaucoma and cataract is a potential complication in susceptible individuals, and injudicious use of topical corticosteroids in ocular infection carries significant morbidity. The risk of glaucoma is relatively reduced with the new class of topical corticosteroids like loteprednol etabonate and rimexolone but their absorption and anti inflammatory effects are also decreased. Topical, subconjunctival, and sub-tenon application of corticosteroids are preferable to systemic administration in anterior segment diseases depending on the severity and level of inflammation. The aqueous penetration of topical corticosteroids, their expected molar potencies and possible side effects can provide advice in their judicious use.

References:

[1]McGhee CN, Dean S, Danesh-Meyer H. Locally administered ocular corticosteroids: benefits and risks. Drug Saf 2002; **25**:33-55.

[2] Raizman M. Corticosteroid therapy of eye disease. Fifty years later. Arch Ophthalmol 1996; **114**: 1000-1.

[3] Valerio M. The hazards of prolonged local cortisone therapy. Bull Mem Soc Fr Ophtalmol 1963; **76**: 572-80.

[4] Black RL, Oglesby RB, von Sallmann L et al. Posterior subcapsular cataracts induced by corticosteroids in patients with rheumatoid arthritis. JAMA 1960; **174**: 166-71.

[5] Covell LL. Glaucoma induced by systemic steroid therapy. Am J Ophthalmol 1958; **45**: 108-9.

[6] Becker B, Mills DW. Elevated intraocular pressure following corticosteroid eye drops. JAMA 1963; **185**: 884-6.

[7] Urban RC Jr, Cotlier E. Corticosteroid-induced cataracts. Surv Ophthalmol 1986; **31**: 102-10.

[8] McGhee CN. Pharmacokinetics of ophthalmic corticosteroids. Br J Ophthalmol 1992; **76**: 681-4.

[9] Hill CJ, Rostenberg A Jr. Adverse effects from topical steroids. Cutis 1978; **21**: 624-8.

[10] Lipworth BJ. Systemic adverse effects of inhaled corticosteroid therapy: a systematic review and meta-analysis. Arch Intern Med 1999; **159**: 941-55.

[11] Garbe E, Suissa S, LeLorier J. Association of inhaled corticosteroid use with cataract extraction in elderly patients. JAMA 1998; **280**: 539-43.

[12] Mitchell P, Cumming RG, Mackey DA. Inhaled corticosteroids, family history, and risk of glaucoma. Ophthalmology 1999; **106**: 2301-6.

[13] Salminen L. Review: systemic absorption of topically applied ocular drugs in humans. J Ocul Pharmacol 1990; **6**: 243-9.

[14] Carnahan MC, Goldstein DA. Ocular complications of topical, peri-ocular, and systemic corticosteroids. Curr Opin Ophthalmol 2000; **11**: 478-83.

[15] Flach AJ, Jaffe NS, Akers WA. The effect of ketorolac tromethamine in reducing postoperative inflammation: double-mask parallel comparison with dexamethasone. Ann Ophthalmol 1989; **21**: 407-11.

[16] Othenin-Girard P, Tritten JJ, Pittet N et al. Dexamethasone versus diclofenac sodium eye drops to treat inflammation after cataract surgery. J Cataract Refract Surg 1994; **20**: 9-12.

[17] Koay P. The emerging roles of topical non-steroidal anti-inflammatory agents in ophthalmology. Br J Ophthalmol 1996; **80**: 480-5.

[18] Rosenblum C, Dengler Jr RE, Geoffroy RF. Ocular absorption of dexamethasone phosphate disodium by the rabbit. Arch Ophthalmol 1967; **77**: 234-7.

[19] Grass GM, Robinson JR. Mechanisms of corneal drug penetration. I: In vivo and in vitro kinetics. J Pharm Sci 1988; **77**:3-14.

[20] Foroutan SM, Watson DG. The in vitro evaluation of polyethylene glycol esters of hydrocortisone 21-succinate as ocular prodrugs. Int J Pharm 1999; **182**: 79-92.

[21] Maitchouk D, Smirennaia E, Kourenkov V. Corneal pharmacodynamics after photorefractive keratectomy and laser in situ keratomileusis in rabbits. J Refract Surg 2002; **18:S382**-4.

[22] McDermott ML, Vale S, Tayfour F, Cowden JW. The intraocular penetration of dexamethasone after photorefractive keratectomy. Ophthalmic Surg Lasers 1998; **29**:839-41.

[23] Watson D, Noble MJ, Dutton GN et al. Penetration of topically applied dexamethasone alcohol into human aqueous humor. Arch Ophthalmol 1988; **106**:686-7.

[24] Kristinsson JK, Fridriksdóttir H, Thórisdóttir S et al. Dexamethasone-cyclodextrin-polymer co-complexes in aqueous eye drops. Aqueous humor pharmacokinetics in humans. Invest Ophthalmol Vis Sci 1996; **37**:1199-203.

[25] Weijtens O, Schoemaker RC, Romijn FP et al. Intraocular penetration and systemic absorption after topical application of dexamethasone disodium phosphate. Ophthalmology 2002; **109**:1887-91.

[26] McGhee CN, Watson DG, Midgley JM et al. Penetration of synthetic corticosteroids into human aqueous humour. Eye 1990; **4**:526-30.

[27] Leibowitz HM, Berrospi AR, Kupferman A et al. Penetration of topically administered prednisolone acetate into the human aqueous humor. Am J Ophthalmol 1977; **83**:402-6.

[28] McGhee CN, Noble MJ, Watson DG et al. Penetration of topically applied prednisolone sodium phosphate into human aqueous humour. Eye 1989; **3**:463-7.

[29] Watson DG, McGhee CN, Midgley JM et al. Penetration of topically applied betamethasone sodium phosphate into human aqueous humour. Eye 1990; **4**:603-6.

[30] Jain MR, Srivastava S. Ocular penetration of hydrocortisone and dexamethasone into the aqueous humour after subconjunctival injection. Trans Ophthalmol Soc U K. 1978; **98**:63-5.

[31] Debnath SC, Richards AB. Concentration of clobetasone butyrate in aqueous humour. Br J Ophthalmol 1983; **67**:203-5.

[32] Leopold IH, Kroman HS. Methyl and fluoro substituted prednisolones in the blood and aqueous humor of the rabbit. Concentrations. Arch Ophthalmol 1960; **63**: 943-7.

[33] Wine NA, Gornall AG, Basu PK. The ocular uptake of subconjunctivally injected C14 hydrocortisone. Part 1. Time and major route of penetration in a normal eye. Am J Ophthalmol 1964; **58**: 362-6.

[34] McCartney HJ, Drysdale IO, Gornall AG et al. An autioradiographic study of the penetration of subconjunctivally injected hydrocortisone into the normal and inflamed rabbit eye. Invest Ophthalmol 1965; **4**: 297-302.

[35] Murdick PW, Keates RH, Donovan EF et al. Ocular penetration studies. II. Topical administration of prednisolone. Arch Ophthalmol 1966; **76**: 602-3.

[36] Short C, Keates RH, Donovan EF et al. Ocular penetration studies. I. Topical administration of dexamethasone. Arch Ophthalmol 1966; **75**: 689-92.

[37] McDonald TO, Kasten K, Hervey R et al. Comparative toxicity of dexamethasone and its tertiary butyl acetate ester after topical ocular instillation in rabbits. Am J Ophthalmol 1973; **76**: 117-25.

[38] Krupin T,Waltman SR, Becker B. Ocular penetration in rabbits of topically applied dexamethasone. Arch Ophthalmol 1974; **92**: 312-4.

[39] Kupferman A, Pratt MV, Suckewer K et al. Topically applied steroids in corneal disease. 3. The role of drug derivative in stromal absorption of dexamethasone. Arch Ophthalmol 1974; **91**: 373-6.

[40] Green K, Downs SJ. Prednisolone phosphate penetration into and through the cornea. Invest Ophthalmol 1974; **13**: 316-9.

[41] Kupferman A, Leibowitz HM. Topically applied steroids in corneal disease. IV. The role of drug concentration in stromal absorption of prednisolone acetate. Arch Ophthalmol 1974; **91**: 377-80.

[42] Kupferman A, Leibowitz HM. Topically applied steroids in corneal disease. V.Dexamethasone alcohol. Arch Ophthalmol 1974; **92**: 329-30.

[43] Hull DS, Hine JE, Edelhauser JFet al. Permeability of the isolated rabbit cornea to corticosteroids. Invest Ophthalmol 1974; **13**: 457-9.

[44] Leibowitz HM, Kupferman A. Anti-inflammatory effectiveness in the cornea of topically administered prednisolone. Invest Ophthalmol 1974; **13**: 757-63.

[45] Sieg JW, Robinson JR. Corneal absorption of fluorometholone in rabbits. A comparative evaluation of corneal drug transport characteristics in anesthetized and unanesthetized rabbits. Arch Ophthalmol 1974; **92**: 240-3.

[46] Unlu N, Robinson JR. Scleral permeability to hydrocortisone and mannitol in the albino rabbit eye. J Ocul Pharmacol Ther 1998; **14**: 273-81.

[47] Johansen S, Rask-Pedersen E, Prause JU.A bioavailability comparison in rabbits after a single topical ocular application of prednisolone acetate formulated as a high-viscosity gel and as an aqueous suspension. Acta Ophthalmol Scand 1996; **74**: 253-8.

[48] Druzgala P,Wu WM, Bodor N. Ocular absorption and distribution of loteprednol etabonate, a soft steroid, in rabbit eyes. Curr Eye Res 1991; **10**: 933-7.

[49] Smolin G, Hall JM, Okumoto M et al. High doses of subconjunctival corticosteroid and antibody-forming cells in the eye and draining lymph nodes. Arch Ophthalmol 1977; **95**: 1631-3.

[50] Sugar J, Chandler JW. Experimental corneal wound strength. Arch Ophthalmol 1974; **92**: 248-9.

[51] Levine ND, Aronson SB. Orbital infusion of steroids in the rabbit. Arch Ophthalmol 1970; **83**: 599-607.

[52] Ke TL, Clark AF, Gracy RW. Age-related permeability changes in rabbit corneas. J Ocul Pharmacol Ther 1999; **15**: 513-23.

[53] Leibowitz HM, Kupferman A. Kinetics of topically administered prednisolone acetate. Optimal concentration for treatment of inflammatory keratitis. Arch Ophthalmol 1976; **94**: 1387-9.

[54] Kupferman A, Leibowitz HM. Biological equivalence of ophthalmic prednisolone acetate suspensions. Am J Ophthalmol 1976; **82**: 109-13.

[55] Schoenwald RD, Boltralik JJ. A bioavailability comparison in rabbits of two steroids formulated as high-viscosity gels and reference aqueous preparations. Invest Ophthalmol Vis Sci 1979; **18**: 61-6.

[56] Schoenwald RD, Stewart P. Effect of particle size on ophthalmic bioavailability of dexamethasone suspensions in rabbits. J Pharm Sci 1980; **69**: 391-4.

[57] Weijtens O, Feron EJ, Schoemaker RC et al. High concentration of dexamethasone in aqueous and vitreous after subconjunctival injection. Am J Ophthalmol1999; **128:192**-7.

[58] Druzgala P,Wu WM, Bodor N. Ocular absorption and distribution of loteprednol etabonate, a soft steroid, in rabbit eyes. Curr Eye Res 1991; **10**: 933-7

[59] Pappa KS. Corticosteroid drugs. In: Mauger TF, Craig EL, editors. Havener's ocular pharmacology. 6th ed. St Louis:Mosby, 1994: 365-414

[60] Haynes RC, Murad F. Adrenocorticotrophic hormone: adrenocortical steroids and their synthetic analogs; inhibitors of the synthesis and actions of adrenocorticoid hormones. In: Hardman JGG, Gillman A, Limbird LL, editors. The pharmacological basis of therapeutics. 9th ed. NewYork:McGraw-Hill, 1995: 1459-85

[61] Kupferman A, Berrospi AR, Leibowitz HM. Fluorometholone acetate. Anew ophthalmic derivative of fluorometholone. Arch Ophthalmol 1982; **100**: 640-1

[62] Iqbal Z, Watson DG, Midgley JM et al. The metabolism of fluorometholone by bovine cornea. J Pharm Biomed Anal 1993; **11**: 1115-20

[63] Dell SJ, Shulman DG, Lowry GM et al. A controlled evaluation of the efficacy and safety of loteprednol etabonate in the prophylactic treatment of seasonal allergic conjunctivitis. Loteprednol Allergic Conjunctivitis Study Group. Am J Ophthalmol 1997; **123**:791-7.

[64] Friedlaender MH, Howes J. A double-masked, placebo-controlled evaluation of the efficacy and safety of loteprednol etabonate in the treatment of giant papillary conjunctivitis. The Loteprednol Etabonate Giant Papillary Conjunctivitis Study Group I. Am J Ophthalmol 1997; **123**:455-64.

[65] Viswalingam M, Rauz S, Morlet N et al. Blepharokeratoconjunctivitis in children: diagnosis and treatment. Br J Ophthalmol 2005; **89**:400-3.

[66] Jabs DA, Mudun A, Dunn JP et al. Episcleritis and scleritis: clinical features and treatment results. Am J Ophthalmol 2000; **130**:469-76.

[67] Donshik PC, Berman MB, Dohlman CH et al. Effect of topical steroids on ulceration in alkali-burned corneas. *Arch Ophthalmol* 1978; **96:**2117-20.

[68] Davis AR, Ali QK, Aclimandos WA et al. Topical steroid use in the treatment of ocular alkali burns. Br J Ophthalmol 1997; **81**:732-4.

[69] Avunduk AM, Avunduk MC, Varnell ED et al. The comparison of efficacies of topical corticosteroids and nonsteroidal anti-inflammatory drops on dry eye patients: a clinical and immunocytochemical study. Am J Ophthalmol 2003; **136**:593-602.

[70] Power WJ, Hillery MP, Benedict-Smith A et al. Acyclovir ointment plus topical betamethasone or placebo in first episode disciform keratitis. Br J Ophthalmol 1992; **76**:711-3.

[71] Controlled evaluation of loteprednol etabonate and prednisolone acetate in the treatment of acute anterior uveitis. Loteprednol Etabonate US Uveitis Study Group. Am J Ophthalmol 1999; **127**:537-44.

[72] Foster CS, Alter G, DeBarge LR et al. Efficacy and safety of rimexolone 1% ophthalmic suspension vs 1% prednisolone acetate in the treatment of uveitis. Am J Ophthalmol 1996; **122:**171-82.

[73] Diestelhorst M, Aspacher F, Konen Wet al. Effect of dexamethasone 0.1% and prednisolone acetate 1.0% eye drops on the blood-aqueous barrier after cataract surgery: a controlled randomized fluorophotometric study. Graefes Arch Clin Exp Ophthalmol1992; **230**:451-3.

[74] Saari KM, Nelimarkka L, Ahola V et al. Comparison of topical 0.7% dexamethasone-cyclodextrin with 0.1% dexamethasone sodium phosphate for postcataract inflammation. Graefes Arch Clin Exp Ophthalmol 2006; **244**:620-6.

Legends:

Figure 1: Illustration showing comparisons of peak aqueous concentrations of topical steroids.

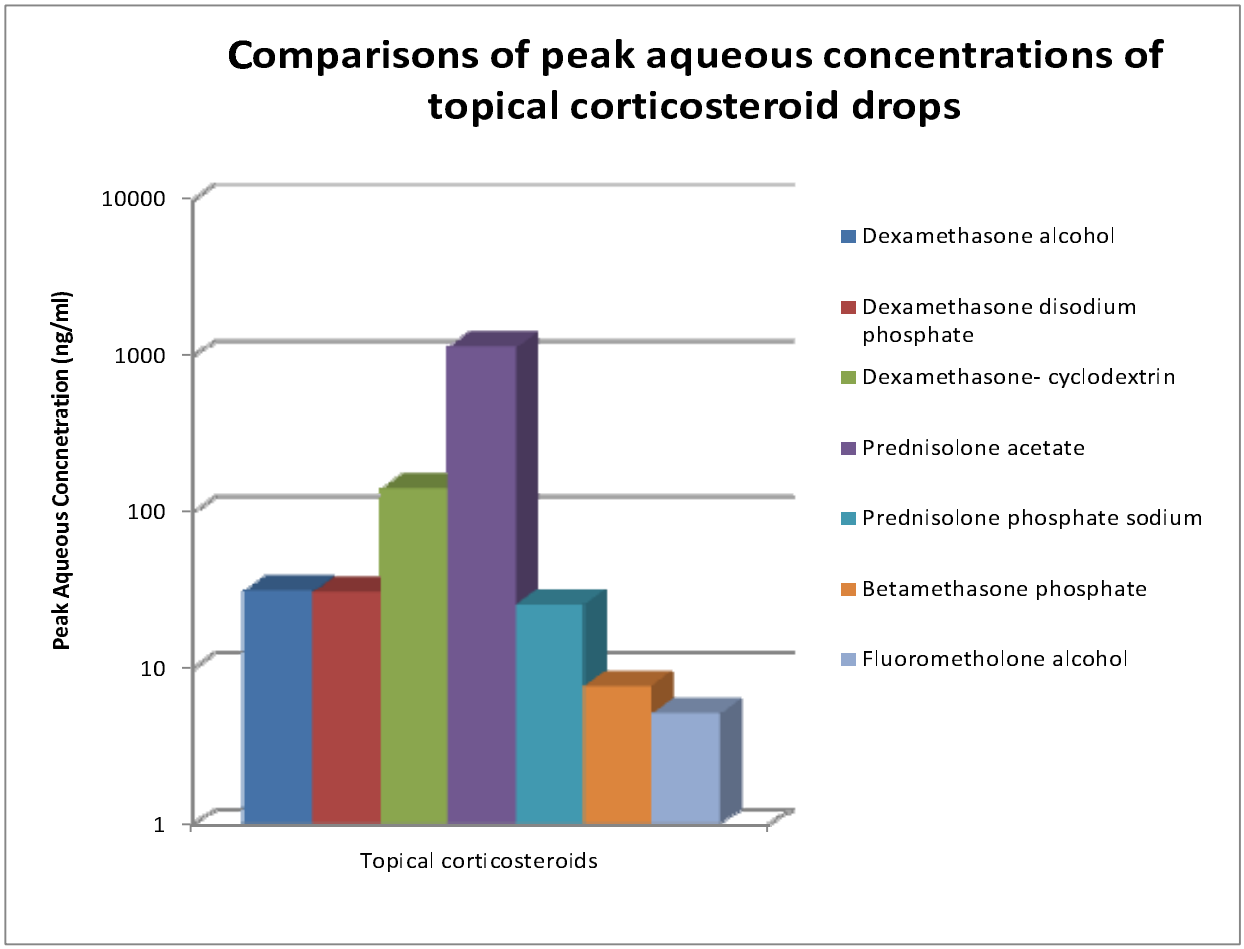
Comparisons of peak aqueous concentrations of topical corticosteroid drops
Peak Aqueous Concnetration (ng/ml)
10000
1000
100
10
1
Topical corticosteroids
Dexamethasone alcohol
Dexamethasone disodium phosphate
Dexamethasone- cyclodextrin
Prednisolone acetate
Prednisolone phosphate sodium
Betamethasone phosphate
Fluorometholone alcohol