



# Small Margin Excision of Periocular Basal Cell Carcinomas

Vikas Chadha, Mark Wright

## ► To cite this version:

Vikas Chadha, Mark Wright. Small Margin Excision of Periocular Basal Cell Carcinomas. British Journal of Ophthalmology, 2009, 93 (6), pp.803-n/a. 10.1136/bjo.2008.151183 . hal-00477828

**HAL Id: hal-00477828**

**<https://hal.science/hal-00477828>**

Submitted on 30 Apr 2010

**HAL** is a multi-disciplinary open access archive for the deposit and dissemination of scientific research documents, whether they are published or not. The documents may come from teaching and research institutions in France or abroad, or from public or private research centers.

L'archive ouverte pluridisciplinaire **HAL**, est destinée au dépôt et à la diffusion de documents scientifiques de niveau recherche, publiés ou non, émanant des établissements d'enseignement et de recherche français ou étrangers, des laboratoires publics ou privés.

**Title: Small Margin Excision of Periocular Basal Cell Carcinomas**

**Keywords: Basal cell carcinoma**

**Authors: Vikas Chadha**

**Mark Wright**

**Institution: Princess Alexandra Eye Pavilion, Edinburgh**

**Corresponding Author: Vikas Chadha**

**Address for Correspondence:**

**Princess Alexandra Eye Pavilion**

**Chalmers Street**

**Edinburgh EH3 9HA**

**Email: [vchdh@aol.com](mailto:vchdh@aol.com)**

**Phone: 07865081415**

**Number of tables: 1 (embedded in text)**

**Number of figures: 1**

## ABSTRACT

**Aims:** To analyse the outcome of small margin (up to 2mm) excision of primary clinically well-defined peri-ocular basal cell carcinomas (BCCs).

**Methods:** Retrospective evaluation of 90 well-demarcated primary basal cell carcinomas having a minimum follow-up of 36 months. All patients underwent excision of the tumour with maximum margins of 2mm. Resulting defects were, if possible, closed directly.

Reconstruction of defects requiring flaps or grafts was delayed until receipt of the histological report which was obtained in all cases.

**Results:** One-stage excision and direct closure was performed in 67 patients (74.4%). In 23 patients (25.6%) excision was performed on one day and reconstruction was done four days later, after receipt of the histopathology report. Histological assessment confirmed complete excision after the first excision in 78 (86.7%) rising to 83 (92.2%) after 2 excisions. The mean follow-up was  $47.5 \pm 9.1$  months. Of the 12 cases with incompletely excised lesions, seven of the patients chose not to have any more surgery and only one of these recurred. There were two other recurrences, and in both of them the lesion had initially been reported as completely excised. Overall the recurrence rate in our study was 3.3% (n=3).

**Conclusions:** Our recurrence rate compares well with published results following conventional excision of BCCs. In the absence of availability of Mohs surgery, well demarcated nodular basal cell carcinomas can be safely excised using smaller margins than conventionally practised.

## TEXT

### Introduction

Basal cell carcinoma (BCC) is the most common of all malignant eyelid tumours accounting for 90-95% of cases. They occur most commonly at the lower lid (50-60%) and then at the medial canthus, upper eyelid and lateral canthus in decreasing frequency.<sup>1</sup> Surgical excision is regarded as the definitive mode of treatment though many other modalities including cryotherapy, radiotherapy, photodynamic therapy and topical treatment have been described.

Moh's micrographic surgery is widely regarded as the gold standard for the complete excision of any dermatological tumour because it preserves the maximum amount of healthy tissue while providing the best assurance of the completeness of removal.<sup>2</sup> However it is time consuming, expensive and requires local expertise, and is, therefore currently impractical for all tumours due to its patchy availability in the UK.

Conventionally, basal cell carcinomas are excised with 3-4mm margins, combined with primary repair.<sup>3</sup> In the peri-ocular region, especially when the lid margin is involved, such wide excision results in large defects requiring complex reconstruction. Hsuan et al have reported excellent results following the use of 2mm margins in peri-ocular BCCs excised in a staged manner.<sup>4</sup> For the past 8 years, we have used similar margins for all clinically well-defined primary lesions in order to preserve more healthy tissue enabling more straightforward closure resulting in reduced patient morbidity. We undertook this retrospective study to ascertain the histological clearance rate and the recurrence rate of our practise of small-margin (2mm) excision of BCCs.

## **Materials and Methods**

Patient details were obtained from a diary record dating back to 1999 in which the details of all patients undergoing a lid lesion biopsy were recorded. The case notes for all histopathologically proven basal cell carcinoma excised between January 1999 to December 2003 were examined. The following cases were then excluded from the study:

1. Clinically poorly demarcated BCC's (irrespective of histopathology)
2. Follow up of less than 36 months from date of excision
3. Recurrent BCCs

### Procedure of excision

The margins of excision were marked 2mm outside the clinical margins of the tumour. This was often done with magnification of the slit lamp to facilitate identification of the margins of the tumour.<sup>5</sup> All tumours were excised under local anaesthetic (2% lignocaine with 1:200,000 adrenaline.) All resulting defects were, if possible, closed directly. Others ie those needing a flap or a graft were scheduled for reconstruction four days later with a request to the department of pathology for an urgent report to be provided before the day of reconstruction.

No arrangements for Moh's surgery existed locally. Therefore, all samples were sent for conventional pathological examination by paraffin section.

## Results

A total of 113 cases were identified of which case notes were available for 102 patients.

Ninety cases (n=90) fulfilled the inclusion criteria. The age ranged between 35-97 years with a mean of  $73.9 \pm 11.8$  years. Forty-nine (54%) of these patients were female. The distribution of the basal cell carcinomas was as follows: lower lid = 45 (50%), medial canthus = 23 (26%), upper lid = 14 (16%) and lateral canthus = 8 (9%).

### Type of Excision

One-stage clinical margin-controlled excision and reconstruction was performed in 67 (74.4%) of the patients. In 23 patients (25.6%) excision was performed on one day and reconstruction was done four days later after receipt of the histopathology report. If histopathology indicated inadequate excision, the patient underwent further excision before reconstruction. However reconstruction was not delayed a second time and was performed without awaiting the second histopathological report.

All defects that could be closed directly without the use of flaps or grafts were reconstructed in the same setting. It was felt that if after one-stop direct closure the histology subsequently deemed the tumour to be incompletely excised, further excision and closure is not been compromised by the initial surgery. The majority of the lesions in the group undergoing delayed reconstruction can be assumed to be larger as they were obviously not amenable to direct closure. However data on the exact sizes was not available.

### Pathology results

Overall, 78 (86.7%) tumours were reported as completely excised after the first surgery. Of the 12 inadequately excised tumours, 8 were in the clinical margin controlled group (i.e. the

group which underwent primary direct closure). After considering various risk factors including size, location and pathology, and discussing the pros and cons of the options of further excision or close follow-up, a joint decision was made to observe 7 of these 8 inadequately excised tumours. One of these 7 patients had a recurrence and underwent further surgery two years after the first excision. One patient decided to undergo further excision which was done three weeks after the first excision. Histopathology reported this sample as having no evidence of residual BCC.

Four of the inadequately excised tumours belonged to the group which underwent two-stage surgery. All of these underwent further excision of 2mm from the involved margin before reconstruction. However reconstruction was not delayed to await the report from the second sample. Of these, one was reported as having no evidence of residual BCC and three were reported completely excised.

The BCC was reported as nodular in 87 patients and morpheic in 3 (3.3%) patients. All morpheic tumors were reported as completely excised.

### Recurrence

The follow-up ranged between 37-59 months with a mean of  $47.5 \pm 9.1$  months. Over this period there were 3 (3.3%) clinical recurrences noted. Two of these were in the lower lid tumors (presenting 14 and 18 months after the first excision) and one in a medial canthal lesion (presenting at 17 months after surgery)

All of these recurrences occurred in the clinical margin controlled group. Thus the recurrence rate for the patients who underwent a two-staged procedure was 0%.

Figure 1 shows the results including distribution of the recurrences according to adequacy of excision. Two cases of recurrence occurred in whom the tumour was reported as having been completely excised.

## **Discussion**

No clear standards have been laid down for histological clearance and recurrence rates after periocular BCC excision. Ideally a 100% histological clearance should be obtained before reconstruction and this should equate to 0% recurrence. This may be possible with a method of histological examination being available at the time of surgery as in Moh's technique or with frozen section examination. Both these techniques are dependent on the existence of appropriate equipment and skills in the unit and are more labour intensive. A second way of attempting to achieve complete histological clearance is by performing the surgery in at least two stages- excision and then awaiting the conventional paraffin section to be reported before proceeding with reconstruction. This second alternative requires at least two visits of the patient to the operating room and therefore increases the load on the service.

Table 1 shows that our histological clearance and recurrence rates are comparable to some of the large studies reporting results following conventional excision using 2-8mm margins.<sup>4,6-8</sup> Frozen section control appears to give lower recurrence rates than conventional excision.<sup>7-9</sup> Moh's technique, however, has been reported to have recurrence rates as low as 0.6% making it the technique of choice if available and practical.<sup>2,10</sup>



Study	Technique	Number	Mean Follow-up	Histological clearance	Recurrence rate
<i>Our Study</i>	<i>Clinical margin (2mm) controlled and two-stage</i>	90	4 yrs (min 3yrs)	86.7%	3.3%
Hsuan <sup>4</sup> et al 2004	2 mm margins; Two-stage	55	5.8 yrs (min 5yrs)	81.8%	0%
Hamada <sup>6</sup> et al 2005	Clinical margin (2-4 mm) controlled	69	Min 5 yrs	84%	4.3%
Conway <sup>7</sup> et al 2004	Clinical margin (4-8mm) controlled	31	6.4 yrs (min 5yrs)	90.3%	9.7%
	Frozen section controlled (3-4mm)	114	6.9 yrs (min 5yrs)	0%	0%
Wong <sup>8</sup> et al 2002	Clinical margin (3mm) controlled	113	2.6 yrs	92.9%	1.8%
		20	5 yrs		5%
	Frozen section controlled (2-4mm)	423	2.6 yrs	--	0.7%
		90	5 yrs		2.2%
Pieh <sup>9</sup> et al 1999	Frozen section controlled	298	5.7 yrs	--	5.36%

**Table 1: Comparison of our results with some large published studies**

Only two published studies have reported on 2mm margins for clinically well-demarcated peri-ocular BCCs. Hamada et al analysed the outcome of non-Moh's excision in their unit and used 2mm margins in 13% of their 162 cases.<sup>6</sup> These were all small nodular BCCs. Their overall recurrence rate was 4.3% but data on the recurrence rate in the 2mm-margin subgroup has not been reported. Hsuan et al reported on five-year follow up for 55 patients who had a clinically well-demarcated nodular BCCs excised with 2mm margins and delayed repair.<sup>4</sup>

They awaited the result of formal paraffin sections before proceeding for reconstruction (i.e. two-stage surgery). Ten of their excisions were reported to have incomplete margins and underwent a further 2mm excision. Using this method they achieved a 0% recurrence rate in their cohort. One big advantage of our approach over Hsuan et al's approach is that majority (75 %) of our patients had their treatment completed at one visit saving a large amount of theatre time. Further, 2 of our 3 recurrences occurred in patients in whom the subsequent histology report had indicated that the tumour was completely removed, and 2 patients were in the one-stage surgery group. If we had chosen to delay closure until receipt of the pathology report then these patients would have had two visits rather than one and would still have had recurrence of their tumours.

A two-stage procedure (primary excision with delayed repair) provides the opportunity to excise more tissue before reconstruction if the first sample has been noted as incompletely excised. Our recurrence rate of 0% in all the patients who underwent a two-staged procedure is the same as in Hsuan et al's study. Of the patients undergoing two-stage surgery, we did not wait for receipt of the (second) histology report before reconstruction. Thus, none of our patients returned for a third visit. In all of these four patients, the second pathology report subsequently showed complete tumour clearance and none of these tumours recurred. We believe that this approach, as in the one-stage surgery, is a reasonable compromise and is justified on the basis of our results. This helps prevent a significant increase in the caseload and a consequent increase in waiting times.

If positive margins are reported and no re-excision performed, the risk of recurrence is high. Our recurrence rate in this group was 14.3% (1 of 12). Other studies have reported recurrence rates of up to 67%.<sup>5</sup> Two (2.6%) of our 'completely excised' BCCs recurred within the study

period. It has been suggested that conventional paraffin sections examine only about 1% of the specimen, and therefore follow-up is essential even in 'complete excisions'.

If complete excision is reported, we see our patients at 1 month, 6 months and then annually for a total of five years. In cases of incomplete excision, the follow-up is more frequent for the first two years- at 1 month, 4 months and then 6-monthly for the next three visits before reverting to the annual visits. All patients are made fully aware of the risk of recurrence irrespective of the reported completeness of excision and are advised to contact us if they suspect any sign of recurrence. In case the patients travelling from long distances, we are equally happy to rely on local follow-up arrangements. In this situation we ensure that pre-operative and post-operative photographs are sent to the department where follow-up is being organised. Some authors recommend life-long follow-up for all patients with periocular BCC.<sup>8</sup> This may be ideal, but is impractical in the NHS setting.

The retrospective nature of the study has certain drawbacks. There was no data on the size of the tumours excised. This is an important prognostic factor. Periocular BCCs larger than 10mm have been reported to have nearly four times the recurrence rates of smaller BCCs in the same location.<sup>11</sup> Further all the patients were not operated by the same surgeon. Finally, this study is somewhat limited by its minimum three year follow-up although the mean follow-up was nearly four years. It is said that only 66% of all recurrences appear within three years of the primary excision.<sup>12</sup>

Our study suggests that the histological clearance rates and recurrence rates at our department are not significantly compromised by using smaller (2mm) than conventional margins for clinically well-demarcated nodular basal cell carcinomas. Mohs surgery remains the

technique which results in minimum tissue excision. However, in the absence of its availability, healthy periocular tissue can be preserved by using 2mm margins for clinically well-defined lesions simplifying subsequent reconstructive procedures.

#### Licence for Publication

The Corresponding Author has the right to grant on behalf of all authors and does grant on behalf of all authors, an exclusive licence (or non exclusive for government employees) on a worldwide basis to the BMJ Publishing Group Ltd to permit this article (if accepted) to be published in BJO and any other BMJ PGL products and sublicences such use and exploit all subsidiary rights, as set out in our licence (<http://bjo.bmj.com/ifora/licence.pdf>).

Competing Interest: None declared.

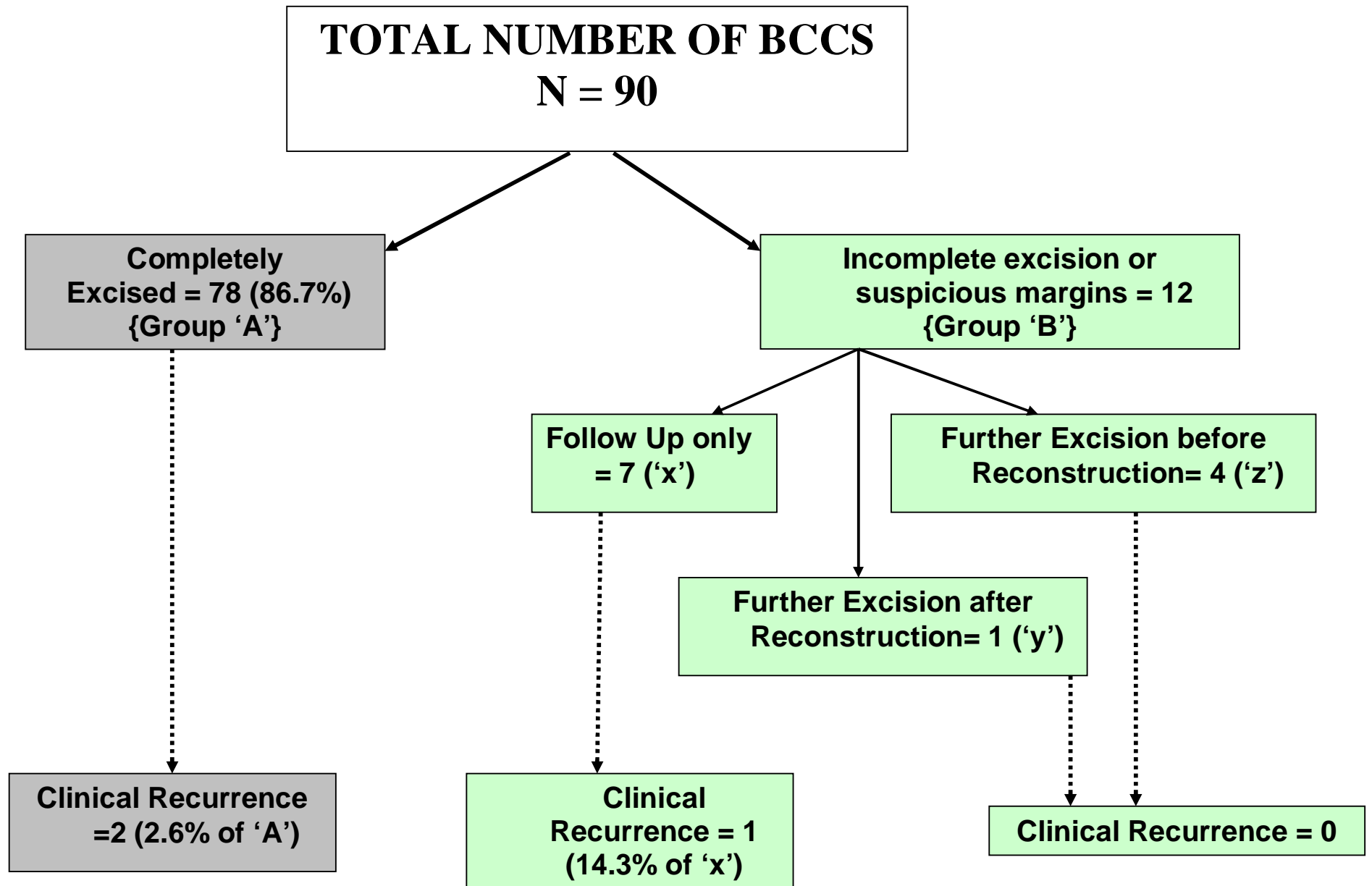
#### **References**

1. Bernardini FP. Management of malignant and benign eyelid lesions. *Curr Opin Ophthalmol* 2006;17:480-484.
2. Malhotra R, Huilgol SC, Huynh NT et al. The Australian Mohs database, part II. Periocular basal cell carcinoma at 5-year follow-up. *Ophthalmology* 2004;111:631-636.
3. Wolf DJ, Zitelli JA. Surgical margins for basal cell carcinoma. *Arch Dermatol* 1987;123:340-344.
4. Hsuan JD, Harrad RA, Potts MJ et al. Small margin excision of periocular basal cell carcinoma: 5 year results. *Br J Ophthalmol* 2004;88:358-360.

5. Macrae ME, Wright M. Non-micrographic excision of eyelid tumours-ten practical tips. *CME Ophthalmology* 2007;8:59-61.
6. Hamada S, Kersey T, Thaller VT. Eyelid basal cell carcinoma: non-Mohs excision, repair and outcome. *Br J Ophthalmol* 2005;89:992-994.
7. Conway RM, Themel S, Holbach LM. Surgery for primary basal cell carcinoma including the eyelid margins with intraoperative frozen section control: comparative interventional study with a minimum clinical follow-up of 5 years. *Br J Ophthalmol* 2004;88:236-238.
8. Wong VA, Marshall JA, Whitehead KJ et al. management of periocular basal cell carcinoma with modified en face frozen section controlled excision. *Ophthalm Plast Reconstr Surg* 2002;18:430-435.
9. Pieh S, Kuchar A, Novak P et al. Long term results after basal cell carcinoma excision in the eyelid region. *Br J Ophthalmol* 1999;83:85-88.
10. Mohs FE. Micrographic surgery for the microscopically controlled excision of eyelid cancers. *Arch Ophthalmol* 1986;104:901-906.
11. Thissen MRTM, Neumann MHA, Schouten LJ. A systematic review of treatment modalities for primary basal cell carcinomas. *Arch Dermatol* 1999;135:1177-1183.
12. Rowe DE, Carroll RJ, Day CL. Long term recurrence rates in previously untreated (primary) basal cell carcinoma: implications for patient follow-up. *J Dermatol Surg Oncology* 1989;15:315-328.

### **Legend for Figure 1**

Flow-chart representing the clinical recurrence rates in the completely excised and incompletely excised groups.



**FIGURE 1**