



HAL
open science

Glaucoma and Helicobacter Pylori Infection. Correlations and Controversies.

Alberto Izzotti, Sergio Claudio Sacca', Alessandro Bagnis, Santi M. Recupero

► **To cite this version:**

Alberto Izzotti, Sergio Claudio Sacca', Alessandro Bagnis, Santi M. Recupero. Glaucoma and Helicobacter Pylori Infection. Correlations and Controversies.. British Journal of Ophthalmology, 2009, 93 (11), pp.1420-n/a. 10.1136/bjo.2008.150409 . hal-00477826

HAL Id: hal-00477826

<https://hal.science/hal-00477826v1>

Submitted on 30 Apr 2010

HAL is a multi-disciplinary open access archive for the deposit and dissemination of scientific research documents, whether they are published or not. The documents may come from teaching and research institutions in France or abroad, or from public or private research centers.

L'archive ouverte pluridisciplinaire **HAL**, est destinée au dépôt et à la diffusion de documents scientifiques de niveau recherche, publiés ou non, émanant des établissements d'enseignement et de recherche français ou étrangers, des laboratoires publics ou privés.

Glaucoma and *Helicobacter Pylori* Infection.

Correlations and Controversies

Alberto Izzotti ^a, Sergio Claudio Sacca ^b, Alessandro Bagnis ^c, Santi Maria Recupero ^d

^aDept. of Health Sciences, Faculty of Medicine, University of Genoa, Italy;

^bDept. of Head/Neck Pathologies, St. Martino Hospital: Ophthalmology Unit, Genoa, Italy;

^cDept. of Neurosciences, Ophthalmology and Genetics, Clinica Oculistica University of Genoa, Italy;

^dDept. of Ophthalmology, Faculty of Medicine, University "La sapienza" St. Andrea Hospital, Rome, Italy

Words Count: 3015

Licence for Publication

The Corresponding Author has the right to grant on behalf of all authors and does grant on behalf of all authors, an exclusive licence (or non exclusive for government employees) on a worldwide basis to the BMJ Publishing Group Ltd to permit this article (if accepted) to be published in BJO and any other BMJ PGL products and sublicences such use and exploit all subsidiary rights, as set out in our licence .

Corresponding Author : Sergio Claudio Sacca', St Martino Hospital : Ophthalmology Unit,

Viale Benedetto XV, I° piano. 16132 Genoa, Italy. Tel: +39-010 555 2443; Fax:+39-010 555 6585.

E-mail: sergio.sacca@hsanmartino.it

KEYWORDS: *Helicobacter pylori*; glaucoma; oxidative damage

The authors have no proprietary interest in any aspect of this report.

BACKGROUND

In recent years, a possible association between *Helicobacter pylori* (HP) infection (**Fig. 1**) and eye diseases, including Sjogreen's syndrome, blepharitis, central serous chorioretinopathy and uveitis, has been proposed [1-4] (**Fig. 2**). The relationships between these different eye diseases and HP infection have not yet been clarified. Glaucoma is the second leading cause of blindness in the world, after cataracts, and the leading cause of irreversible blindness [5-7]. However, many aspects of its pathogenesis remain unknown. HP infection is also one of the world's most common infections and has been associated with glaucoma [8]; recently, HP infection has been proposed as an environmental familial clustering risk factor for primary open-angle glaucoma [9]. In a prospective, nonrandomized, comparative study, Kountouras et al. found that the frequency of HP infection in a group of glaucoma patients was higher than in control subjects [8]. In their study, HP infection was histologically confirmed in 88.2% of glaucoma patients. The authors claimed that a theoretical relationship between glaucoma and HP infection may exist because: (a) both diseases affect senescent people in the developed world; (b) HP infection may produce systemic disorders resulting from the release of vasoactive and proinflammatory substances; (c) HP infection may be related to atherosclerosis and increased platelet activation and aggregation. Others authors found that positivity for HP detected by a urea breath test was significantly higher in patients with glaucoma than in control participants ($p=0.017$), thereby suggesting that HP infection might be associated with open-angle glaucoma in Chinese patients (10).

Conversely, other studies have found no association between HP infection and open-angle glaucoma [11;12]. Moreover, Razeghinejad et al. have determined the levels of anti-*H. pylori* IgG antibody in the aqueous humor of patients with pseudoexfoliation and primary open angle glaucoma, in comparison with age and sex matched cataract patients (13). Although the results of this study did not support a relation between HP infection and primary open angle glaucoma, there was an elevated concentration of anti-HP IgG in pseudoexfoliation glaucoma compared with the control group ($p=0.03$). (**Tab. 1**)

The aim of our review was to assess whether the different results of these studies could be compared and to ascertain whether or not HP infection and glaucoma share common pathogenetic aspects. In particular, we focused on oxidative damage as a possible link between these pathologies.

METHODS

In July 2006, we performed a literature search consisting of a textword search in Medline from 1998 to July 2008. Articles dealing with pathogenetic aspects of HP infection, glaucoma and oxidative damage and stress were then selected and reviewed (**Tab.2**)

RESULTS

Kountouras et al. first reported an association between glaucoma and HP infection [8]. Even If Ozturk et al. (14) have demonstrated a link between glaucoma and HP serology. Anyway, Kountouras et al. [8] investigated 41 glaucomatous patients (78% with primary open-angle glaucoma - POAG, 12% with pseudoexfoliative glaucoma - PEG) and 30 age-matched anaemic controls. All 71 subjects underwent diagnostic gastroscopy and gastric mucosa biopsies to determine HP infection by means of histopathologic analysis and urease test. The prevalence of HP infection and serum levels of IgG anti-HP was significantly higher among glaucoma patients than controls.

This result has been confirmed by a chinese report (10) but other studies ([11,12].) did not detect any association between glaucoma and HP infection . Table 1 shows the different methods used to determine the frequency of HP infection in glaucoma patients and controls in each of the 5 studies, and the results obtained [8,10-13,15]. Kountouras et al. [8] examined HP infection directly by searching for HP in endoscopic specimens, while the other studies examined HP infection indirectly by detecting the antibodies (Ab) produced against the bacterium. Kurtz et al. also evaluated seropositivity to the cytotoxin-associated gene A (CagA) antigen, an important virulence marker of some strains of *Helicobacter pylori* [16]; they found no association between seropositivity for virulent CagA-bearing HP strains and the occurrence of glaucoma among the

patients in their study [12]. It should be noted, however, that the detection of anti-HP Ab in serum does not only reflect current infection but may also be a hallmark of eradicated infections. Furthermore, serum Ab are not sensitive markers of HP infection, as this bacterium does not penetrate into the blood stream but localizes between the gastric mucosa and the mucus layer, mainly inducing the production of mucosal IgA rather than serum IgG. Consequently, evaluations of HP infection status by serum ELISA and the histological examination of gastric mucosa may not always be congruent. In addition, the ELISA technique of detecting HP infection has been reported to have suboptimal sensitivity and specificity [8].

The effects of HP eradication on intraocular pressure and visual field defects progression were evaluated by Kountouras et al. in a separate study. Thirty-six HP-positive glaucoma patients underwent a triple eradication regimen and were observed for 2 years. The success of HP eradication was evaluated by control endoscopy at least 8 weeks after the cessation of therapy and by rapid urease test. In the subgroup of patients from whom the infection was eradicated, glaucoma parameters (mean intraocular pressure and mean visual field) 2 years after eradication had improved ($P < 0.01$ for intraocular pressure; $P \leq 0.01$ for visual field) while no enhancement was demonstrated in patients in whom eradication was unsuccessful [17].

The presence and concentration of Helicobacter pylori-specific antibody in the aqueous humour of glaucoma patients has been also evaluated. Kountouras et al. [15] found that the concentration of HP-specific IgG evaluated by means of the ELISA technique was significantly higher in aqueous humour samples from both POAG ($P = 0.006$) and PEG ($P = 0.003$) patients than in controls. Similarly, the serum concentration of anti-HP IgG was greater in POAG ($P = 0.013$) and PEG ($P = 0.002$) patients than in controls. Moreover, the mean vertical cupping of the optic nerve head correlated significantly with the concentration of HP-specific IgG in the aqueous humour of

POAG patients, suggesting that this could reflect the severity of glaucomatous damage in these subjects.

DISCUSSION

HP and oxidative damage

HP infection is responsible for inflammation, increased production of ROS, and the induction of oxidative DNA damage in the gastric mucosa [18-19]. A positive association between ROS production and HP infection has been demonstrated since 1994 [20]. Recently, it has been reported that the HP induction of oxidative DNA damage mainly occurs in cases of infection by CagA-positive HP strains in patients bearing adverse polymorphism of the OGG1 gene, which is involved in 8-oxo-dG repair [21].

HP infection locally induces a chronic inflammatory status consisting of neutrophil, Polymorphonuclear (PMN) cells and lymphocyte recruitment at the infection site [22]. PMN cells attempt to damage bacterial structures by producing superoxide radical and other ROS, thus determining local oxidative stress. Excessive and long-lasting ROS production in the gastric mucosa may damage cellular components, including polyunsaturated fatty acids, proteins and DNA. Membrane lipid-peroxidation results in the perturbation of various cellular and organellar membrane functions, including transport processes, the maintenance of ion and metabolite gradients, receptor-mediated signal transduction, etc. Accordingly, antioxidant reduced glutathione (GSH) in the gastric mucosa is significantly decreased in HP-infected patients that may be associated with gastric carcinogenesis, since GSH is involved in the prevention and direct repair of oxidative DNA lesions [25]. Subjects infected by HP also present lower levels of plasma

ascorbic acid and plasma beta-carotene [26] Also children infected with HP are deficient in vitamin A [27].

Beta-carotene and vitamins A, C and E are chain-breaking antioxidants. Since decreased levels of antioxidants due to increased levels of lipid peroxidation create a state of oxidative stress [28].

Furthermore many HP virulence factors promote release of variety chemoattractants / inflammatory mediators triggering an intense leukocyte infiltration of the gastric mucosa, and neutrophil activation provides a major source of reactive oxygen species which can cause tissue damage mainly in the absence of antioxidants (29).

Oxidative damage and glaucoma

Ascorbic acid is thought to be a primary substrate in eye protection on account of its high ocular concentration [30]. This molecule is highly concentrated in the aqueous humour, cornea and tear film [31-33]. Vitamin C is an important antioxidant, protecting cells from oxidative stress-induced death [34]. The trabecular meshwork (TM) cells contain antioxidant enzymes, such as superoxide dismutase and catalase [35]. Glutathione is detectable in aqueous humour, [36] while the ocular ciliary epithelium expresses genes coding for glutathione-*S*-transferases, glutathione peroxidases and other enzymes involved in the glutathione cycle [37]. Both glutathione peroxidase and glutathione reductase activities have been detected in TM cells [38]. Catalase has been suggested to protect ocular tissues when high H₂O₂ concentrations are present, whereas the GSH redox system is believed to protect ocular tissues from damage induced by low H₂O₂ concentrations [39,40]. In experimental glaucoma, glutathione content is increased in Müller cells and the concentration progressively increases with the duration of elevated IOP. This might

possibly be the result of the glutamate-induced formation of reactive nitrogen and oxygen species, glutathione protecting both neurons and Müller cells against oxidative damage [41].

The TM plays a fundamental role in the hydrodynamics of the aqueous humour. Alterations in the aqueous outflow lead to IOP increase, elevated IOP being one of the main risk factors for the development of glaucomatous neuropathy [42]. The total reactive antioxidant potential of aqueous humour obtained from glaucoma patients is significantly decreased [43]. TM cells are in contact with high concentrations of H_2O_2 , which can induce detrimental effects on aqueous humour outflow [44] and the age-related decrease in TM cellularity [45]. Furthermore, the specific activity of superoxide dismutase shows an age-dependent decline in normal TM from cadavers [35]. TM oxidative stress-related damage is likely to be manifested as an increase in IOP due to alterations in outflow facility, as outflow resistance increases in the presence of high H_2O_2 levels [44]. H_2O_2 damages the cytoskeleton, compromising TM integrity [46] and influencing the biological reactions of the TM [47,48].

Oxidative damage in the TM of glaucoma patients is significantly higher than in controls [49] and is related to IOP [50]. Thus, increased oxidative damage in the TM could affect regulation of the extracellular matrix structure and the associated IOP regulation, leading to the clinical onset of glaucoma [2,51,52]. Further support for this hypothesis is provided by the finding that timolol, a beta-blocking drug used to decrease IOP in glaucoma patients, exerts antioxidant activity which protects human endothelial cells from oxidative stress [53].

The permeability of the TM endothelium barrier is influenced by endothelins and nitric oxide (NO). These molecules also play an important role in the regulation of ocular blood flow. Under normal conditions, the vasoconstricting effect of endothelin-1 is counterbalanced by the relaxing effect of NO [54]. In the presence of free radicals, NO generates toxic products that interact with

oxygen, iron, and copper, aggravating the metabolic conditions of the TM and altering its motility and function. [54-56]

It is conceivable that oxidative stress play an important pathologic role in inducing damage both in TM endothelial cells and in the optic nerve head. Glaucomatous neuropathy is characterized by a selective lost of retinal ganglion cells, which results in a loss of visual field corresponding to the nerve fiber layer pattern. [57] Glaucomatous visual field defects and oxidative stress in the TM are correlated [50]. There are three major stimuli for retinal ganglion cell apoptotic death, i.e. hypoxia, neurotrophin withdrawal and glutamate-mediated toxicity. In this context, oxidative stress seems to play an important role [58-62].

Ischemia reperfusion injury produces free radicals responsible for oxidative damage to the axons [63,64]. Moreover, the re-uptake of glutamate is influenced by the concentration of free radicals, an increase in ROS levels leading to increased extra-cellular glutamate concentration [65].

Glutamate is a neurotransmitter whose physiologic role is to transmit synaptic pulses. In pathologic conditions it can potently stimulate target cells, causing death; this type of cellular damage is known as “excitotoxicity” [66,67]. Activation of N-methyl-D-aspartate type (NMDA) membrane receptors by glutamate stimulates the production of large quantities of nitric oxide (NO). Nitric oxide can react with superoxide (mostly produced in the mitochondria of the axons) leading to the formation of peroxynitrate and peroxynitrite anions, which are unstable and rapidly decompose to form the more toxic hydroxide radical, leading to neurotoxicity [54,68,69]. The peroxynitrite anion is particularly able to trigger cell death through apoptosis [54,70]. Intravitreal injection of NMDA produces a delayed retinal damage that can be prevented by pre-treatment with NMDA receptor antagonists or with nitro-L-arginine methyl ester [71]. It has also been shown that large (magnocellular) retinal ganglion cells, the elements most sensitive to

glaucomatous destruction, are more susceptible to NMDA and glutamate-mediated neurotoxicity than small ganglion cells [72,73]. Moreover, the astrocytes of the optic nerve head in glaucoma patients express the inducible form of nitric oxide synthase (NOS II) whose expression in glial cells can be induced in vitro by mechanical and hypoxic stress [68]. This finding further supports the possibility that free radicals may be a link between the vascular and mechanical theories of glaucoma pathogenesis. Nitric oxide also appears to be involved in the pathogenesis of cellular damage in the lateral geniculate nucleus, as documented directly in glaucoma (**Fig. 3**) [74,75].

Correlation between HP infection and glaucoma

Oxidative stress has been implicated in the pathogenesis of several diseases, including both primary open-angle glaucoma and HP infection (**Tab. 3**). Up-regulation of the genes involved in inflammation, which typically occurs in HP-infected gastric mucosa, and acute-phase response might initiate and contribute to the progression of glaucoma [76]. Therefore, HP infection might influence the pathophysiology of glaucoma by releasing various pro-inflammatory and vasoactive substances, as well as by influencing the apoptotic process or TM homeostasis. These parameters may also exert their own effects on the induction and/or progression of glaucomatous neuropathy [77]. What links HP infection and glaucoma may be oxidative damage, which has been shown to occur in cardiovascular diseases, inflammation and glaucoma [50,78-81]. Thus, it cannot be ruled out that HP infection affects the pathophysiology of glaucoma by producing systemic oxidative stress through the increase of circulating lipid peroxides [80;82]. Reactive oxygen species and circulating peroxides are apoptotic signals, apoptosis being the most important mechanism of cellular death during glaucoma [72]. Moreover, increased levels of HP-specific IgG antibodies have been found directly in the aqueous humour of glaucomatous patients [15]. Recently, it has

been proposed that mitogen-activated protein kinases (MAPKs) present in the aqueous humour could be involved in glaucoma pathogenesis [83]; mitogen-activated protein kinase networks are involved in the apoptotic process, which is a possible cellular response to oxidative stress [84]. Interestingly, HP has been shown to induce activation of the MAPKs extracellular signal-regulated protein kinase (ERK) 1/2, and MAPK/ERK kinase (MEK) 1/2, which are mediated at the level of the IL-8 promoter [85]. HP infection also induces IL-8 production, leading to neutrophil migration and activation, ROS generation and oxidative damage.

Gastric HP infection could result in the systemic release of pro-inflammatory and vasoactive substances, including endothelin-1, nitric oxide and inducible nitric oxide synthase [80,82].

Accordingly, glaucoma patients could display higher susceptibility to oxidative damage in both the TM and optic nerve head. In agreement with Li et al. (86) we can say that chronic oxidative stress in TM cells induced iROS production in mitochondria. This increase in ROS may contribute to the pathogenesis of the TM in glaucoma (30,50) by inducing the expression of inflammatory mediators and also has the potential to contribute by itself to pathophysiological changes of the outflow pathway by increasing the levels of oxidative damage in the cells.

Hosseini et al. hypothesized that eye problems in HP-infected patients may be related to the high concentration in exhaled air of volatile noxious compounds elaborated by the microorganism, including hydrogen nitrate and hydrogen cyanide [87]. The activation of inflammatory mediators by HP might be the pathogenetic mechanism underlying the association between ocular diseases and HP infection. Similarly, an association between HP infection and respiratory diseases has been proposed on the basis of the genetic predisposition of the infected host, the presence of strain-specific virulence factors, and the serum concentration of pro-inflammatory markers in HP-infected patients [88].

The notion that systemic oxidative damage induced by infective agents is related to the onset of chronic degenerative diseases has already been suggested by studies that have investigated this relationship with regard to cardiovascular diseases. An association between *Chlamydia pneumoniae* or *Cytomegalovirus* infection and atherosclerosis has also been reported, [89,90] suggesting that the underlying pathogenetic mechanism is the production of reactive oxygen species [90].

Conclusions

In conclusion, it is extremely difficult to compare the results of studies that currently are present in the literature because we would need a based study population, including thousands of patients, to really know the prevalence of glaucoma in patients infected with HP. However at present, is possible to say that H. pylori infection may influence the pathophysiology of glaucoma (Table 3) (91) by releasing various proinflammatory and vasoactive substances, as well as by influencing the apoptotic process, parameters that may also exert their own effects in the induction and/or progression of glaucomatous neuropathy (77). In any case, it is difficult to understand how HP infection can be linked to such varied pathologies. It is possible that the “link” might be the oxidative damage that recurs in circulation disorders (92), in inflammation (93) (94) and in glaucoma (50). Anyway, it is clear that an increase in oxidative damage occurs in HP-infected subjects. This phenomenon does not occur only locally in the infected gastric mucosa, but may be exported to the systemic level, thereby affecting a variety of organs and tissues, including the eye. Systemic HP-induced oxidative damage may be the mechanism which links oxidative stress, HP infection and the damage to the TM and Optical Nerve Head that results in glaucoma.

Notwithstanding, we do not really know if whether or not the prevalence of glaucoma is significantly different in HP infected patients from that in non-infected subjects, there are no epidemiologic studies that demonstrated the possible ethnic similarities and/or diversities regarding the association between HP and glaucoma among different countries (95) . Further studies are necessary to confirm or confute this hypothesis and to clarify the possible role and importance of genetic factors common to both diseases.

REFERENCES

1. El Miedany YM, Baddour M, Ahmed I, Fahmy H. Sjogren's syndrome: concomitant H. pylori infection and possible correlation with clinical parameters. *Joint Bone Spine* 2005;72:135-41.
2. Saccà SC, Pascotto A, Venturino GM et al. Prevalence and treatment of Helicobacter pylori in patients with blepharitis. *Invest Ophthalmol Vis Sci.* 2006;47:501-8.
3. Cotticelli L, Borrelli M, D'Alessio AC et al. Central serous chorioretinopathy and Helicobacter pylori. *Eur J Ophthalmol* 2006;16:274-8.
4. Otasevic L, Zlatanovic G, Stanojevic-Paovic A et al. Helicobacter pylori: an underestimated factor in acute anterior uveitis and spondyloarthropathies?. *Ophthalmologica* 2007;221:6-13.
5. Quigley HA. The search for glaucoma genes - implications for pathogenesis and disease detection. *N Engl J Med* 1998;338:1063-1064.
6. Tomarev SI. Eyeing a new route along an old pathway. *Nat Med* 2001;7:294-295.
7. Wang N, Chintala SK, Fini ME, Schuman JS. Activation of a tissue-specific stress response in the aqueous outflow pathway of the eye defines the glaucoma disease phenotype. *Nat Med* 2001;7:304-309.
8. Kountouras J, Mylopoulos N, Boura P et al. Relationship between Helicobacter Pylori infection and glaucoma. *Ophthalmology* 2001;108:599-604.
9. Kountouras J, Zavos C, Grigoriadis N, Deretzi G, Katsinelos P, Tzilves D. Helicobacter pylori infection as an environmental familial clustering risk factor for primary open-angle glaucoma. *Clin Experiment Ophthalmol.* 2008;36:296-7.
10. Hong Y, Zhang C, Duan L, Wang W. Relationship between Helicobacter pylori infection and open angle glaucoma in China. *Asian J Ophthalmol* 2007;9:205-8.
11. Galloway P, Warner S, Morshed M, Mikelgerg F. Helicobacter pylori infection and the risk for open angle glaucoma. *Ophthalmology* 2003;110:922-925.
12. Kurtz S, Regenbogen M, Goldiner I, Horowitz N, Moshkowitz M. No association between Helicobacter pylori infection or CagA-bearing strains and glaucoma. *J Glaucoma* 2008;17:223-226

13. Razeghinejad MR, Kamali-Sarvestani E, Farvardin M, Pourhabibi A. Aqueous levels of anti-*Helicobacter pylori* IgG antibody in patients with primary open angle and pseudoexfoliation glaucoma. *Iran J Immunol* 2006;3:86-90.
14. Ozturk F, Kurt E, Inan UU, et al. Is *Helicobacter pylori* related to glaucoma? In: Program and abstracts of the 6th Congress of the European Glaucoma Society, London, 2000:108 [abstract].
15. Kountouras J, Mylopoulos N, Konstas AG, Zavos C, Chatzopoulos D, Boukla A. Increased levels of *Helicobacter pylori* IgG antibodies in aqueous humour of patients with primary open-angle and exfoliation glaucoma. *Graefes Arch Clin Exp Ophthalmol* 2003;241:884-90
16. Franceschi F, Niccoli G, Ferrante G. CagA antigen of *Helicobacter pylori* and coronary instability: Insight from a clinico-pathological study and a meta-analysis of 4241 cases. *Atherosclerosis* 2008 (Epub head of print)]
17. Kountouras J, Mylopoulos N, Chatzopoulos D et al. Eradication of *Helicobacter pylori* may be beneficial in the management of chronic open-angle glaucoma. *Arch Intern Med* 2002;162:1237-44.
18. Siomek A, Rytarowska A, Szaflarska-Poplawska A et al. *Helicobacter pylori* infection is associated with oxidatively damaged DNA in human leukocytes and decreased level of urinary 8-oxo-7,8-dihydroguanine. *Carcinogenesis* 2005;27:405-408.
19. Kountouras J, Zavos C, Chatzopoulos D. *Helicobacter pylori* and glaucoma. *Ophthalmology* 2003;110:2433-4.
20. Davies GR, Simmonds NJ, Stevens TR, et al. *Helicobacter pylori* stimulates antral mucosal reactive oxygen metabolite production in vivo. *Gut* 1994;35:179-85.
21. Izzotti A, De Flora S, Cartiglia C et al. Interplay between *Helicobacter pylori* and host gene polymorphisms in inducing oxidative DNA damage in the gastric mucosa. *Carcinogenesis* 2007;28:892-8
22. Miedany Y, Baddour M, Ahmed I, Fahmy H. Sjogren's syndrome: concomitant H. Pylori infection and possible correlation with clinical parameters. *Joint Bone Spine* 2005;72:135-141.

23. Verhulst ML, Van Oijen AH, Roelofs HM, Peters WH, Jansen JB. Antral glutathione concentration and glutathione S-transferase activity in patients with and without *Helicobacter pylori*. *Dig Dis Sci* 2000;45:629-32.
24. Shirin H, Pinto JT., Liu LU, Merzianu M, Sordillo EM; Moss SF. *Helicobacter pylori* decreases gastric mucosal glutathione. *Cancer Lett* 2001;164:127-33.
25. Naito Y, Yoshikawa T. Molecular and cellular mechanisms involved in *Helicobacter Pylori*-induced inflammation and oxidative stress. *Free Rad Biol & Med.* 2002;3:323-336.
26. Correa P. The role of antioxidants in gastric carcinogenesis. *Crit Rev Food Sci Nutr* 1995;53:59-64.
27. Khaled MA, Sarker SA and Wahed MA. *Helicobacter pylori* and vitamin A status in children. *Am J Clin Nutr* 1997;66:707.
28. Halliwell B. Antioxidants in human health and diseases. *Ann Rev Nutr* 1996;16:33-50.
29. Kountouras J, Chatzopoulos D, Zavos C.: Reactive oxygen metabolites and upper gastrointestinal diseases. *Hepatogastroenterology.* 2001;48:743-51.
30. Saccà SC, Izzotti A, Rossi P, Traverso C. Glaucomatous outflow pathway and oxidative stress exp. *Eye Res* 2007;84:389-399.
31. Hanashima C, Namiki H. Reduced viability of vascular endothelial cells by high concentration of ascorbic acid in vitreous humour. *Cell Biol Int.* 1999;23:287-98.
32. Brubaker RF, Bourne WM, Bachman LA, McLaren JW. Ascorbic acid content of human corneal epithelium. *Invest Ophthalmol Vis Sci* 2000;41:1681-1683.
33. Dreyer R, Rose RC. Lacrimal gland uptake and metabolism of ascorbic acid. *Proc Soc Exp Biol Med* 1993;202:212-216.
34. Guaiquil VH, Vera JC, Golde DW. Mechanism of vitamin C inhibition of cell death induced by oxidative stress in glutathione-depleted HL-60 cells. *J Biol Chem* 2001;276:40955-61.
35. De La Paz MA, Epstein DL. Effect of age on superoxide dismutase activity of human trabecular meshwork. *Invest Ophthalmol Vis Sci* 1996;37:1849-53.
36. Richer SP, Rose RC. Water soluble antioxidants in mammalian aqueous humour: interaction with UV B and hydrogen peroxide. *Vision Res* 1998;38:2881-8.
37. Coca Prados M, Escribano J, Ortego J. Differential gene expression in the human ciliary epithelium. *Prog Retin Eye Res* 1999;18:403-429.

38. Nguyen KP, Weiss H, Karageuzian LN, Anderson PJ, Epstein DL. Glutathione reductase of calf trabecular meshwork. *Invest Ophthalmol Vis Sci* 1985;26:887-890.
39. Costarides AP, Riley MV, Green K. Roles of catalase and the glutathione redox cycle in the regulation of the anterior-chamber hydrogen peroxide. *Ophthalmic Res* 1991;23:284-294.
40. Riley MV. Physiologic neutralization mechanisms and the response of the corneal endothelium to hydrogen peroxide. *CLAO-J* 1990;16:S16-S21.
41. Carter-Dawson L, Shen FF, Harwerth RS, Crawford ML, Smith EL3rd, Whitetree A. Glutathione content is altered in Muller cells of monkey eyes with experimental glaucoma. *Neurosci Lett* 2004;364:7-10.
42. Sommer A, Tielsch JM, Katz J et al. Relationship between intraocular pressure and primary open angle glaucoma among white and black Americans. The Baltimore Eye Survey. *Arch Ophthalmol* 1991;109:1090-5.
43. Ferreira SM, Lerner SF, Branzini R, Evelson PA, Llesury SF. Oxidative stress markers in aqueous humour of glaucoma patients. *Am J Ophthalmol* 2004;137:62-9.
44. Kahn MG, Giblin FJ, Epstein DL. Glutathione in calf trabecular meshwork and its relation to aqueous humour outflow facility. *Invest Ophthalmol Vis Sci* 1983;24:1283-1287.
45. Alvarado JA, Murphy CG, Polansky JR, Juster R. Age-related changes in trabecular meshwork cellularity. *Invest Ophthalmol Vis Sci* 1981;21:714-727.
46. Zhou L, Li Y, Yue BY. Oxidative stress affects cytoskeletal structure and cell-matrix interactions in cells from an ocular tissue: the trabecular meshwork. *J Cell Physiol* 1999;180:182-189.
47. Barksdale Sbhuyan K, Podos S. Oxidative stress in cultured Human Trabecular cells suppression of prostaglandin production. *Invest Ophthalmol Vis Sci* 1986;27:210-214.
48. Tamm ER, Russell P, Johnson DH, Piatigorsky J. Human and monkey trabecular meshwork accumulate alpha B-crystallin in response to heat shock and oxidative stress. *Invest Ophthalmol Vis Sci* 1996;37:2402-2413.
49. Izzotti A, Saccà SC, Cartiglia C, De Flora S. Oxidative deoxyribonucleic acid damage in the eyes of glaucoma patients. *Am J Med* 2003;114:638-46.

50. Saccà SC, Pascotto A, Camicione P, Capris P, Izzotti A. Oxidative DNA Damage in the Human Trabecular Meshwork: clinical correlation in patients with primary open-angle glaucoma. *Arch Ophthalmol* 2005;123:458–463.
51. Knepper PA, Goossens W, Hvizd M, Palmberg PF. Glycosaminoglycans of the human trabecular meshwork in primary open-angle glaucoma. *Invest Ophthalmol Vis Sci* 1996;37:1360-7.
52. Lutjen-Drecoll E, Rohen JW. Morphology of aqueous outflow pathways in normal and glaucomatous eyes. In: R. Ritch, M.B. Shields, T. Krupin eds. *The Glaucomas* 2nd ed. St. Louis: Mosby 1996;1:89-123.
53. Izzotti A, Saccà SC, Di Marco B, Penco S, Bassi AM. Antioxidant activity of timolol on endothelial cells and its relevance for glaucoma course. *Eye* 2007;2:1-7.
54. Haefliger IO, Dettmann E, Liu R et al. Potential role of nitric oxide and endothelin in the pathogenesis of glaucoma. *Surv Ophthalmol.* 1999;43:S51-8.
55. Tamm ER, Lutjen Drecoll E. Nitric Oxide in the outflow pathways of the aqueous humour. In: I.O. Haefliger, J. Flammer, eds, *Nitric Oxide and Endothelin in the pathogenesis of Glaucoma*. New York: Lippincott-Raven 1998;158-167.
56. Wiederholt M. Nitric Oxide and endothelin in aqueous humour outflow regulation. In: I.O. Haefliger, J. Flammer, eds. *Nitric Oxide and Endothelin in the pathogenesis of Glaucoma*. New York: Lippincott-Raven 1998;68-177.
57. Palmberg Paul F, Wiggs JL. Mechanisms of glaucoma. In: M. Yanoff, J.S. Duker, eds. *Ophthalmology*. 2nd edition. St. Louis: Mosby 2004;1423-1430.
58. Tezel G, Yang X. Caspase-independent component of retinal ganglion cell death, in vitro. *Invest Ophthalmol Vis Sci* 2004;45:4049-59.
59. Lambert WS, Clark AF, Wordinger R.J. Neurotrophin and Trk expression by cells of the human lamina cribrosa following oxygen-glucose deprivation. *BMC Neurosci* 2004;5:51.
60. Meldrum B, Garthwaite J. Excitatory amino acid neurotoxicity and neurodegenerative disease. *Trends Pharmacol Sci* 1990;11:379-87.
61. Chung H, Harris A, Evans DW, Kagermann L, Garzoi HJ, Martin B. Vascular aspect in the pathology of glaucomatous optic neuropathy. *Survey of Ophthalmology* 1999;43:S43-50.

62. Moreno MC, Campanelli J, Sande P, Sanes DA, Keller Sarmiento MI; Rosestein RE. Retinal oxidative stress induced by high intraocular pressure. *Free Radic Biol Med* 2004;37:803-12.
63. Flammer J. The vascular concept in glaucoma. *Surv Ophthalmol* 1994;38:S3-6.
64. Flammer J, Haefliger I, Orgül S, Resink T. Vascular dysregulation: a principal risk for glaucomatous damage? *J Glaucoma* 1999;8:212-219.
65. Vergun O, Sobolevsky AI, Yelshansky MV, Keelan J, Khodorov BI, Duchon MR. Exploration of the role of reactive oxygen species in glutamate neurotoxicity in rat hippocampal neurones in culture. *J Physiol* 2001;531:47-163.
66. Lipton SA, Rosenberg PA. Excitatory amino acids as a final common pathway for neurologic disorders. *New Engl J Med* 1994;330:613-622.
67. Standaert D, Young A. Trattamento delle malattie degenerative del sistema nervosa centrale. In: P.B. Molinoff, R.W. Ruddon, eds. *Goodman & Gilman, Le basi farmacologiche della terapia*, New York: McGraw-Hill 1996:502.
68. Flammer J, Orgül S, Costa V et al. The impact of ocular blood flow in glaucoma. *Prog Retin Eye Res* 2002;21:259-393.
69. Lipton SA. Neuronal protection and destruction by NO. *Cell Death Differ* 1999;6:943-51.
70. Moncada S, Palmer RMJ, Higgs A. Nitric oxide: Physiology, pathophysiology and pharmacology. *Pharmacol Rev* 1992;43:109-142.
71. Morizane C, Adachi K, Furutani I et al. N(omega)-nitro-L-arginine methyl ester protects retinal neurons against N-metil-D-aspartate-induced neurotoxicity in vivo. *Eur J Pharmacol* 1997;328:45-49.
72. Rabacchi SA, Ensini M, Bonfanti L, Gravina A, Maffei L. Nerve growth factor reduces apoptosis of axotomized retinal ganglion cells in the neonatal rat. *Neuroscienze* 1994;63:696-973.
73. Osborne NN, Ugarte M, Chao M ,et al., Neuroprotection in relation to retinal ischemia and relevance to glaucoma. *Surv Ophthalmol* 1999;43:S102-122.
74. Nucci C, Morrone L, Rombola L, Nistico L, Piccirilli S, Cerulli L. Multifaceted roles of nitric oxide in the lateral geniculate nucleus: from visual signal transduction to neuronal apoptosis. *Toxicol Lett* 2003;139:163-73.

75. Chaturvedi N, Hedley-Whyte ET, Dreyer EB. Lateral geniculate nucleus in glaucoma. *Am J Ophthalmol* 1993;116:182-8.
76. Liton PB, Luna C, Challa P, Epstein DL, Gonzalez P. Genome-wide expression profile of human trabecular meshwork cultured cells, nonglaucomatous and primary open-angle glaucoma tissue. *Mol Vis* 2006;12:774-90.
77. Kountouras J, Zavos C, Chatzopoulos D, Induction of apoptosis as a proposed pathophysiological link between glaucoma and *Helicobacter pylori* infection. *Med Hypotheses* 2004;62:378-81.
78. DeLano FA, Balete R, Schmid-SchonbeinGW. Control of oxidative stress in microcirculation of spontaneously hypertensive rats. *Am J Physiol Heart Circ Physiol* 2005;288:H805-12.
79. Halliday GM. Inflammation, gene mutation and photoimmunosuppression in response to UVR-induced oxidative damage contributes to photocarcinogenesis. *Mutat Res* 2005;571:107-20.
80. Sun YQ, Girgensone I, Leanderson P, Peterson F, Borch K. Effects of antioxidant vitamin supplements on *Helicobacter pylori*-induced gastritis in Mongolian gerbils. *Helicobacter* 2005;10:33-42.
81. Kountouras J, Deretzi G, Zavos C et al. Association between *Helicobacter pylori* infection and acute inflammatory demyelinating polyradiculoneuropathy. *Eur J Neurol* 2005;12:139-43.
82. Kountouras J, Zavos C, Grigoriadis N, Deretzi G, Katsinelos P, Tzilves D. *Helicobacter pylori* infection as a risk factor for primary open-angle glaucoma. *Clin Experiment Ophthalmol* 2008;36:196
83. Beit-Yannai E, Shmulevich A. Does the aqueous humour have a role in mitogen-activated protein kinase (MAPK) intracellular signalling in glaucoma? *Med Hypotheses* 2004;62:378-81
84. Winter-Vann AM, G, Johnson JL. Integrated activation of MAP3Ks balances cell fate in response to stress. *J Cell Biochem* 2007;102:848-858
85. Zavos C, Kountouras J, Skoura L, Sakkias G, Parapanisiou E. Mitogen-activated protein kinase (MAPK) intracellular signalling in the aqueous humour activated by *Helicobacter pylori* may have a role in glaucoma. *Med Hypotheses* 2007;68:928-9.

86. Li G, Luna C, Liton PB, Navarro I, Epstein DL, Gonzalez P.: Sustained stress response after oxidative stress in trabecular meshwork cells. *Mol Vis.* 2007;13: 2282-8.
87. Hosseini H, Ghaffariyeh A, Nikandish R. Noxious compounds in exhaled air, a potential cause for ocular manifestations of *H. pylori* gastrointestinal infection. *Med Hypotheses* 2007;68:91-3.
88. Roussos A, Philippou N, Mantzaris GJ, Gourgoulialis KI. Respiratory diseases and *Helicobacter pylori* infection: is there a link? *Respiration* 2006;73:708-14.
89. Kälvegren H, Bylin H, Leanderson P, Richter A, Grenegård M, Bengtsson T. *Chlamydia pneumoniae* induces nitric oxide synthetase and lipoxygenase dependent production of reactive oxygen species in platelets. Effects on oxidation of low-density lipoproteins. *Thromb Haemost* 2005;94:327-35.
90. Liu R, Moroi M, Yamamoto M et al. Presence and Severity of *Chlamydia pneumoniae* and Cytomegalovirus Infection in Coronary Plaques Are Associated With Acute Coronary Syndromes. *Int Heart J* 2006;47:511-9.
91. Kountouras J, Zavos C, Chatzopoulos D.: Primary open-angle glaucoma: pathophysiology and treatment. *Lancet.* 2004;364:1311-2.
92. DeLano FA, Balete R, Schmid-Schonbein GW.: Control of oxidative stress in microcirculation of spontaneously hypertensive rats. *Am J Physiol Heart Circ Physiol.* 2005; 288:H805-12.
93. Sun YQ, Girgensone I, Leanderson P, Petersson F, Borch K.: Effects of antioxidant vitamin supplements on *Helicobacter pylori*-induced gastritis in Mongolian gerbils. *Helicobacter.* 2005; 10:33-42.
94. Kountouras J, Tsolaki M, Gavalas E, Boziki M, et al.: Relationship between *Helicobacter pylori* infection and Alzheimer disease. *Neurology.* 2006;66:938-40.
95. Kountouras J, Zavos C, Katsinelos P, Grigoriadis N, Deretzi G, Tzilves D.: Greek and Israeli patterns of *Helicobacter pylori* infection and their association with glaucoma: similarities or diversities? *J Glaucoma.* 2008;17:503-4.

	Urease test (saliva)	Urease test (gastric mucosa)	Histological presence	Seropositivity (ELISA)	Seropositivity (immunoblotting)	Seropositivity to CagA (immunoblotting)	Acqueous IgG levels	Urea breath-test
Kountouras et al, 2001⁸ CASES (41 patients with POAG or PEG)	46.5%	74.9%	88.2%	68.3%	undone	undone	undone	undone
CONTROLS: (30 anemic non glaucomatous patients)	30%	46.7%	46.7%	30%	undone	undone	undone	undone
	P>0.05	-P=0.003 P>0.05	-P=0.0006 P=0.02	P=0.002				
Galloway et al, 2003¹⁰ CASES: 73 patients with different types of glaucoma	undone	undone	undone	26.0%	undone	undone	undone	undone
CONTROLS 94 non glaucomatous patients	undone	undone	undone	20.2%	undone	undone	undone	undone
Kountouras et al 2003???								
	P=0.03 P>0.05*	-	-	P=0.46				
Razeghinejad et al, 2006 CASES 41 patients with POAG and PEG	undone	undone	undone	undone	undone	undone	0.54±0.67 U/ml	undone
CONTROLS 36 patients with cataract	undone	undone	undone	undone	undone	undone	0.24±0.52 U/ml	undone
	P=0.002	P=0.46	-				P>0.05 P=0.003	
Hong Y et al, 2007 CASES: 24 patients with different types of glaucoma	undone	undone	undone	undone	undone	undone	undone	54.2%
CONTROLS: 24 non glaucomatous patients	undone	undone	undone	undone	undone	undone	undone	20.8%
	-	-						P=0.017
Kurtz et al, 2008¹¹ CASES 51 patients with different types of glaucoma	undone	undone	undone	undone	60.8%	51.0%	undone	undone
CONTROLS 36 non glaucomatous patients	undone	undone	undone	undone	61.1%	52.8%	undone	undone
	-	-			P=0.877	P=0.674		

§ Mean of the results obtained within POAG and PEG subgroups.

* Significance of POAG subgroup vs control group and of PEG subgroup vs control group, respectively

** Mean serum IgG levels and corresponding statistical significance of the difference between groups.

Table 1. Comparison of several studies on the prevalence of *Helicobacter pylori* (HP) infection among glaucomatous patients, and methods of detection used. The table shows a number of different tests, most of which are not common to the six studies considered; owing to these differences, it is difficult to compare the results. However, Kountouras *et al.* suggest a significant association between HP infection and both POAG and PEG; their results were yielded by histological detection of the infection. Moreover, they found a significant difference in IgG anti-HP levels in the aqueous humour of glaucomatous and normal subjects; these results were only partially confirmed by Razeghinejad *et al.* Results from Galloway *et al.* and Kurtz *et al.* were obtained only by serological detection of the infection and do not suggest a link between HP infection and glaucoma.

Combination of the terms	Search Engine	
	PubMed	Scopus
	Numbers of papers found	
Helicobacter AND glaucoma	18	36 (34)
Helicobacter AND eye AND pathogenesis	50 (46)	16 (14)
Helicobacter pylori infection AND oxidative stress AND pathogenesis	115 (97)	18
glaucoma AND oxidative stress AND pathogenesis	73 (57)	71 (65)

Table 2 The papers were sought in two databases PubMed and Scopus. We reviewed only papers written in English. The number of papers actually reviewed is shown in brackets: all abstracts were read and, if subject was compatible with our article, the paper was reviewed in detail.

Mechanisms linking H.pylori infection and glaucoma

- Increased platelet and platelet-leucocyte aggregation
- Release of proinflammatory and vasoactive substances (cytokines, eicosanoids, acute-phase proteins)
- Endothelin-dependent vascular dysregulation
- Mononuclear cell stimulation to induce a factor-like procoagulant activity
- Induction of cross-mimicry between endothelial and H. pylori antigens
- Autoimmune injury to the optic nerve directly by autoantibodies
- Production of free radicals and lipid peroxidation
- Induction of apoptosis

Table 3: Several similar alterations are observed in aged individuals and senescent cells, and are correlated with cellular response to sublethal doses of oxidative stress. These alterations and responses include: (1) decline in mitochondrial respiratory function; (2) increase in the rate of production of reactive oxygen species (ROS); (3) accumulation of mitochondrial DNA (mtDNA) mutations; (4) increase in the levels of oxidative damage to DNA, protein and lipids; and (5) decrease in the capacity to degrade oxidatively damaged proteins and other macromolecules. While the mechanism that links HP infection to glaucoma cannot be identified with certainty, it should be underlined that free radicals play a central role in both conditions, probably through various pathogenetic mechanisms. However, the incidence of these condition is known to vary from person to person, even in the same environmental group of subjects.

FIGURE LEGENDS

Figure 1. Legend A: *H. Pylori* (grey arrows) adherence to gastric epithelia, as detected by electron transmission microscopy (4,000 x) in a gastric biopsy collected from a gastritis-affected patient: *H. pylori* bound to intestinal villi and mucus is evident. In B: *H. pylori* colonising gastric epithelia, detected by scanning electron microscopy (3,000 x)
Courtesy of Prof. A. Piana, University of Sassari, Italy.

Figure 2. Legend Relationship between HP infection and ocular diseases and possible pathogenetic mechanisms. *H. pylori* infection promotes a local and systemic immune response, resulting in the production of antibodies against HP-associated cytotoxicity A antigen (CagA), heat shock proteins (HSP) and bacterial epitopes. Cross-mimicry mechanisms could in part explain the purported relationship between HP infection and *Sjogren's syndrome*, *idiopathic central serous chorioretinopathy (ICSC)* and *diffuse retinal epitheliopathy (DRE)*. The endothelial dysfunction leading to the microvascular alterations found in ICSC could also be caused by chronic inflammation resulting from the large amount of inflammatory mediators released during HP infection. Chronic gastritis due to HP infection can lead to malabsorption of vitamins (B12) and folate, which results in the failure of methylation by 5-methyl-tetrahydrophobic acid and homocystein accumulation, which, in turn, could trigger endothelial damage (95). Chronic inflammation can be triggered or exacerbated by gastrin and nitric oxide (NO) produced by the bacterium, which has also been linked to *rosacea*, *blepharitis* and *uveitis*. In this context, the role of reactive oxygen species (ROS) appears to be important. As a consequence of the infection, ammonia, hydrogen cyanide and hydrogen nitrate levels have been found to be elevated in the exhaled breath of HP-infected patients, prolonged exposure to these toxic compounds possibly causing significant ocular sequelae.

Figure 3. Legend Mechanism of the relationship between reactive oxygen species (ROS) and optic nerve damage in ROAG. Glaucomatous neuropathy has a multifactorial etiology. Elevated intraocular pressure (IOP) is considered the most important risk factor for the development of the pathology, but increasing evidence supports the so-called “vascular theory”. Elevated IOP can lead to retinal ganglion cell (RGC) death by blockage of the axoplasmic flow and withdrawal of

neurotrophic factors, such as *brain derived neurotrophic factor* (BDNF) or nerve growth factor (NGF). Many local and systemic mechanisms can lead to local hypoxia and reperfusion injury in glaucoma; the production of free radicals (ROS) can directly affect RGC axons and has also been demonstrated to affect the trabecular meshwork, causing IOP increase. Elevated ROS levels can increase extracellular glutamate – which is responsible for excitotoxic RGC death through the activation of NMDA receptors – Ca^{++} influx, nitric oxide (NO) production, and nitrosative and oxidative stress. NMDA receptor activation is also able to activate caspases and transcriptional factors responsible for apoptotic cell death. Both elevated IOP and hypoxia can activate glial-cell-inducible nitric oxide synthases (NOS); moreover, they can lead to RGC death through the increased release of tumour necrosis factor alpha (TNF- α). Nitric oxide seems to be involved in the lateral geniculate nucleus (LGN) degeneration observed during glaucoma.

Figure 4. Legend The possible relationship between HP and glaucoma and its mechanisms. How *H. pylori* promotes gastric neoplasia is not yet completely understood; one of the hypothesized mechanisms is the production of reactive oxygen species (ROS). The bacteria induce chronic inflammation of the gastric mucosa, followed by the generation of a large amount of ROS by activated polymorphonucleated cells (PMN); the release of CagA toxins may also lead to ROS production and the resulting oxidative stress may be amplified by the reduction of antioxidant defence factors, such as GSH, as induced by the bacterium itself. An accumulation of intracellular ROS regulates the expression of many genes and can induce point mutations contributing to the pathogenesis of gastric cancer. Proinflammatory cytokines, such as interferon-gamma (INF- γ) and tumour necrosis factor-alpha (TNF- α), and VacA toxins can trigger apoptotic mechanisms, leading to optic nerve head degeneration. This may also be the result of the autoimmune response following the infection or the final effect of endothelins and nitrosative stress generated by the bacterium.

ACKNOWLEDGEMENTS

Our study was supported by grants from The Glaucoma Foundation (TGF)

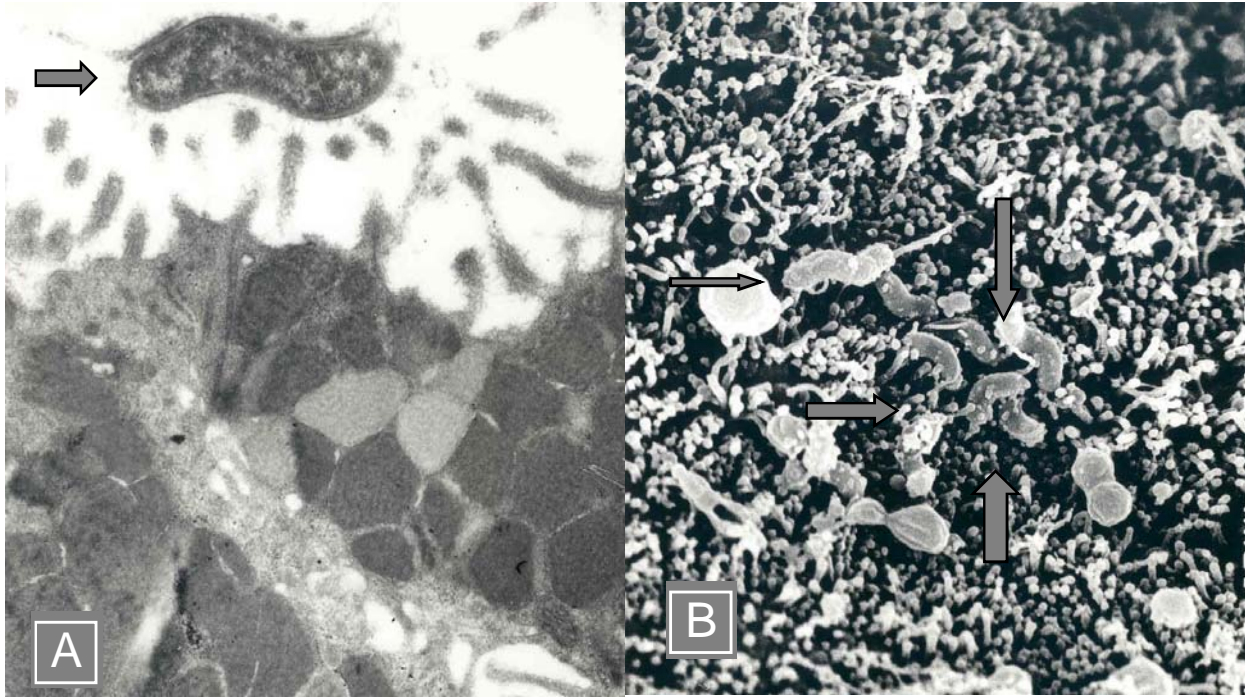


Figure 1

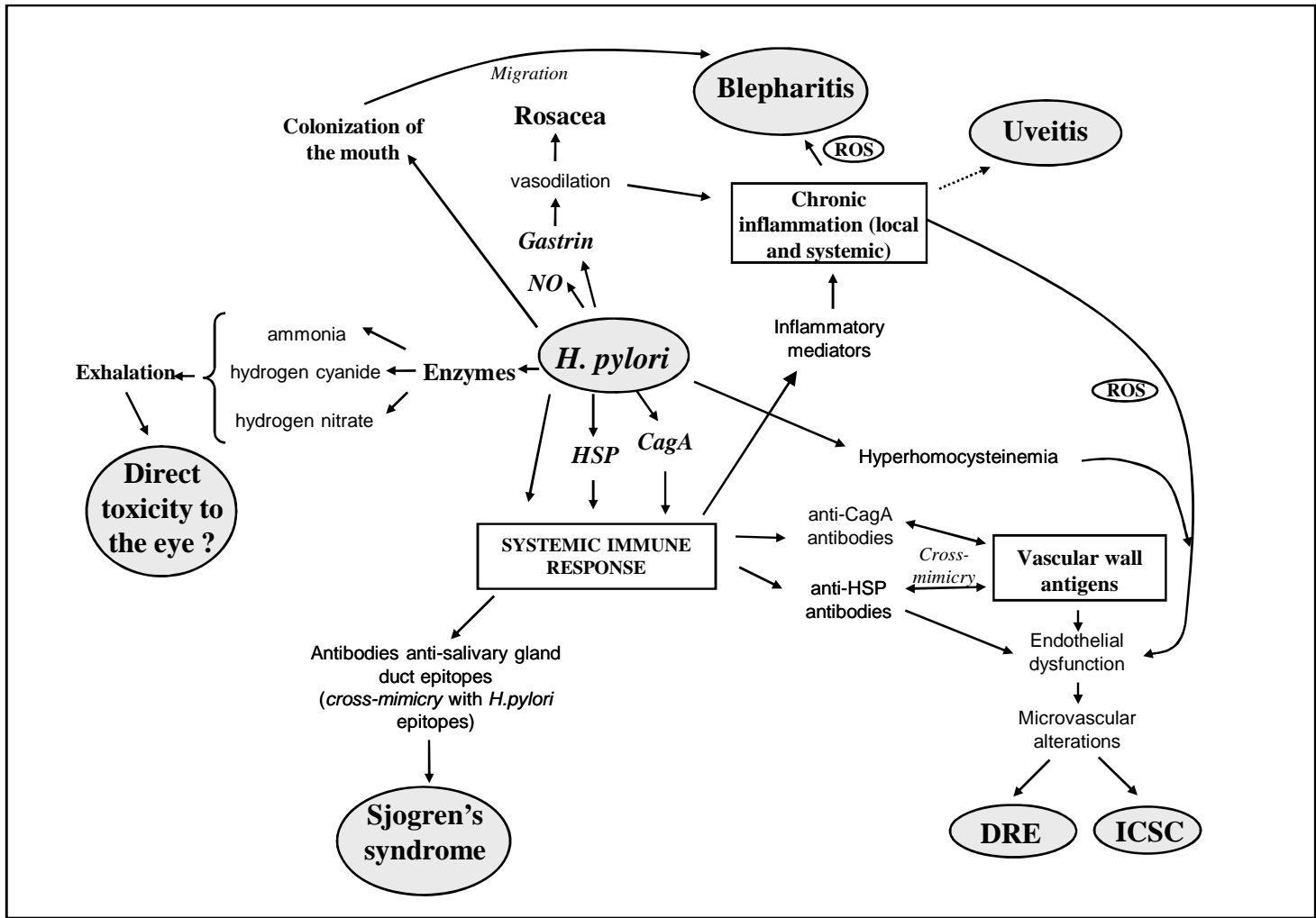


Figure 2

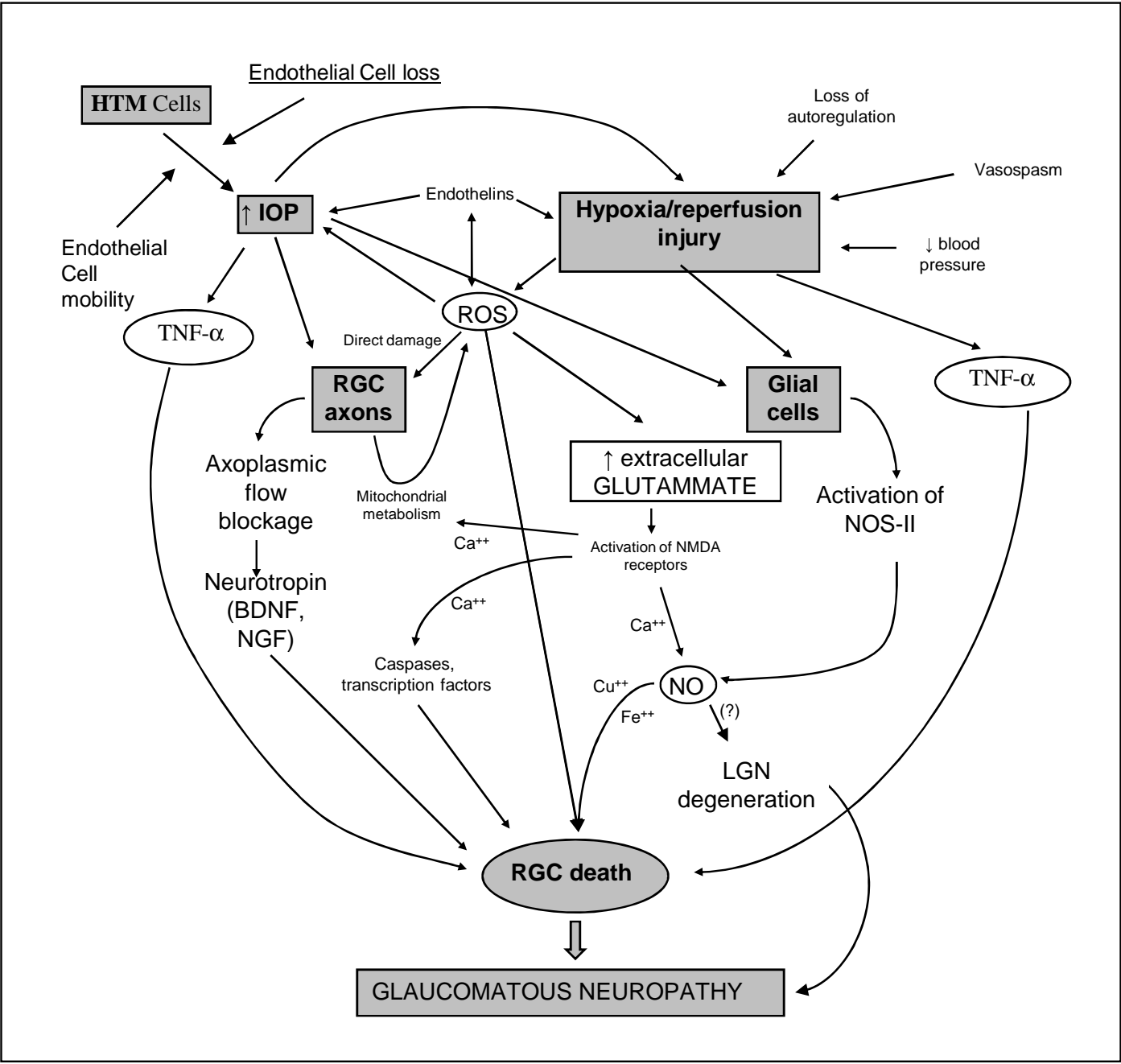


Figure 3

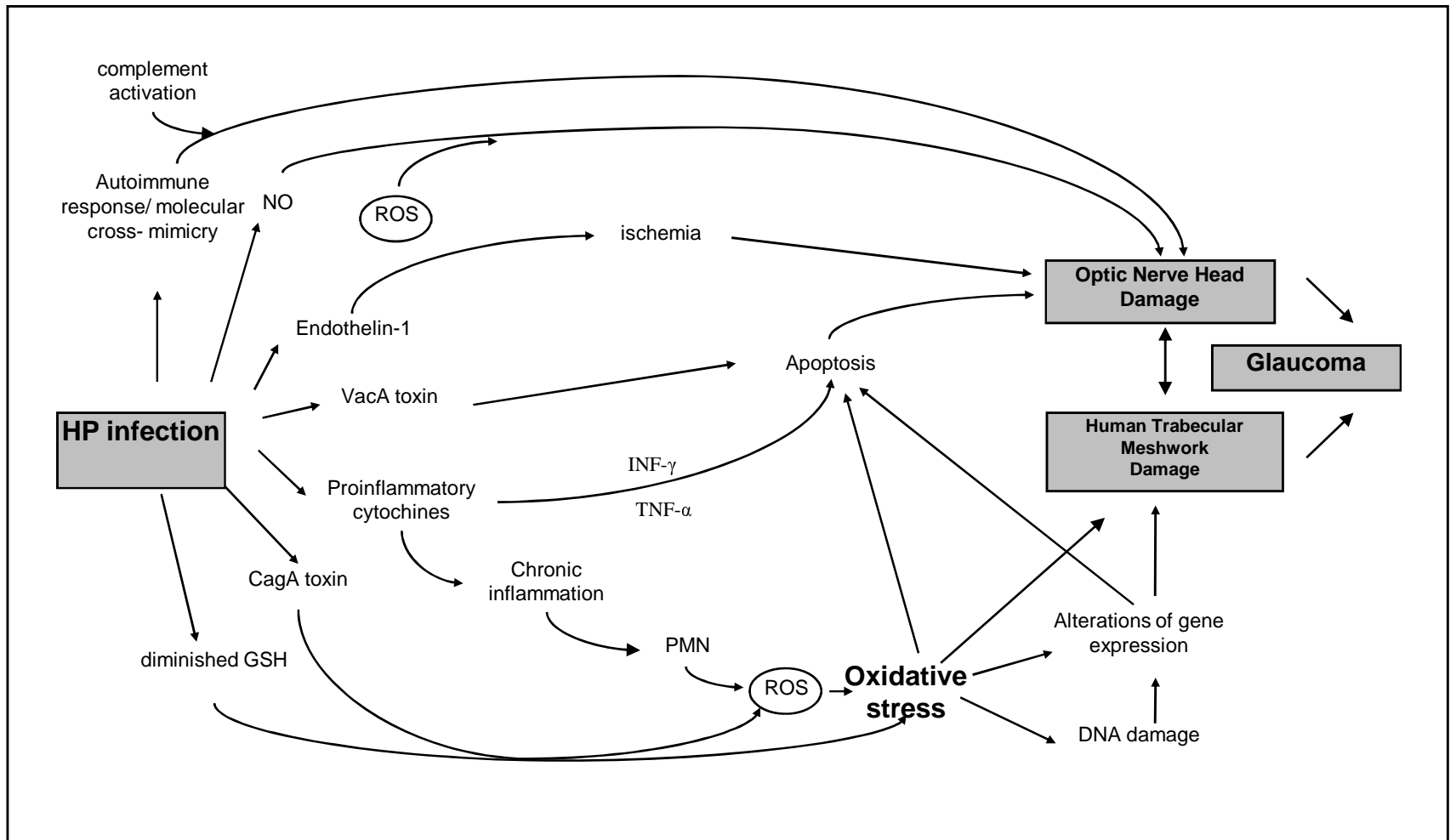


Figure 4