



Changes in Donor Corneal Lenticule Thickness after Descemet's Stripping Automated Endothelial Keratoplasty (DSAEK) with Organ-Cultured Corneas

Pavel Pogorelov, Björn O Bachmann, Claus Cursiefen, Friedrich Kruse

► To cite this version:

Pavel Pogorelov, Björn O Bachmann, Claus Cursiefen, Friedrich Kruse. Changes in Donor Corneal Lenticule Thickness after Descemet's Stripping Automated Endothelial Keratoplasty (DSAEK) with Organ-Cultured Corneas. British Journal of Ophthalmology, 2009, 93 (6), pp.825-n/a. 10.1136/bjo.2008.147389 . hal-00477816

HAL Id: hal-00477816

<https://hal.science/hal-00477816>

Submitted on 30 Apr 2010

HAL is a multi-disciplinary open access archive for the deposit and dissemination of scientific research documents, whether they are published or not. The documents may come from teaching and research institutions in France or abroad, or from public or private research centers.

L'archive ouverte pluridisciplinaire **HAL**, est destinée au dépôt et à la diffusion de documents scientifiques de niveau recherche, publiés ou non, émanant des établissements d'enseignement et de recherche français ou étrangers, des laboratoires publics ou privés.

**Changes in Donor Corneal Lenticule Thickness after Descemet's
Stripping Automated Endothelial Keratoplasty (DSAEK) with Organ-
Cultured Corneas**

Pavel Pogorelov, MD

Claus Cursiefen, MD

Bachmann BO, MD

Friedrich E. Kruse, MD

Department of Ophthalmology
University of Erlangen-Nuremberg
Erlangen, Germany
(Chairman: Prof. Dr. F.E. Kruse)

Correspondence and Reprints:

Pavel Pogorelov, M.D.

Schwabachanlage 6, D-91054 Erlangen, Germany.

Phone: +49 (9131) 8544723

Fax: +49 (9131) 8534615

Email: pavel.pogorelov@uk-erlangen.de

Aims: To quantify changes of donor and host corneal tissue after Descemet's stripping automated endothelial keratoplasty (DSAEK) using organ-cultured corneas and to correlate these findings with the visual acuity during intermediate-term follow-up.

Methods: 15 eyes of 15 consecutive patients with Fuchs' endothelial dystrophy treated with DSAEK using organ-cultured corneas underwent ophthalmologic examination including the slit lamp-adapted OCT (SL-OCT) at 1, 3, 7 days, 4 weeks, 8 weeks and 6 months after the surgery.

Results: The mean BSCVA improved from 20/100 preoperatively to 20/40 six months postoperatively ($P<0.0001$). A continuous decrease of thickness of the grafted lenticule was observed during the follow-up (mean thickness immediately after surgery $191 \pm 56 \mu\text{m}$, compared with $100 \pm 38 \mu\text{m}$ six months after surgery, $P<0.001$). The central corneal thickness decreased from $1057 \pm 86 \mu\text{m}$ at the first postoperative day to $661 \pm 74 \mu\text{m}$ after six months. Both central corneal thickness and the thickness of the posterior donor lamella correlate with the 6-months-BSCVA (Pearson correlation -0.745 and -0.589 respectively, $P<0.05$).

Conclusions: Organ-cultured corneas can be successfully used for DSAEK. The thickness of the grafted corneal lenticule correlates with the BSCVA six months after the surgery. It is decreasing continuously during the follow up.

Introduction

In contrast to penetrating keratoplasty (PK), posterior lamellar keratoplasty allows for selective replacement of diseased host endothelium¹⁻³. This is a more specific procedure than PK, and it has been successfully applied for patients with endothelial corneal disorders such as Fuchs' corneal dystrophy and pseudophakic bullous keratopathy. The most common technique for posterior lamellar keratoplasty is Descemet's stripping automated endothelial keratoplasty (DSAEK)⁴⁻⁸. It employs mechanical stripping of the host endothelium and replacement with a healthy homograft of a posterior corneal lenticule harvested using an automated microkeratome.

Slit lamp-adapted optical coherence tomograph (SL-OCT) enables non-contact in-depth measurements of the cornea and tissues lining the anterior chamber of the eye⁹⁻¹².

The purpose of this clinical study is to quantify changes of donor and host corneal tissue after DSAEK using organ-cultured corneas and to correlate these findings with the visual acuity during intermediate-term follow-up.

Materials and Methods

15 phakic eyes of 15 consecutive patients, 9 females and 6 males, with a mean age of 72.8 ± 5.0 years, which underwent DSAEK between August 2006 and September 2007 were enrolled in this study. Institutional review board approval was obtained. All patients had clinically significant corneal edema from Fuchs' endothelial dystrophy. In three eyes (20%), simultaneous phakoemulsification with implantation of a posterior chamber IOL in the bag was performed (so-called triple procedure). Postoperatively, all patients underwent quantification of uncorrected VA, best spectacle-corrected VA (BSCVA), slit-lamp examination, measurement of intraocular pressure using

applanation tonometry, and a SL-OCT-examination of the anterior eye segment at 1, 3, 7 days, 4 weeks, 8 weeks and 6 months after the surgery.

All surgeries were performed by two surgeons (FEK and CC) under general anaesthesia. Donor corneas were cultured in the eye bank of the Department of Ophthalmology of the University of Erlangen-Nuremberg, Germany in MEM for 307.7 ± 118.9 hours at 37°C . All donor corneas were subjected to 5% dextran containing medium for 6 days prior to surgery. The post-mortem time of corneal donor tissue was 8.0 ± 6.0 hours with a mean donor age of 78.1 ± 9.7 years. The mean endothelial cell density of donor corneas was 2309 ± 135 cells/mm². The preparation of donor corneal lenticules was performed using a Moria ALTK microkeratome (Moria, S.A., Doylestown, PA) with the blade set to 350 μm -depth, as previously described⁵. In patients undergoing a triple procedure (keratoplasty, cataract extraction and intraocular lens placement), phakoemulsifikation was performed through the same incision. The remaining steps of the surgical procedure have also been previously described^{1 2 6 7 13}.

OCT measurements were performed with a commercially available anterior segment OCT (SL-OCT, Heidelberg Engineering, Luebeck, Germany) which uses a wavelength of 1310 nm. This slit-lamp-adapted OCT system uses a scanning module with a lateral scan range of 6 mm (Haag-Streit BD 900, Wedel, Germany). The optical resolution is between 20 and 100 μm . The OCT image was sampled with an axial digital resolution of 3 μm . The SL-OCT examination of the anterior segment was performed with the subject in the sitting position. The scanning line was positioned onto the corneal vertex in the 180° axis, allowing cross-sectional imaging of the cornea and the entire anterior segment. The measurements of the central corneal thickness were performed manually at the corneal vertex within of 1 mm central zone

(Fig. 5). The peripheral corneal thickness was also measured manually in a distance of 3 mm nasally and temporally of the corneal vertex.

Statistical analysis was performed with SPSS (version 15.0, SPSS Inc., Chicago, USA) using t-test for paired samples and Pearson correlation; statistical significance was set at $P=0.05$.

Results

No intra- or postoperative complications occurred in 14 of 15 eyes (93.3%). Except for one patient who needed a second air injection on day 3 because of partial detachment of the donor lamella, all transplants remained centered and attached on slit-lamp- and OCT-examination. No graft rejection was observed during the follow-up in all our patients. At slit-lamp biomicroscopy, the corneal edema resolved completely within first 4 weeks.

The mean preoperative BSCVA was 20/100 (1-logMAR 0.84 ± 0.63). The mean BSCVA at 6 months postoperative was 20/40 (1-logMAR 0.37 ± 0.18), and was significantly different from preoperative BSCVA ($P<0.0001$, paired-samples t test). After DSAEK, all patients (100%) demonstrated improvement of BSCVA, 3 patients achieved a BSCVA of 20/25 (Fig. 1).

On the first postoperative day, the total central corneal thickness was $1057 \pm 86 \mu\text{m}$. During the follow-up, corneal thickness continuously decreased to $661 \pm 74 \mu\text{m}$ six months after surgery ($P<0.0001$). However, alterations of corneal thickness were only significant within the first 8 weeks and remained stable thereafter (Fig 2a.). The mean peripheral corneal thickness (3 mm nasally and temporally of the vertex) at the first postoperative day was $1222 \pm 78 \mu\text{m}$, compared with $756 \pm 74 \mu\text{m}$ six months after DSAEK (Fig. 3). The decrease of the peripheral corneal thickness was significant at all follow-up visits ($P<0.05$).

Patients with coexisting ocular pathology such as age-related macular degeneration (AMD), primary open angle glaucoma or mild secondary cataract ($n = 5$, 33.3%) were not excluded from our analysis. The Pearson correlation coefficient between the 6-months-BSCVA and central corneal thickness of patients without coexisting ocular pathology was -0.745 ($n=10$, $P=0.021$, Fig. 4a).

At six months, the mean endothelial cell density was 1640 ± 390 cells/mm², compared with preoperative cell density of donor corneas of 2309 ± 135 cells/mm². We found no significant correlation between the duration of organ culture and the BSCVA ($P=0.3$). There was neither a significant correlation between the duration of organ culture and postoperative central corneal thickness at any examination time point, nor between organ culture duration and the thickness of grafted donor tissue at any examination time point. We found also no significant correlation between the thickness of prepared and grafted corneal lenticule immediately after the surgery and the organ culture duration ($P=0.92$).

The SL-OCT allows for selective non-contact measurement of the thickness of the grafted corneal lenticule (Fig. 5). The average thickness of the donor lamella decreased over time as well. At 6 months after DSAEK thickness was 100 ± 38 μ m, compared with 191 ± 56 μ m at the first postoperative day ($P<0.0001$; Fig. 2b). The correlation coefficient between BSCVA and posterior corneal lamella at 6 months after surgery was -0.589 ($P=0.05$, Fig. 4b).

Discussion

DSAEK represents one of the most current developments of posterior lamellar corneal surgery. It differs from previously reported techniques by introducing the use of a microkeratome to avoid manual lamellar dissection of donor cornea. As with other forms of posterior lamellar surgery, the advantages of DSAEK include rapid

visual rehabilitation, minor subjective discomfort after the surgery, predictable postoperative corneal power and low regular postoperative astigmatism. Although a visual acuity of 20/25 and even 20/20 can be achieved after DSAEK, most of our patients reached 20/40 postoperatively, which is similar to previous reports after posterior lamellar keratoplasty⁴⁵. In our series, all donor corneal lenticules were clear at 6 months, all eyes showed improved BSCVA, and three eyes even reached a BSCVA of 20/25.

There are many factors that determine the final visual acuity after DSAEK, such as regular or irregular corneal astigmatism, higher-order optical aberrations, corneal haze, endothelial cell density and the regularity of the posterior donor lenticule. Another factor that might influence the DSAEK outcome is the type of storage of the donor corneas. Worldwide the most common techniques for storing corneas employs the use of hypothermic storage media, such as McCarey-Kaufman (M-K) or Optisol (Plus, GS) at 2-6°C. In contrast, the majority of European eye banks uses organ culture conservation in e.g. MEM medium at 30-37°C with addition of 4-8% dextran for dehydration prior to surgery¹⁴. The technique of hypothermic storage is simple and requires no complex equipment. The storage solutions are commercially available. During storage the corneal tissue remains thin and it is directly available for surgery. The modern hypothermic storage systems, such as the modified M-K medium, K-sol or Optisol claim a storage period of 14-16 days^{14 15}. To reduce the risk of primary graft failure, the recommended storage periods are kept far below the claimed maxima (up to 7-10 days for Optisol)¹⁶. In addition, the time interval between death of the donor and storage of the cornea (so-called post-mortem time) is generally kept within 12 hours or shorter¹⁴.

The technique of organ culture is relatively complicated. The corneas are stored in an incubator at 30-37°C, supplemented with antibiotics and antimycotics. Dehydrating

macromolecules, necessary to maintain normal hydration in vitro, accumulate in the cells and layers of the cornea, leading to swelling of the donor cornea to about twice of its normal thickness^{17 18}. The swelling should be reversed prior to grafting, performed by placement the cornea in the so-called transport medium containing 4-8% dextran¹⁸. The dehydration time varies between cornea banks from less than one up to seven days. Organ culture allows for extended storage period up to 4-5 weeks and yields excellent preservation of endothelial viability¹⁹. We could recently demonstrate that a prolonged organ culture storage improves graft survival after low-risk keratoplasty²⁰.

It is known from penetrating grafts that the thickness of organ-cultured corneal tissue continuously decreases following the first 8 weeks after the grafting, although a constant hydration is achieved by the addition of dextran to the culture medium²¹.

Since it is known from studies investigating penetrating grafts that BSCVA correlates with the graft thickness, we hypothesized that this might be the case in DSAEK as well. Although the patient sample size as well the follow-up period are limited, our study shows that postoperative BSCVA after DSAEK significantly correlates with the central corneal thickness and with the thickness of the grafted lamella six months after the surgery. In addition, our study shows that the thickness of the donor corneal lenticule decreases rapidly after DSAEK in an almost linear fashion (Fig. 2b). During the first six months after surgery, the peripheral corneal thickness behaves in similar manner (Fig. 3). We could not detect a significant correlation between the peripheral corneal thickness and the BSCVA at any follow up visit. In our study, the mean postoperative endothelial cell density was comparable with previous reported results after DSAEK⁵.

Since it is not possible to quantify corneal thickness by slit lamp biomicroscopy, SL-OCT is important for the follow-up of patients after DSAEK. With the slit-lamp-

adapted OCT, the anterior segment of the eye can be easily examined even on the first postoperative day. In a recent study¹², Li et al showed that SL-OCT measurements were reliable and comparable with ultrasound pachymetry.

Furthermore, the best agreement was reported between ultrasound pachymetry and manual SL-OCT measurement, which was also used in our study. With SL-OCT it is possible to measure not only the central corneal thickness, but also the peripheral thickness at any required point of the cornea. The graft-host interface can be visualized as well as irregularities, fibrosis, debris, graft dislocations, Descemet's detachment or lenticule asymmetry.

There are only few studies available comparing clinical outcome after grafting between organ-cultured and hypothermic storage tissues²². A recent study²³ of Rijneveld et al. compared the outcome of corneal grafts preserved in M-K medium versus organ cultured grafts 14 years after penetrating keratoplasty. No significant differences were observed in visual acuity, endothelial cell density and cell loss. Which storage system might benefit survival and transparency of the lamellar grafted corneal tissue needs to be proven in further studies^{24 25}.

References

1. Melles GR, Eggink FA, Lander F, Pels E, Rietveld FJ, Beekhuis WH, et al. A surgical technique for posterior lamellar keratoplasty. *Cornea* 1998;17(6):618-26.
2. Price MO, Price FW, Jr. Descemet's stripping with endothelial keratoplasty: comparative outcomes with microkeratome-dissected and manually dissected donor tissue. *Ophthalmology* 2006;113(11):1936-42.
3. Heindl LM, Hofmann-Rummelt C, Schlotzer-Schrehardt U, Kruse FE, Cursiefen C. Histologic analysis of descemet stripping in posterior lamellar keratoplasty. *Arch Ophthalmol* 2008;126(4):461-4.
4. Koenig SB, Covert DJ. Early results of small-incision Descemet's stripping and automated endothelial keratoplasty. *Ophthalmology* 2007;114(2):221-26.
5. Koenig SB, Covert DJ, Dupps WJ, Jr., Meisler DM. Visual acuity, refractive error, and endothelial cell density six months after Descemet stripping and automated endothelial keratoplasty (DSAEK). *Cornea* 2007;26(6):670-74.
6. Terry MA, Ousley PJ. Replacing the endothelium without corneal surface incisions or sutures: the first United States clinical series using the deep lamellar endothelial keratoplasty procedure. *Ophthalmology* 2003;110(4):755-64.
7. Terry MA, Ousley PJ. Deep lamellar endothelial keratoplasty visual acuity, astigmatism, and endothelial survival in a large prospective series. *Ophthalmology* 2005;112(9):1541-48.
8. Bachmann BO, Pogorelov P, Kruse FE, Cursiefen C. [Patient satisfaction after posterior lamellar keratoplasty (DSAEK)]. *Klin Monatsbl Augenheilkd* 2008;225(6):577-81.

9. Muller M, Hoerauf H, Geerling G, Pape S, Winter C, Huttmann G, et al. Filtering bleb evaluation with slit-lamp-adapted 1310-nm optical coherence tomography. *Curr.Eye Res.* 2006;31(11):909-15.
10. Theelen T, Wesseling P, Keunen JE, Klevering BJ. A pilot study on slit lamp-adapted optical coherence tomography imaging of trabeculectomy filtering blebs. *Graefes Arch.Clin.Exp.Ophthalmol.* 2007;245(6):877-82.
11. Radhakrishnan S, Goldsmith J, Huang D, Westphal V, Dueker DK, Rollins AM, et al. Comparison of optical coherence tomography and ultrasound biomicroscopy for detection of narrow anterior chamber angles. *Arch.Ophthalmol.* 2005;123(8):1053-59.
12. Li H, Leung CK, Wong L, Cheung CY, Pang CP, Weinreb RN, et al. Comparative study of central corneal thickness measurement with slit-lamp optical coherence tomography and visante optical coherence tomography. *Ophthalmology* 2008;115(5):796-801 e2.
13. Cursiefen C, Kruse FE. The Erlangen DSAEK Group [Posterior Lamellar Keratoplassty (DSAEK)]. *Ophthalmologe*, 2008;105(2):183-90.
14. Pels E, Beele H, Claerhout I. Eye bank issues: II. Preservation techniques: warm versus cold storage. *Int Ophthalmol*, 2008:155-63.
15. Aquavella JV, Van Horn DL, Haggerty CJ. Corneal preservation using M-K medium. *Am J Ophthalmol* 1975;80(5):791-9.
16. Camposampiero D, Tiso R, Zanetti E, Ruzza A, Bruni A, Ponzin D. Improvement of human corneal endothelium in culture after prolonged hypothermic storage. *Eur J Ophthalmol* 2003;13(9-10):745-51.
17. Pels E, Schuchard Y. The effects of high molecular weight dextran on the preservation of human corneas. *Cornea* 1984;3(3):219-27.

18. Borderie VM, Baudrimont M, Lopez M, Carvajal S, Laroche L. Evaluation of the deswelling period in dextran-containing medium after corneal organ culture. *Cornea* 1997;16(2):215-23.
19. Armitage WJ, Easty DL. Factors influencing the suitability of organ-cultured corneas for transplantation. *Invest Ophthalmol Vis Sci* 1997;38(1):16-24.
20. Kuchle M, Cursiefen C, Nguyen NX, Langenbucher A, Seitz B, Wenkel H, et al. Risk factors for corneal allograft rejection: intermediate results of a prospective normal-risk keratoplasty study. *Graefes Arch Clin Exp Ophthalmol* 2002;240(7):580-4.
21. Borderie VM, Touzeau O, Bourcier T, Allouch C, Zito E, Laroche L. Outcome of graft central thickness after penetrating keratoplasty. *Ophthalmology* 2005;112(4):626-33.
22. Rijneveld WJ, Beekhuis WH, van RG, Rinkel-van DB, Pels E. Clinical comparison of grafts stored in McCarey-Kaufman medium at 4 degrees C and in corneal organ culture at 31 degrees C. *Arch.Ophthalmol.* 1992;110(2):203-05.
23. Rijneveld WJ, Remeijer L, van Rij G, Beekhuis H, Pels E. Prospective clinical evaluation of McCarey-Kaufman and organ culture cornea preservation media: 14-year follow-up. *Cornea* 2008;27(9):996-1000.
24. Muller LJ, Pels E, Vrensen GF. The effects of organ-culture on the density of keratocytes and collagen fibers in human corneas. *Cornea* 2001;20(1):86-95.
25. Ohno K, Mitooka K, Nelson LR, Hodge DO, Bourne WM. Keratocyte activation and apoptosis in transplanted human corneas in a xenograft model. *Invest Ophthalmol Vis.Sci.* 2002;43(4):1025-31.

Figure legends

Figure 1. Preoperative and postoperative BSCVA of all patients in our study (N=15).

Figure 2: Changes in central corneal thickness (Fig. 2A) and donor corneal lenticule thickness (Fig. 2B) after DSAEK (N=15).

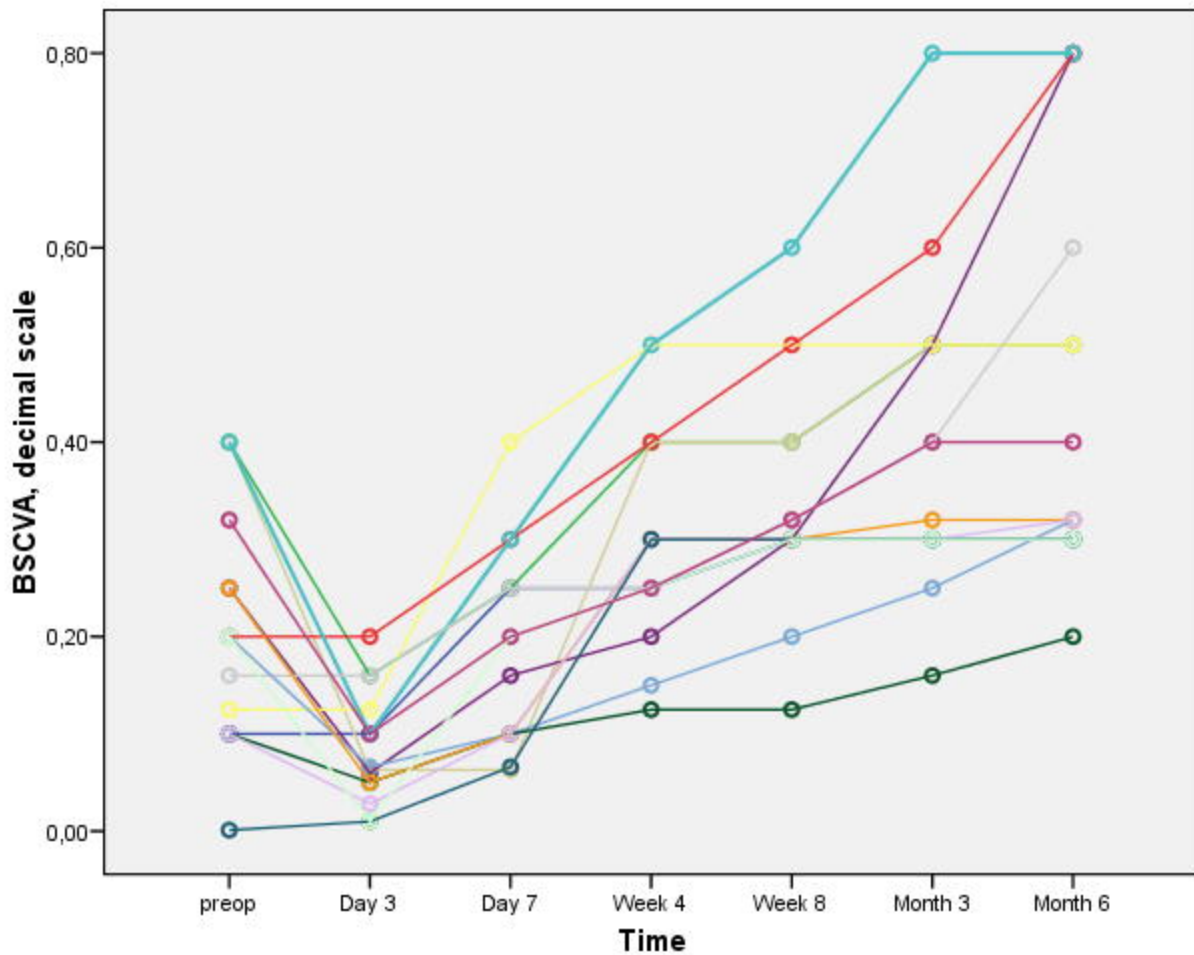
Figure 3: Changes in peripheral corneal thickness during the follow-up (N=15).

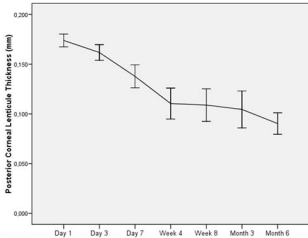
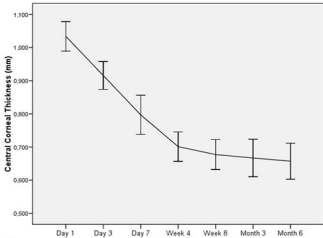
Figure 4: Correlation between central corneal thickness and BSCVA 6 months after DSAEK (N=10, $r = -0.745$, $P=0.021$, Fig. 4A) and between grafted corneal lenticule thickness and BSCVA (N=10, $r = -0.589$, $P=0.05$, Fig. 4B).

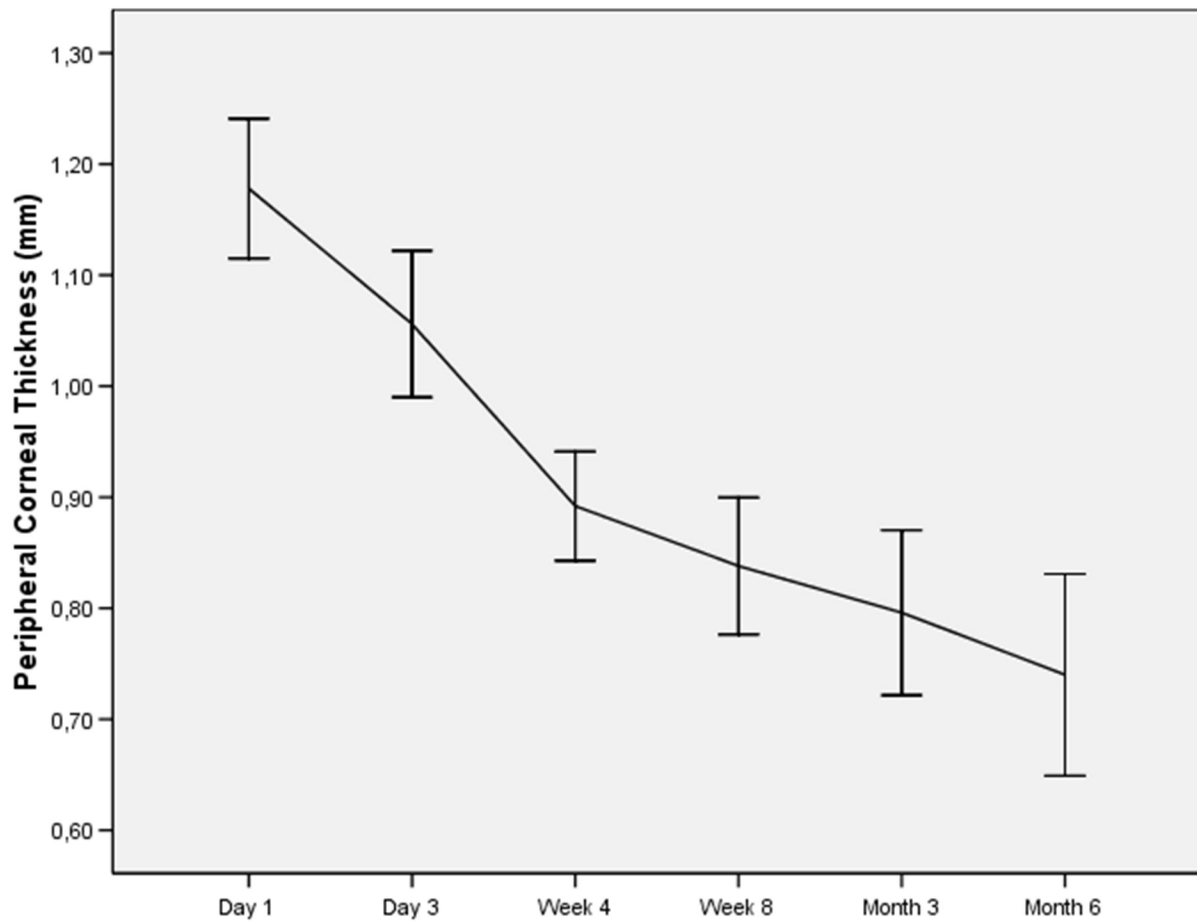
Figure 5. SL-OCT and slit lamp imaging of the cornea before (top, corneal thickness 778 μm) and 6 months after DSAEK (bottom, corneal thickness 555 μm , posterior donor lenticule 77 μm).

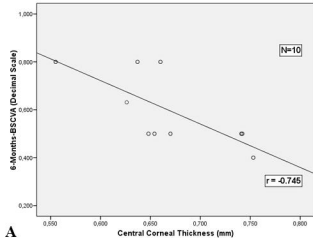
Competing interests: None declared (for all authors).

The Corresponding Author has the right to grant on behalf of all authors and does grant on behalf of all authors, an exclusive licence (or non exclusive for government employees) on a worldwide basis to the BMJ Publishing Group Ltd and its licencees, to permit this article (if accepted) to be published in BJO and any other BMJ Group products and to exploit all subsidiary rights, as set out in our licence (<http://bjo.bmjournals.com//ifora/licence.pdf>)







A**B**