



HAL
open science

Subclinical keratoconus and inflammatory molecules from tears.

Isabel Lema, Tomas Sobrino, Juan A Duran, David Brea, Elio Diez-Feijoo

► **To cite this version:**

Isabel Lema, Tomas Sobrino, Juan A Duran, David Brea, Elio Diez-Feijoo. Subclinical keratoconus and inflammatory molecules from tears.. *British Journal of Ophthalmology*, 2009, 93 (6), pp.820-n/a. 10.1136/bjo.2008.144253 . hal-00477809

HAL Id: hal-00477809

<https://hal.science/hal-00477809>

Submitted on 30 Apr 2010

HAL is a multi-disciplinary open access archive for the deposit and dissemination of scientific research documents, whether they are published or not. The documents may come from teaching and research institutions in France or abroad, or from public or private research centers.

L'archive ouverte pluridisciplinaire **HAL**, est destinée au dépôt et à la diffusion de documents scientifiques de niveau recherche, publiés ou non, émanant des établissements d'enseignement et de recherche français ou étrangers, des laboratoires publics ou privés.

SUBCLINICAL KERATOCONUS AND INFLAMMATORY MOLECULES FROM TEARS.

Isabel Lema MD PhD,¹ Tomás Sobrino PhD,² Juan A. Durán MD PhD,³ David Brea BSc,² Elío Díez-Feijoo, MD PhD.¹

¹ Instituto Galego de Oftalmoloxía, University of Santiago de Compostela, Spain.

² Clinical Neuroscience Research Laboratory, Hospital Clínico Universitario, University of Santiago de Compostela, Santiago de Compostela, Spain.

³ Instituto Clínico-Quirúrgico de Oftalmología, University of Pais Vasco, Spain.

Address for correspondence:

Isabel Lema, MD, PhD.

Instituto Galego de Oftalmoloxía, Hospital de Conxo,
Santiago de Compostela - 15706,
Spain.

E-mail: mariaisabel.lemma@usc.es

Telephone: +34 981951098

Fax number: +34 981951098

Keywords: Keratoconus; Inflammatory molecules; tears.

Word count: 2683.

ABSTRACT

Background/Aims: Tissue degradation in corneal thinning disorders, such as keratoconus (KC), involves the expression of inflammatory mediators. The purpose of this study was to determine the levels of proinflammatory cytokines and matrix metalloproteinase 9 (MMP-9) in tears from both eyes of unilateral keratoconus (KC) patients.

Methods: Thirty patients diagnosed with asymmetric KC (30 KC eyes, and 30 subclinical KC eyes) and 20 normal control subjects (1 eye) were studied in a prospective, cross sectional study.

Keratoconus screening programs were performed on these participants. Ten microliters of tears were collected from each eye. The concentrations of cytokines (interleukin-6 [IL-6] and tumor necrosis factor α [TNF- α]), and MMP-9 were measured by ELISA.

Results: Mean values for IL-6 levels were similar in KC and subclinical KC samples (5.5 [4.9 - 6.9] vs. 5.7 [4.5 - 6.2] pg/mL, $p=0.131$), but significantly higher in relation to the control group (2.2 [1.0 - 4.1] pg/ml, $p<0.0001$). Significant differences were found in TNF- α levels between KC and subclinical KC eyes (5.4 [4.1 - 6.8] vs. 4.8 [4.2 - 6.0] pg/mL, $p=0.032$) and control group (1.8 [1.5 - 2.3] pg/mL, $p<0.0001$). Increased values of MMP-9 were found in KC (59.4 [50.6-66.1] ng/mL) vs. subclinical KC eye (7.0 [4.8-8.6] ng/mL) ($p<0.0001$). MMP-9 levels in the control group (6.1 [3.9 - 8.3] ng/mL) and subclinical KC were similar ($p=0.203$).

Conclusions: IL-6 and TNF- α are overexpressed in the tears of subclinical and KC eyes. Increased MMP-9 levels were found only in the KC eye. These results indicate that the pathogenesis of KC may involve chronic inflammatory events.

INTRODUCTION

Keratoconus (KC) is a primary corneal ectasia, generally bilateral and progressive, with a conical shape as a result of the thinning of the stroma. This thinning induces irregular astigmatism, leading to mild to marked impairment in the quality of vision.[1] KC has its onset at puberty, and it progresses until the third or fourth decade of life.[2]

In most cases, KC initially affects only one eye. As ectasia develops, it may remain restricted to one eye, but more frequently progresses to both. The second eye may develop KC or remain in an unchanging state referred to as the "forme fruste" or subclinical KC.[3] Currently, reported frequencies of unilateral KC, as determined by using computerized videokeratography techniques, range from 0.5% to 4%.[4, 5]

In a recent study, in which 85 unilateral KC patients were monitored over a long period (6 months to 8 years), authors have found that (35.3%) of initially healthy eyes, developed KC during the follow-up period, and (83.3%) of these developed KC within the first 6 years after the initial KC diagnosis. Likewise, the risk of KC onset in initially healthy eyes was higher for those with greater inferior-superior asymmetry (I-S asymmetry). Authors have estimated that over a 16-year period follow-up, about 50% of initially healthy contralateral eyes will develop KC.[6]

Unilateral KC can be studied to provide insight into the pathogenesis of the disease. In fact, given that KC may arise without biomicroscopic signs, examination of the initially healthy eye may be useful for the detection of subclinical changes and progression of the disease.[7]

There is increasing evidence that supports the fact that KC is an inherited genetic disorder. If this were the case, it would be expected to express itself as a binocular condition, even though variable expression of the gene may show differing levels for each eye. The videokeratoscopy has shown almost every case of apparent monocular KC to be different expressions of the condition in the two eyes.[8] Videokeratoscopes enable the detection of small changes in the corneal topography, which is essential for the detection and monitoring of KC.[9,10] Orbscan II, that uses a slit scanning

procedure to map the anterior and posterior corneal surface, may help to identify frustrated or subclinical forms of KC in a short time.[11]

The cornea is part of an integrated system - the ocular surface - which contains specific and non-specific immune molecules. Tissue degradation in thinning disorders, such as keratoconus, involves the expression of inflammatory mediators, such as proinflammatory cytokines, cell adhesion molecules and matrix metalloproteinases.[12-15]. Moreover, previous studies from our group have demonstrated that the levels of proinflammatory cytokines [interleukin-6 (IL-6) and the tumor necrosis factor alpha (TNF- α)] and matrix metalloproteinase-9 (MMP-9) are significantly increased in the tears of patients with KC.[16]

The purpose of this study was to measure levels of proinflammatory cytokines (IL-6 and TNF- α) and MMP-9 in the tears of both eyes from asymmetric KC patients, and to analyze the possible difference between subclinical and KC eyes and normal controls, with a view to contribute to our understanding of whether inflammatory molecules may enhance the progression to KC.

MATERIALS AND METHODS

Patients

We have designed a prospective, cross sectional study in which 30 asymmetric KC patients (30 KC and 30 subclinical KC eyes) and 20 control subjects (1 eye) were enrolled. Asymmetric KC patients (70% male; mean age, 27.1 \pm 8.1 years) were selected from a database of 385 KC patients at the Instituto Galego de Oftalmoloxía, Santiago de Compostela, Spain, which makes up 7.8% of the sample. We studied both eyes from each patient. Fourteen patients wore rigid gas-permeable (RGP) contact lenses in the keratoconic eye. In addition, 3 of them wore a hydrogel contact lens in the fellow eye. Patients were asked not to wear their contact lenses for a week prior to the study. Controls (47.8% male; mean age, 22.6 \pm 6.6 years) were myopic subjects who requested contact lenses, without previous history of keratoconus or eye rubbing, who

presented normal topographic patterns. All patients were expressly cited for the purposes of this study, and all examinations were performed by the same researcher between October 2005 and June 2006. Protocol was approved by the Hospital's Research Ethics Committee, and informed consent was given by all patients and control subjects. Data collected included gender, age, patient's ocular history, medical history (allergy, eye rubbing), and family history.

Inclusion criteria were; 1) Asymmetric KC patients (1 KC eye and 1 subclinical KC eye). Rabinowitz/McDonnell criterion was used for the KC diagnosis.[2] According to the videokeratographic guidelines proposed by Rabinowitz and McDonnell, it is possible to classify an eye as subclinical keratoconus if the simulated central corneal power is greater than 47.2 D but less than 48.7 D, with an inferior-superior dioptric asymmetry greater than 1.4 D, but less than 1.9 D. Eyes presenting central corneal curvature exceeding 48.7D, as well as inferior-superior dioptric asymmetry greater than 1.9 D can be classified as "true keratoconus". 2) The distance visual acuity (DVA) of the subclinical KC eye with value of 1.0 (without correction or with spherical and /or cylindrical compensation < 1.50D).

Exclusion criteria included; 1) Previous surgical intervention in the anterior segment, or childhood corneal trauma or disease. 2) Existence of active or systemic inflammation, or ocular disease, or current treatment with systemic or local anti-inflammatory drugs.

Instrumental

Basic examination instruments were a Topcon biomicroscope, Topcon refraction column, and alphabetic Snellen visual acuity test. As specific examination instruments we used an EyeSys Corneal System (EyeSys Laboratories, Texas, USA), and an Orbscan II corneal topographer (Orbtek, Utah, USA).

Procedure

Our protocol collected the following information: elapsed time from diagnosis of KC in

the first eye, laterality, itching and rubbing, family history of KC and allergies.

After obtaining the best correction, the biomicroscopy exam was performed to detect signs of KC. The corneal topography study was performed using the EyeSys and the Orbscan topographers. Five quantitative topographic parameters were analyzed: simulated keratometry (K) readings, 3 mm irregularity, 5 mm irregularity, posterior elevation and the thinnest point pachymetry of the cornea.

Tear analysis

Tear samples were obtained by capillary flow as previously described.[16] Briefly, tear samples were obtained by capillarity attraction, without nasal stimulation or previous instillation of drugs or vital dyes. We collected 10 μ L of tear sample in micropipettes (Disposable Micro Sampling Pipettes, Corning, NY, USA), placing them in microtubes (Micro Titertube natural 845-TP, TTE Laboratories, Hopkinton MA, USA). A new capillary tube was used for each tear sample. Samples were frozen and stored at -80 °C within 1 hour after collection.

Concentration of cytokines (IL-6 and TNF- α) in tear samples were measured with commercially available quantitative sandwich enzyme-linked immunoadsorbent assay kits (Quantikine, R&D Systems, Minneapolis, MN, USA) and the assays were performed in accordance with the supplier's instructions. MMP-9 levels were determined by commercially available enzyme linked immunoadsorbent assay (ELISA) kits (Biotrack, Amersham Pharmacia Biotech, Buckinghamshire, UK). ELISAs were performed according to the manufacturer's instructions. Samples were diluted 1:20 with sample solvent to a final volume of 300 μ l. All determinations were carried out without knowledge of the corresponding clinical data (blind test), and the final results were multiplied by the dilution factor (x20).

Statistical analysis

Descriptive statistical analyses were performed with percentage for categorical variables. Discontinuous variables were expressed as median [quartiles]. Graphic expressions were elaborated by Box and Whisker plots.

Statistical significance for intergroup differences was assessed by the χ^2 test for categorical variables. Inflammatory molecular markers values were not normally distributed (Kruskal-Wallis analysis). One-way ANOVA and the Mann-Whitney test were performed for comparison between groups. The Spearman correlation coefficient was used to analyze the statistical significance between quantitative topographic parameters (the thinnest point pachymetry of the cornea) and the concentrations of molecular marker (MMP-9). A value of $p < 0.05$ was considered to be statistically significant.

RESULTS

Clinical Features

No age-related or sex-related statistical differences were detected between the groups. The elapsed time from the first diagnosis of KC eye ranged from 1 to 16 years (mean, 5.6 ± 4.3 years). In 22 patients (73.3%) the KC eye was the right one. A family history of KC was reported for 8 patients (26.6%). Eighteen KC patients (60%) reported allergy disease and 15 (50%) a family history of allergy (most commonly to pollen or acaroids). Nineteen patients (63.3%) reported itchy eyes and, in 69% of them itchiness was more marked in the KC eye. For patients who reported itchy eyes, 58% admitted frequent and vigorous eye rubbing on the KC eye. Three subjects (15%) from the control group reported allergic disease, and no eye rubbing.

Mean K_2 was 51.5 ± 7.3 D in the affected eye, versus 43.9 ± 1.4 D in the subclinical KC eye. Astigmatism (dK) was 3.44 ± 2.97 D in the KC eye versus 0.96 ± 1.12 D. Mean of the thinnest point pachymetry was 407.8 ± 59.3 μm in the KC eye, and 499.4 ± 37.6 μm in the contralateral eye. **Table 1** shows the quantitative topographic parameters in KC, subclinical KC and control subjects.

TABLE 1 : QUANTITATIVE TOPOGRAPHIC PARAMETERS.

TOPOGRAPHIC PARAMETERS	KERATOCONUS (N = 30)	SUBCLINICAL KC (N = 30)	CONTROL (N = 20)
Central K (D)	50.9±6.3	43.6±1.7	42.9±0.9
K2 (D)	51.5±7.3	43.9±1.4	43.2±1.1
Astigmatism (D)	3.4±2.9	0.9±1.1	0.6±0.7
Max. K inferior(D)	53.6±5.9	44.2±1.4	43.3±1.2
Post.elevation	0.082±0.035	0.032±0.011	0.023±0.007
Thinnest P (µm)	407.8±59.3	499.4±37.6	534±23.2

Values are expressed in mean (± SD)

Inflammatory mediators

Levels of inflammatory molecules in KC, subclinical KC and controls tears are shown in

Table 2.

TABLE 2: LEVELS OF INFLAMMATORY MOLECULES FROM TEARS.

MOLECULAR MARKER	KERATOCONUS (N = 30)	SUBCLINICAL KC (N = 30)	CONTROL (N = 20)
IL-6 (pg/mL)	5.5 [4.9 – 6.9]*	5.7 [4.5 – 6.2]*	2.2 [1.0 – 4.1]
TNF-α (pg/mL)	5.4 [4.1 – 6.8]*/***	4.8 [4.2 – 6.0]*	1.8 [1.5 – 2.3]
MMP-9 (ng/mL)	59.4 [50.6 – 66.1]*/**	7.0 [4.8 – 8.6]	6.1 [3.9 – 8.3]

Values are expressed in median [quartiles]

*p<0.0001, in relation to control group.

**p<0.0001, in relation to subclinical KC.

***p<0.05, in relation to subclinical KC.

IL-6: interleukin 6; TNF-α: tumor necrosis factor α; MMP-9: matrix metalloproteinase-9.

Patients with asymmetric KC showed significantly higher levels of IL-6 and TNF- α in both eyes. Mean values for IL-6 levels were similar in KC and subclinical KC samples (5.5 [4.9 - 6.9] vs. 5.7 [4.5 - 6.2] pg/mL, $p= 0.131$), but significantly higher in relation to control group (2.2 [1.0 - 4.1] pg/ml, $p<0.0001$). Likewise, significant differences were found in TNF- α levels between KC and subclinical KC eyes (5.4 [4.1 - 6.8] vs. 4.8 [4.2 - 6.0] pg/mL, $p= 0.032$) and control group (1.8 [1.5 - 2.3] pg/mL, $p<0.0001$). On the other hand, increased MMP-9 levels were found only in the KC eye (59.4 [50.6 - 66.1] ng/mL) compared to subclinical KC eye (7.0 [4.8 - 8.6] ng/mL) and control group (6.1 [3.9 - 8.3] ng/mL) (all $p<0.0001$). However, MMP-9 levels in control group (6.1 [3.9 - 8.3] ng/mL) and subclinical KC (7.0 [4.8-8.6] ng/mL) were similar ($p= 0.203$) (**Figure 1**).

Association between levels of MMP-9 and the thinnest point pachymetry of the cornea in KC and subclinical KC eyes was also analyzed. As indicated in **Figure 2**, a significant correlation was found between the concentration of MMP-9 in keratoconus tears and the thinnest point pachymetry, by simple regression analysis. The Spearman coefficient associated with the concentration of MMP-9 and the thinnest point pachymetry in KC eye was -0.374 ($p=0.042$) (**Figure 2A**); and -0.172 ($p=0.362$) for subclinical KC eye (**Figure 2B**).

DISCUSSION

Despite extensive basic and clinical studies of Keratoconus in recent years, the precise mechanisms underlying this pathology still remain largely unknown. In this study, we have performed a detailed analysis of both eyes in patients with asymmetric keratoconus (1 eye with classic signs of KC, and the other with subclinical KC). Our results suggest that in such cases the contralateral eye typically shows certain topographic and pachymetric changes, indicative of subclinical KC. These results are in line with a recent controversy about if true monocular keratoconus can occur.[17] Using Placido disk methods, it may be difficult to detect any changes in the anterior corneal face of the contralateral eye. However, Orbscan reveal a raised posterior face and

pachymetry, indicative of incipient KC. Binder has also reported KC cases in which topographic changes in the contralateral eyes were observed after LASIK surgery, suggesting that these cases are in fact bilateral KC with marked asymmetry, instead of true asymmetric KC.[18]

It likely seems that in most cases, unilateral KC exists only in the early stages of disease, and that in such cases, asymmetry is simply due to unevenness in disease development. In order to try to corroborate the hypothesis that KC is bilateral in last stage, we performed this study about inflammation molecules from tears, which were previously shown to be elevated in KC patients, with the aim of analyze whether inflammatory molecules may enhance the progression of Keratoconus.[16]

It seems becoming clear that mediators of inflammation are present in the keratoconus cornea.[14,19] The presence of collagen degradation products has been reported in the tears of keratoconus patients.[20] In the present study, we demonstrate that the levels of studied cytokines (IL-6 and TNF- α) are significantly increased in the tears from both eyes of patients with asymmetric keratoconus. To our knowledge, this is the first study supporting an important increase of proinflammatory markers in the tear film of subclinical keratoconus eyes. However, MMP-9 levels in tears from subclinical KC eyes are not raised, presenting MMP-9 levels similar to those of control eyes.

Preocular tear film contains numerous specific and non-specific immune components, that include cytokines and cell adhesion molecules.[21,22] Increased levels of these molecules may be a consequence of increased secretion from the corneal epithelium or from another non-corneal cell type. Various cell types, including keratocytes, produce IL-6 in response to stimulation by IL-1 or TNF- α . [23]

In recent years, numerous clinical studies of keratoconus support the idea that its pathogenesis involves an inflammatory component. A variety of changes in the ocular surface of keratoconus patients have been found, including reduced corneal sensitivity, increased fluorescein and rose Bengal staining scores, and abnormal impression cytology such as squamous metaplasia and lower goblet cell density.[24] In the same

way, increased enzymatic activity has been demonstrated in the conjunctiva of keratoconus patients.[25] Overall, it cannot be ruled out that keratoconus originates in events which take place outside the cornea but which are ultimately responsible for the induction of its ectasia.

Association between keratoconus and allergy,[26] as well as the role played by eye rubbing in the development of ectasia are well established. Eye rubbing may well contribute to the development of keratoconus by activating inflammatory mediators.

The tear may be a vehicle of some of the pathogenic protagonists of keratoconus, such as IL-6, TNF- α or MMP-9. Our results indicate that the concentration of inflammatory molecules in tears is associated with both eyes from asymmetric KC patients, although TNF- α is significantly higher in the KC eye, respect to the subclinical one. This difference could explain the differences in progression for both eyes, since IL-1 β and TNF- α have been shown to up-regulate MMP-9 expression in human corneal epithelial cells.[27] Nevertheless, the presence of different classes of enzymes which play a role in the pathological process is not necessarily accompanied by an immediate presentation of corresponding clinical manifestations.[21] We must also bear in mind that there is the possibility that the changes in these inflammatory mediators may be an epiphenomenon of change in corneal structure. It is likely that keratoconus is a disease with a multivariable origin, in which corneal ectasia results from the degradation of stromal collagen.

Thinning and ectasia of the cornea are suggestive of a degraded extracellular matrix. It has become clear that inflammatory events take place in keratoconus and that KC is a bilateral disease that needs inflammatory conditions to progress along the time. The present study reveals that the increase levels of MMP-9 are associated with the corneal thinning; being the minimal corneal thickness related with increases values of MMP-9 in the clinical KC eye. In light of the present results, we believe that when the

KC eye diagnosis is achieved for a patient, especially for young people, there is a risk of progression of this disease.

In conclusion, this study reveals that some cytokines such as IL-6 and TNF- α are overexpressed in the tears of subclinical and Kc eyes in patients diagnosed with unilateral KC. However, the precise role of each of these molecular factors still needs to be defined in further studies. These results indicate that KC cannot be defined as a non-inflammatory disorder and that the pathogenesis of KC progression may involve chronic inflammatory events.

ACKNOWLEDGMENTS

This project has been supported by a grant from the Xunta de Galicia, PGIDIT07PXIB918088PR.

LICENCE FOR PUBLICATION

The Corresponding Author has the right to grant on behalf of all authors and does grant on behalf of all authors, an exclusive licence (or non exclusive for government employees) on a worldwide basis to the BMJ Publishing Group Ltd to permit this article (if accepted) to be published in BJO and any other BMJ PGL products and sublicences such use and exploit all subsidiary rights, as set out in our licence (<http://bjo.bmj.com/ifora/licence.pdf>).

COMPETING INTEREST

None declared.

REFERENCES

1. Krachmer JH, Feder RS, Belin MW. Keratoconus and related noninflammatory corneal thinning disorders. *Surv Ophthalmol* 1984; **28**:293-322.
2. Rabinowitz YS. Keratoconus. *Surv Ophthalmol* 1998; **42**:297-319.
3. Maguire LJ, Lowry JC. Identifying progression of subclinical keratoconus by serial topography analysis. *Am J Ophthalmol* 1991; **112**:41-5.
4. Rabinowitz YS, Nesburn AB, McDonnell PJ. Videokeratography of the fellow eye in unilateral keratoconus. *Ophthalmology* 1993; **100**:181-6.
5. Holland DR, Maeda N, Hannush SB, et al. Unilateral keratoconus: incidence and quantitative topographic analysis. *Ophthalmology* 1997; **104**:1409-13.
6. Xiaohui L, Rabinowitz YS, Rasheed K, et al. Longitudinal study of the normal eyes in unilateral keratoconus patients. *Ophthalmology* 2004; **111**:440-6.
7. Wilson SE, Klyce SD. Screening for corneal topographic abnormalities before refractive surgery. *Ophthalmology* 1994; **101**:147-52.
8. Phillips AJ. Can true monocular keratoconus occur? *Clin Exp Optom* 2003; **86**:399-402.
9. Rabinowitz YS. Videokeratographic indices to aid in screening for keratoconus. *J Refract Surg* 1995; **11**:371-9.
10. Lee LR, Hirst LW, Readshaw G. Clinical detection of unilateral keratoconus. *Aust NZ J Ophthalmol* 1995; **23**:129-33.
11. Rao SN, Raviv T, Majmudar PA, et al. Role of Orbscan II in screening keratoconus suspects before refractive corneal surgery. *Ophthalmology* 2002; **109**:1642-6.
12. Chandler JW. Ocular surface immunology. In: Pepose JS, Holland GN, Wilhelmus KR, eds. *Ocular infection and immunity*. St Louis: Mosby, 1996; 104-11.
13. Bonini S, Lambiase A, Juhas T, et al. Inflammatory immune-associated diseases of the cornea. In: Ben Ezra D, ed. *Ocular inflammation: basic and clinical concepts*. London: Martin Dunitz, 1999; 151-68.

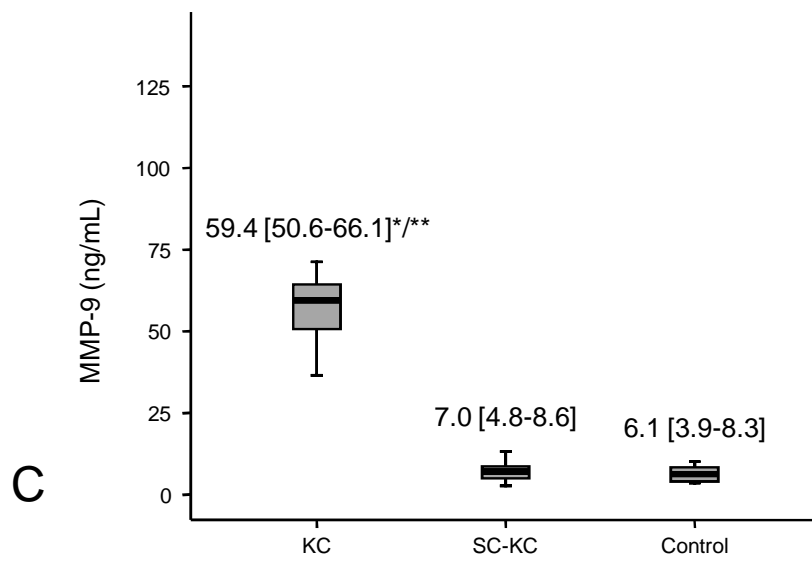
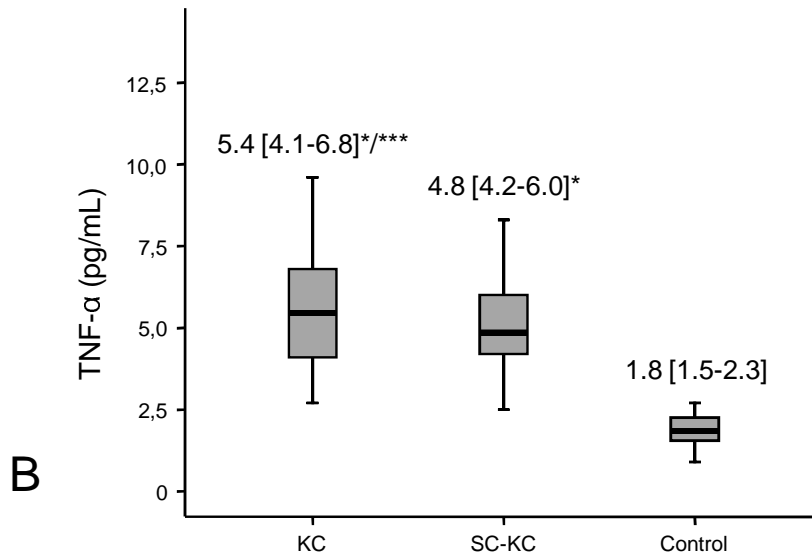
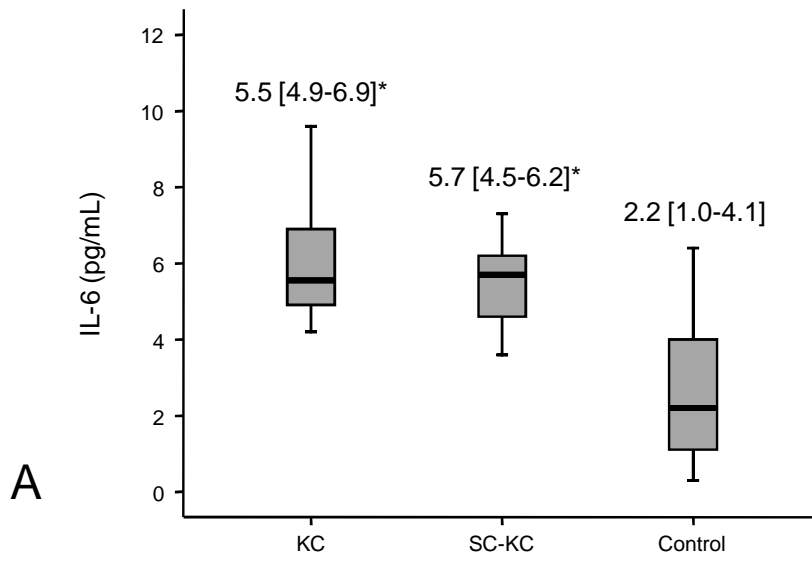
14. Zhou L, Sawaguchi S, Twining SS, et al. Expression of degradative enzymes and protease inhibitors in corneas with keratoconus. *Invest Ophthalmol Vis Sci* 1998; **39**:1117-24.
15. Collier SA, Madigan MC, Penfold PL. Expression of membrane-type 1 matrix metalloproteinase (MT1-MMP) and MMP-2 in normal and keratoconus corneas. *Curr Eye Res* 2000; **21**:662-8.
16. Lema I, Durán JA. Inflammatory molecules in the tears of patients with keratoconus. *Ophthalmology* 2005; **112**: 654-9.
17. Mahon L, Kent D. Can true monocular keratoconus occur? *Clin Exp Optom* 2004; **87**:126.
18. Binder PS. Ectasia after laser *in situ* keratomileusis. *J Cat Refract Surg* 2003; **29**:2419-29.
19. Smith VA, Rishmawi H, Hussein H, Easty DL. Tear film MMP accumulation and corneal disease. *Br J Ophthalmol* 2001; **85**:147-53.
20. Abalain JH, Dossou H, Colin J, Floch HH. Levels of collagen degradation products (telopeptides) in the tear film of patients with keratoconus. *Cornea* 2000; **19**:474-6.
21. Sonoda S, Uchino E, Nakao K, Sakamoto T. Inflammatory cytokine of basal and reflex tears analyzed by multicytokine assay. *Br J Ophthalmol* 2006; **90**:120-22.
22. Solomon A, Dursun D, Liu Z, et al. Pro- and anti-inflammatory forms of interleukin-1 in the tear fluid and conjunctiva of patients with dry-eye disease. *Invest Ophthalmol Vis Sci* 2001; **42**:2283-92.
23. Planck SR, Huang XN, Robertson JE, Rosenbaum JT. Cytokine mRNA levels in rat ocular tissues following systemic endotoxin treatment. *Invest Ophthalmol Vis Sci* 1994; **35**:924-30.
24. Dogru M, Karakaya H, Özçetin H, et al. Tear function and ocular surface changes in keratoconus. *Ophthalmology* 2003; **110**:1110-8.

25. Shen JF, McMahon TT, Cheng EL, et al. Lysosomal hydrolase staining of conjunctival impression cytology specimens in keratoconus. *Cornea* 2002; **21**:447-52.
26. Bawazeer AM, Hodge WG, Lorimer B. Atopy and keratoconus: a multivariate analysis. *Br J Ophthalmol* 2000; **84**:834-6.
27. Li DQ, Lokeshwar BL, Solomon A, et al. Regulation of MMP-9 production by human corneal epithelial cells. *Exp Eye Res* 2001; **73**:449-59.

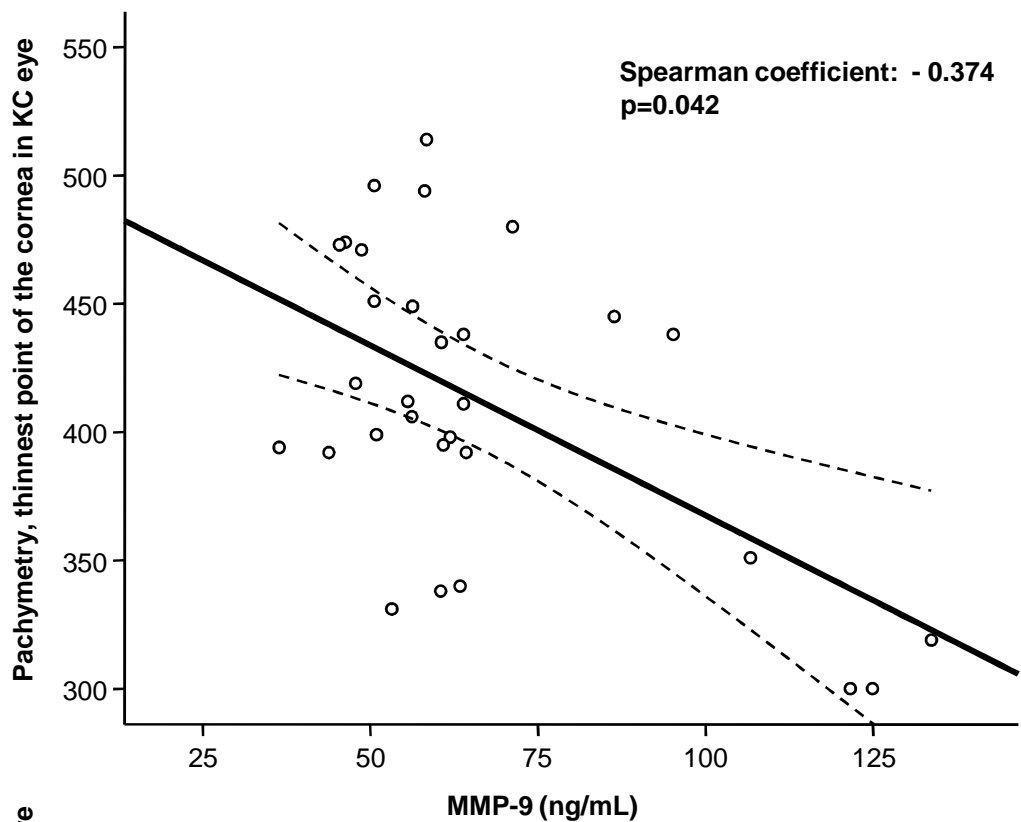
FIGURE LEGENDS

Figure 1 Concentrations of inflammatory molecules in Keratoconus (KC) subclinical (SC-KC) and controls tears. A, Interleukin-6 (IL-6). B, Tumor necrosis factor α (TNF- α). C, Metalloproteinase 9 (MMP-9). * $p < 0.0001$, in relation to the control group; ** $p < 0.0001$, in relation to the SC-KC; *** $p < 0.05$, in relation to the SC-KC.

Figure 2 Correlation between the concentration of MMP-9 and the thinnest point pachymetry of the cornea in KC (2A) and subclinical KC eyes (2B).



A



B

