



HAL
open science

Fundus autofluorescence in subfoveal choroidal neovascularization secondary to pathologic myopia

Maurizio Parodi, Pierluigi Iacono, Giuseppe Ravalico

► **To cite this version:**

Maurizio Parodi, Pierluigi Iacono, Giuseppe Ravalico. Fundus autofluorescence in subfoveal choroidal neovascularization secondary to pathologic myopia. *British Journal of Ophthalmology*, 2009, 93 (6), pp.771-n/a. 10.1136/bjo.2008.139576 . hal-00477807

HAL Id: hal-00477807

<https://hal.science/hal-00477807>

Submitted on 30 Apr 2010

HAL is a multi-disciplinary open access archive for the deposit and dissemination of scientific research documents, whether they are published or not. The documents may come from teaching and research institutions in France or abroad, or from public or private research centers.

L'archive ouverte pluridisciplinaire **HAL**, est destinée au dépôt et à la diffusion de documents scientifiques de niveau recherche, publiés ou non, émanant des établissements d'enseignement et de recherche français ou étrangers, des laboratoires publics ou privés.

Fundus Autofluorescence in Subfoveal Choroidal Neovascularization Secondary to Pathologic Myopia

Maurizio Battaglia Parodi¹ MD,

Pierluigi Iacono², MD

Giuseppe Ravalico¹, MD

¹ Eye Clinic, Azienda Ospedaliero-Universitaria di Trieste

² Fondazione G. B. Bietti per l'Oftalmologia, IRCCS (Istituto di Ricovero e Cura a Carattere Scientifico), Roma, Italy;

Corresponding author:

M. Battaglia Parodi

Eye Clinic, Azienda Ospedaliero-Universitaria di Trieste

Ospedale Maggiore, 34129, Trieste, Italy

fax/phone number 0039 040 772449

maubp@yahoo.it

Licence_for_Publication

The Corresponding Author has the right to grant on behalf of all authors and does grant on behalf of all authors, an exclusive licence (or non exclusive for government employees) on a worldwide basis to the BMJ Publishing Group Ltd to permit this article (if accepted) to be published in BJO and any other BMJPGJL products and sublicences such use and exploit all subsidiary rights, as set out in our licence (<http://bjo.bmj.com/ifora/licence.pdf>).

Competing Interest: None declared.

ABSTRACT

PURPOSE: to describe the fundus autofluorescence (FAF) characteristics of choroidal neovascularization (CNV) associated with Pathologic Myopia (PM), and their modification after photodynamic therapy (PDT).

DESIGN: Open-label, prospective, interventional case series.

METHODS: Forty-two patients affected by subfoveal CNV in PM underwent PDT with a 24-month follow-up. Each patient underwent an ophthalmological examination every three months, including FAF and fluorescein angiography. FAF distribution was qualitatively evaluated at the CNV site, around the CNV and outside the area affected by CNV.

RESULTS: CNV at baseline showed high FAF signal with uniform distribution, or with some spots of low FAF internally, in 64% and 36% of cases, respectively. At the 3-month control after PDT, the CNV retained the same response, but a round halo of increased signal extending beyond the site of the PDT application was detectable around the CNV. At the end of the follow-up, a high or a low FAF signal was detected in 40% and 60% of cases, respectively.

CONCLUSION: CNV secondary to PM shows a specific, high signal, FAF pattern. A round halo of increased FAF signal surrounding the CNV was detectable after PDT application, whereas a FAF signal progressive reduction was visible at and around the CNV site from the sixth month. A high FAF signal at the CNV site is associated with an improved visual acuity outcome at the 2-year follow-up. Further studies to correlate the morphological and functional features are advisable, especially by means of microperimetric analyses and with a longer-term follow-up.

KEY WORDS

Fundus autofluorescence, Choroidal neovascularization, Retinal pigment epithelium, Photodynamic therapy, Pathologic myopia

INTRODUCTION

Fundus autofluorescence (FAF) is determined mainly by the lipofuscin component within the retinal pigment epithelium (RPE) cells.¹ Lipofuscin originates predominantly from the incomplete digestion of outer segments of photoreceptors and accumulates progressively with age.²

The role of RPE lipofuscin in the pathogenesis of Age-related Macular Degeneration (AMD) has been studied chiefly by means of autofluorescent images, especially as regards geographic atrophy and choroidal neovascularization (CNV).³⁻⁶ As yet there are no data concerning either the distinguishing characteristics of the FAF pattern in Pathologic Myopia (PM) or CNV, one of its most feared complications. Myopic CNV is characteristically a type-two CNV, located between the sensory retina and RPE, and is coated with a double RPE layer.⁷ RPE modifications, as evidenced by lipofuscin alterations and visualizable by means of FAF, may help provide a better picture of the clinical characteristics and prognosis of CNV secondary to PM.

The aim of the present study is to describe the FAF characteristics of CNV associated with PM, and their modification after photodynamic therapy (PDT).

METHODS

The study prospectively enrolled patients referred to Trieste Eye Clinic between January 2003 and January 2006 with a diagnosis of subfoveal CNV in PM. The research adhered to the tenets of the Declaration of Helsinki, and investigational review board approval was obtained. Each patient was informed of the purpose of the research and provided signed consent to all procedures.

Inclusion criteria were: CNV secondary to PM, subfoveal CNV (including both CNV under the geometric centre of the foveal avascular zone and CNV involving the fixation point), evidence of classic CNV on FA, greatest linear dimension under 5400 microns, best-corrected visual acuity (BCVA) from 20/200 to 20/40 on ETDRS charts, and symptom duration of under one month. PM was defined as an eye requiring a distance correction of at least -6.0 diopters (spherical equivalent) and/or axial length was at least 26.5 mm, as well as fundus abnormalities – other than subretinal

CNV – compatible with PM, including one or more of the following features: lacquer cracks, peripapillary atrophy, macular geographic atrophy, diffuse fundus pallor.

Exclusion criteria were: evidence of any condition other than PM associated with CNV, any significant ocular disease that had compromised or could compromise vision in the study eye, active hepatitis or clinically significant liver disease, porphyria or other porphyrin sensitivity, pregnancy, intraocular surgery within the last 2 months or capsulotomy in the study eye within the last month, and previous laser photocoagulation.

Each patient underwent an ophthalmological examination, including BCVA on standard ETDRS charts and fluorescein angiography (FA) at baseline, every 3 months over a planned follow-up of 24 months. Subfoveal CNV had to be treated with PDT, adhering strictly to VIP guidelines. FAF was performed using a Heidelberg Retina Angiograph (Heidelberg Engineering, Germany), averaging series of 9–15 digital images to reduce noise. The distribution of FAF was evaluated at the site of the CNV, around the CNV and outside the area affected by the CNV (background autofluorescence). FAF was defined as low (signal lower than background), high (signal higher than background) or unchanged compared with background (signal indistinguishable from background). Distribution of FAF outside the area affected by the CNV (background autofluorescence) was classified as homogeneous, reticular (ill-defined small areas of diminished autofluorescence surrounded by areas of greater autofluorescence), focal (focal areas of increased autofluorescence) or mixed (focal and reticular patterns of autofluorescence).

RESULTS

Forty-two out of 46 patients affected by subfoveal CNV in PM were recruited. Four patients were excluded because they had already undergone PDT in other centres. The mean number of PDT sessions was 2.5 (range: 1-4) in the first year and 1.5 (range: 1-3) in the second year. All the eyes showed a newly-diagnosed subfoveal CNV with classic aspect, on the basis of FA findings.

In all the eyes studied, there was a high FAF signal in correspondence with the CNV site at baseline (Fig. 1). More specifically, two subgroups could be singled out: 27 eyes (64%) showed a high FAF signal with uniform distribution (Fig. 1, 2), whereas 15 (36%) eyes displayed an irregular pattern characterized by high FAF signal, containing spots of low FAF inside (Fig. 3). A fine hyperautofluorescent signal bordered the CNV at least in part in all the cases, which was found on FA to consist of a thin area of blocked fluorescence around the CNV. The FAF pattern appeared to be homogeneous outside the CNV.

At the 3-month control after the PDT treatment, the CNV retained the same high autofluorescent response, displaying a distinct demarcation. A round halo of increased signal extending beyond the site of the PDT application was detectable surrounding the CNV in all the cases (Fig. 1, 2). The remaining posterior pole showed a homogeneous pattern of FAF.

The subsequent follow-up examinations revealed that the high autofluorescent signal corresponding to the CNV site gradually faded away (Fig. 1, 2). In particular, at the end of the 24-month follow-up, 17 CNVs (40%) showed a uniformly high FAF response, whereas 25 CNVs (60%) revealed a central low FAF signal (Fig. 3). This latter group was composed of all the 15 CNVs displaying spots of low FAF and by 10 CNVs characterized by a high FAF signal at baseline.

The halo of high autofluorescence neighboring the CNV was still visible over the whole follow-up, even though it displayed a partial signal reduction at the 24-month examination.

Overall, a progressive reduction of the FAF signal was visible at and around the CNV site from the 6th month, probably due to the progressive atrophic RPE changes.

Analysis of the correlation between BCVA and intensity of FAF signal at baseline examination revealed the absence of any statistically significant difference, when the subgroup characterized by high FAF signal was compared with the subgroup with irregular FAF. By contrast, a statistically significant difference was registered at the end of the follow-up between BCVA values in the eyes retaining high FAF signal and those displaying irregular FAF signal ($p < 0.001$) (Fig. 4).

Moreover, at the end of the follow-up a statistically significant deterioration of BCVA was registered in the subgroup with irregular FAF ($p= 0.015$), whereas BCVA did not reveal any statistically significant change in the subgroup retaining high FAF signal. A statistically significant difference ($p<0.001$) was observed within the subgroup of eyes characterized at baseline by a high FAF signal and comparing BCVA in eyes retaining the same high FAF pattern with that of the developing irregular FAF pattern.

DISCUSSION

Being a type 2 CNV, situated between the sensory retina and RPE and entirely coated by RPE, myopic CNV has specific histopathological features. PM-related CNV is characterized by an RPE layer on its inner surface and an inverted RPE layer on its outer surface, creating a twofold RPE layer.⁷ All these histopathological characteristics are to be borne in mind when analyzing the aspects found on FAF. Myopic CNV generally displays a high autofluorescent signal at its site, to be explained by the presence of a double RPE layer wrapping the CNV. In this regard, this FAF pattern is completely different from that typical of classic CNV secondary to AMD. Indeed, this form of classic CNV shows a low autofluorescent signal, probably due to the blockage of the autofluorescence caused by the presence of the CNV in the subretinal space.⁵ Nevertheless, from the baseline examination, 36% of eyes showed some spots of low FAF signal within the high FAF response of the CNV. These hyporeflective spots can be explained as areas of damaged RPE.

The presence of a fine margin of high FAF bordering the CNV at baseline can be interpreted as being determined by the RPE cell proliferation around the CNV.⁸ The most intriguing feature is the development of a round halo with high autofluorescence encircling the CNV, detectable after the first PDT administration. This is a newly reported feature and is not detectable on FA. This halo may be directly linked to PDT application, but interestingly the visible limits of the circle lie outside the area exposed to the laser light. The PDT-induced production of lipofuscin within the

RPE cells may explain the development of such a halo. It is noteworthy that the effect on the RPE extends beyond the boundary of the area directly affected by the laser.

Moreover, a prolonged follow-up reveals a gradual reduction of the autofluorescent signal, detectable both at the CNV site and in the surrounding areas, probably owing to the atrophic RPE changes.

The effect on the RPE of PDT administered for PM-related CNV has been previously analyzed on FA⁹, revealing progressive RPE alterations, such as accentuation of the pigmentary zone surrounding the CNV and RPE depigmentation and atrophy.⁹ All these features have a correlation with FAF, manifested by the gradually decreasing autofluorescent signal, both at the CNV site and at the adjacent retina.

RPE involvement due to PDT is a matter of debate.^{10,11} Even though no ultrastructural study has specifically targeted RPE cell alterations induced by PDT, speculative deductions suggest that PDT acts on RPE, leading to clinical and angiographic results.

The presence of normal or near-normal FAF over areas of CNV in AMD has been correlated to a normal or near-normal RPE, resulting in a better functional prognosis⁴, and our results support this conclusion. The comparison between the subgroup retaining a high FAF signal and the subgroup developing a low signal at the end of the follow-up revealed a statistically significant difference in the BCVA. This finding suggests that the initial FAF pattern can provide information regarding the final functional outcome after the PDT application.

The present study cannot explain the reasons underlying the different FAF pattern detectable at baseline. The FAF pattern may reflect a number of features, including RPE cell viability, CNV duration, presence of fluid or blood or biochemical changes that are not directly quantifiable yet.

We acknowledge that this study has important limitations, especially regarding the lack of an untreated control group. The small sample of patients did not allow a stratification of BCVA values in the subgroups. Moreover, the study aims at a qualitative rather than a quantitative analysis of the

FAF distribution and looks at the identification of changes in autofluorescence patterns. It is possible that a quantitative evaluation of the FAF will reveal more important details.

In conclusion, CNV secondary to PM exhibits a specific, high-signal, FAF pattern. A round halo of increased FAF signal surrounding the CNV is detectable after PDT application. Overall, a progressive reduction of the FAF signal was visible at and around the CNV site from the 6th month, probably due to the progressive atrophic RPE changes. A high FAF signal at the CNV site is associated with a better visual acuity outcome at the 2-year follow-up. Further studies are advisable to correlate the morphological and functional features, especially by means of microperimetric analyses and including a longer-term follow-up.

REFERENCES

- 1) Delori FC, Dorey CK, Staurenghi G, et al. In vivo fluorescence of the ocular fundus exhibits retinal pigment epithelium lipofuscin characteristics. *Invest Ophthalmol Vis Sci* 1995;36:718–29.
- 2) Feeney L . Lipofuscin and melanin of human retinal pigment epithelium. Fluorescence, enzyme cytochemical, and ultrastructural studies. *Invest Ophthalmol Vis Sci* 1978;17:583–600.
- 3) Holz FG, Bellman C, Staudt S, et al. Fundus autofluorescence and development of geographic atrophy in age-related macular degeneration. *Invest Ophthalmol Vis Sci* 2001;42:1051–6.
- 4) Dandekar SS, Jenkins SA, Peto T, et al. Autofluorescence imaging of choroidal neovascularization due to age-related macular degeneration. *Arch Ophthalmol* 2005;123:1507–13.
- 5) McBain V, Townend J, Lois N. Fundus autofluorescence in exudative age-related macular degeneration. *Br J Ophthalmol* 2007;91:491-496.
- 6) Framme C, Bunse A, Sofroni R, Thalhammer T, Walter A, Sachs HG, Gabel VP. Fundus autofluorescence before and after photodynamic therapy for choroidal neovascularization secondary to age-related macular degeneration. *Ophthalmic Surg Lasers Imaging*. 2006;37:406-414.
- 7) Grossniklaus HE, Gass JDM: Clinicopathologic correlations of surgically excised type 1 and type 2 submacular choroidal neovascular membranes. *Am J Ophthalmol* 1998;126:59-69.
- 8) Miller H. Miller B, Ryan SJ: The role of retinal pigment epithelium in the involution of subretinal neovascularization. *Invest Ophthalmol Vis Sci* 1986;27:1644-1652.
- 9) Parodi MB, Da Pozzo S. Ravalico G. Retinal pigment epithelium changes after photodynamic therapy for choroidal neovascularization in pathological myopia. *Acta Ophthalmol Scand*. 2007 ;85:50-4.

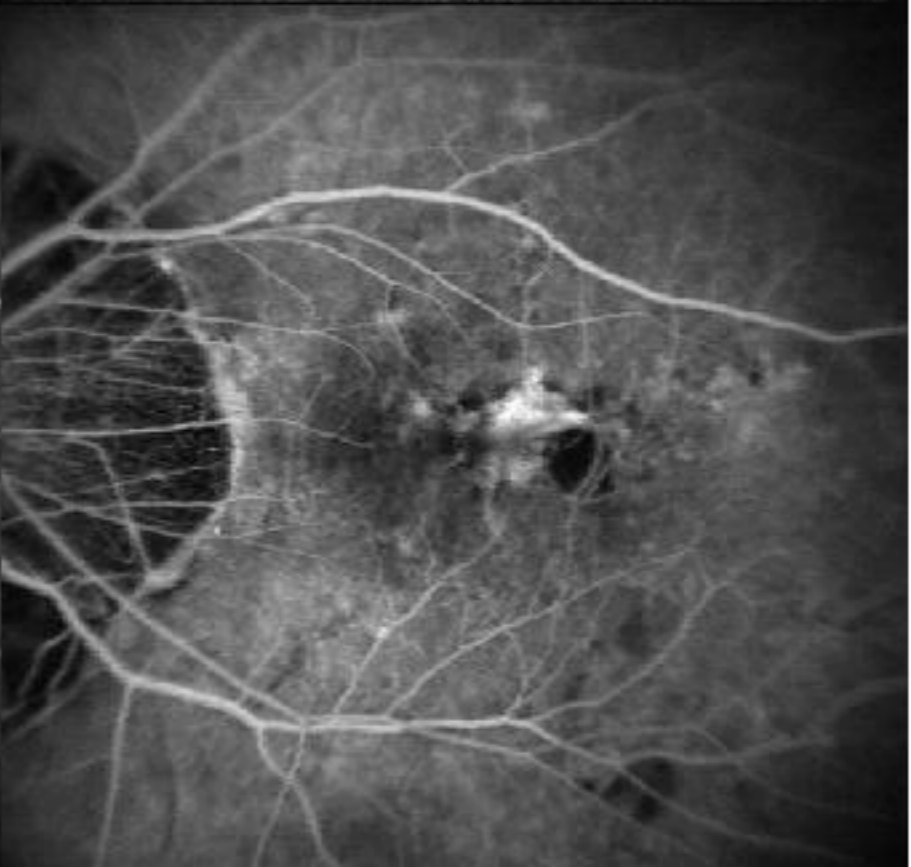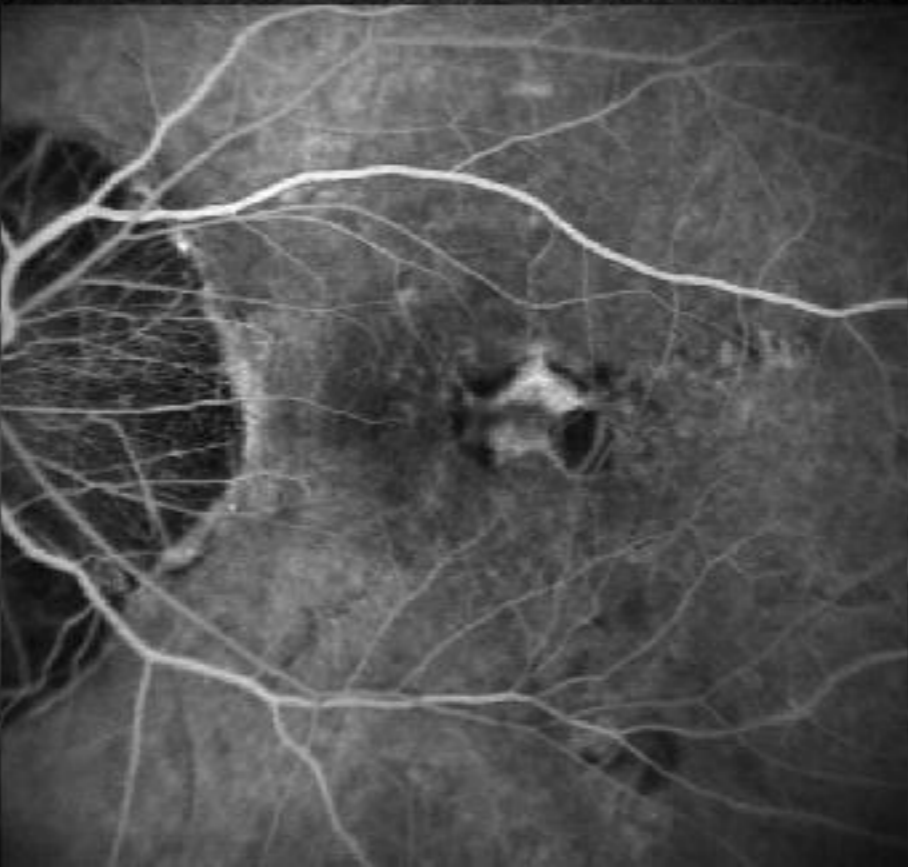
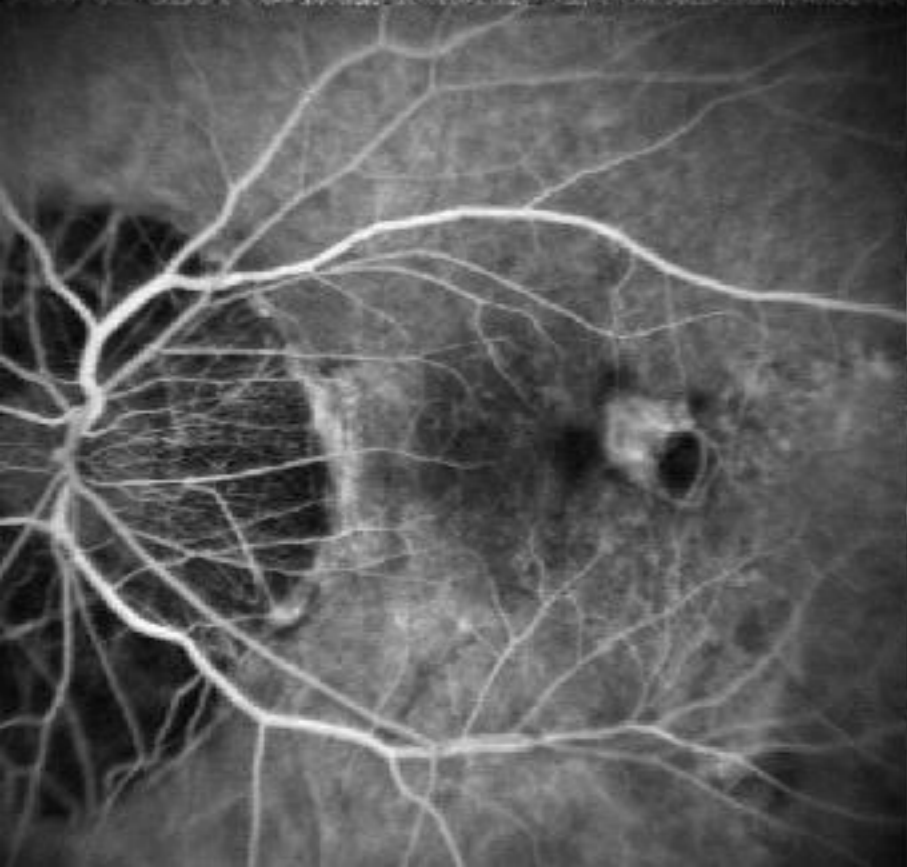
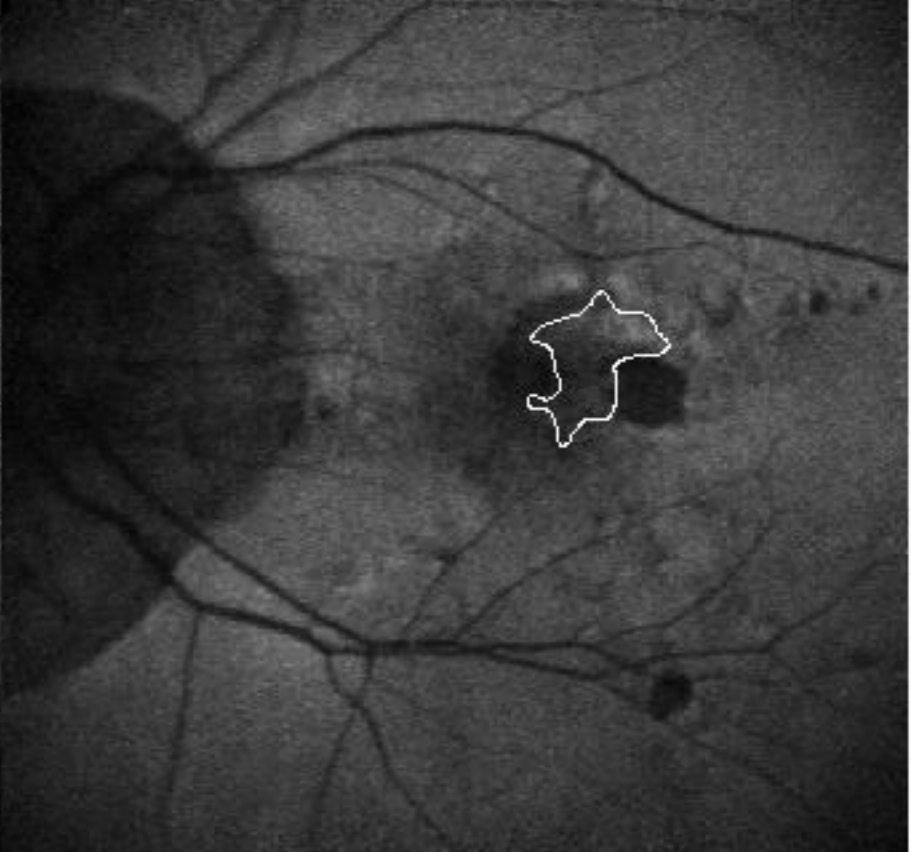
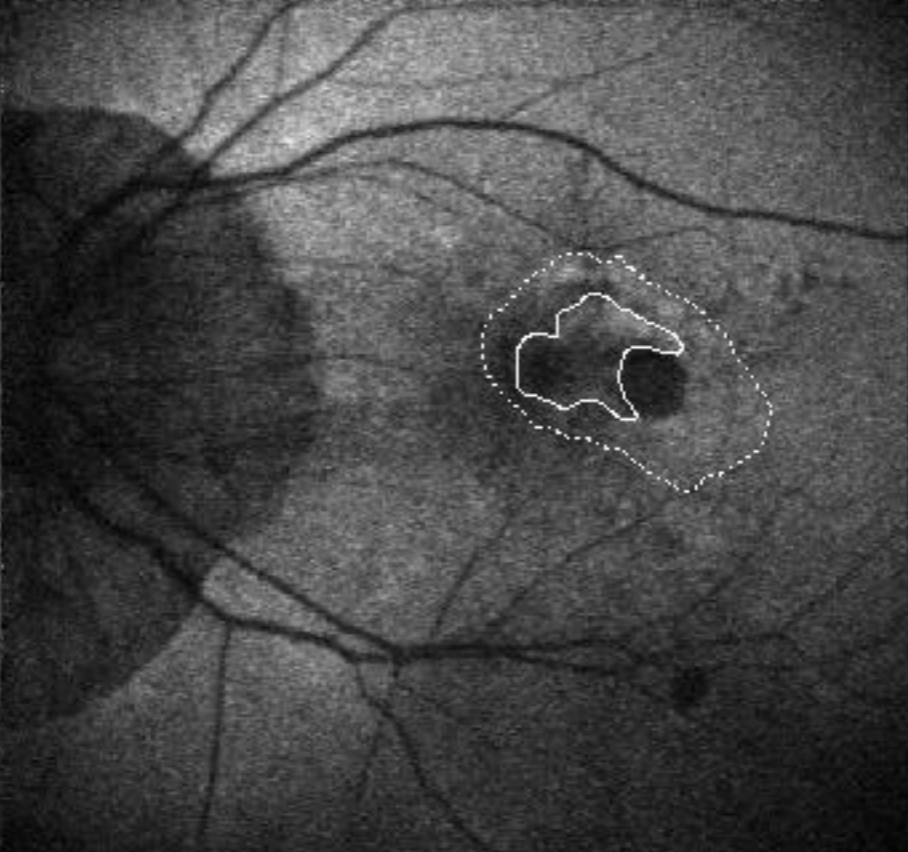
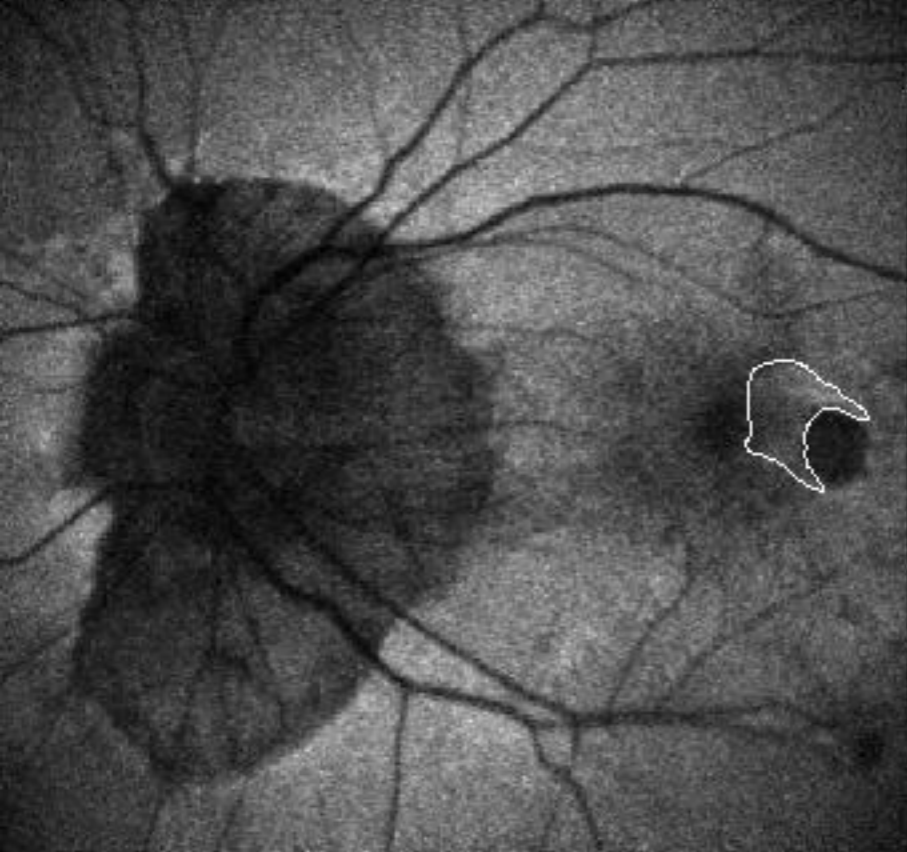
- 10) Parodi MB, Da Pozzo S, Ravalico G: Angiographic features after photodynamic therapy for choroidal neovascularisation in age related macular degeneration and pathological myopia. *Br J Ophthalmol* 2003;87:177-183.
- 11) Parodi MB. The origin of the hypofluorescent spot after photodynamic therapy. *Am J Ophthalmol* 2003;136:584-585.

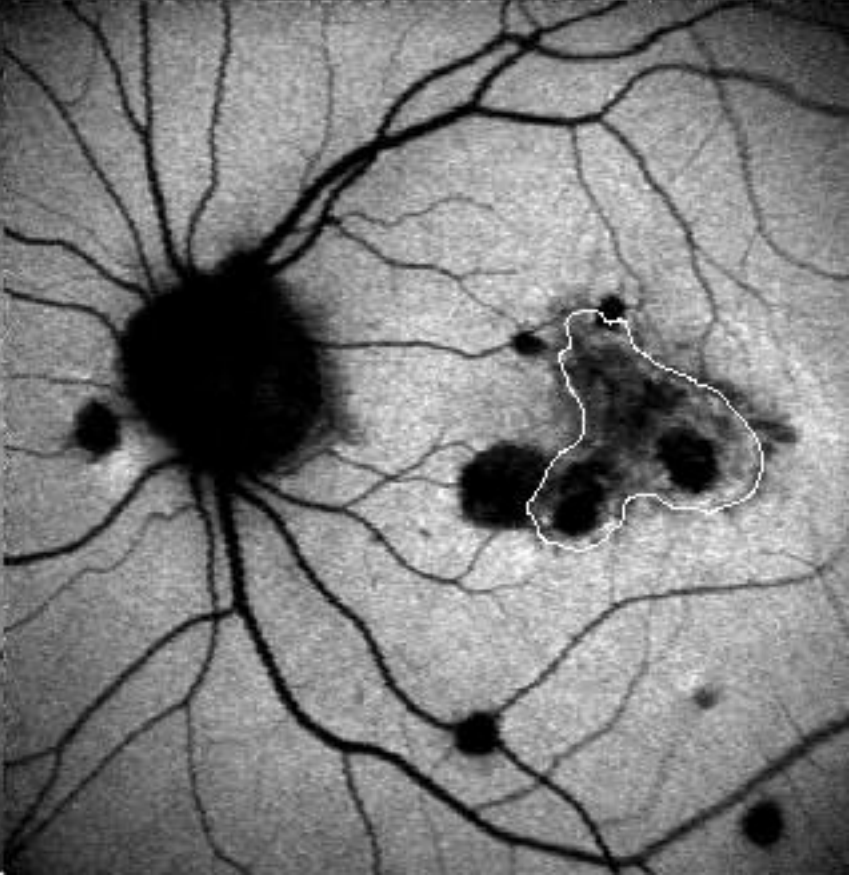
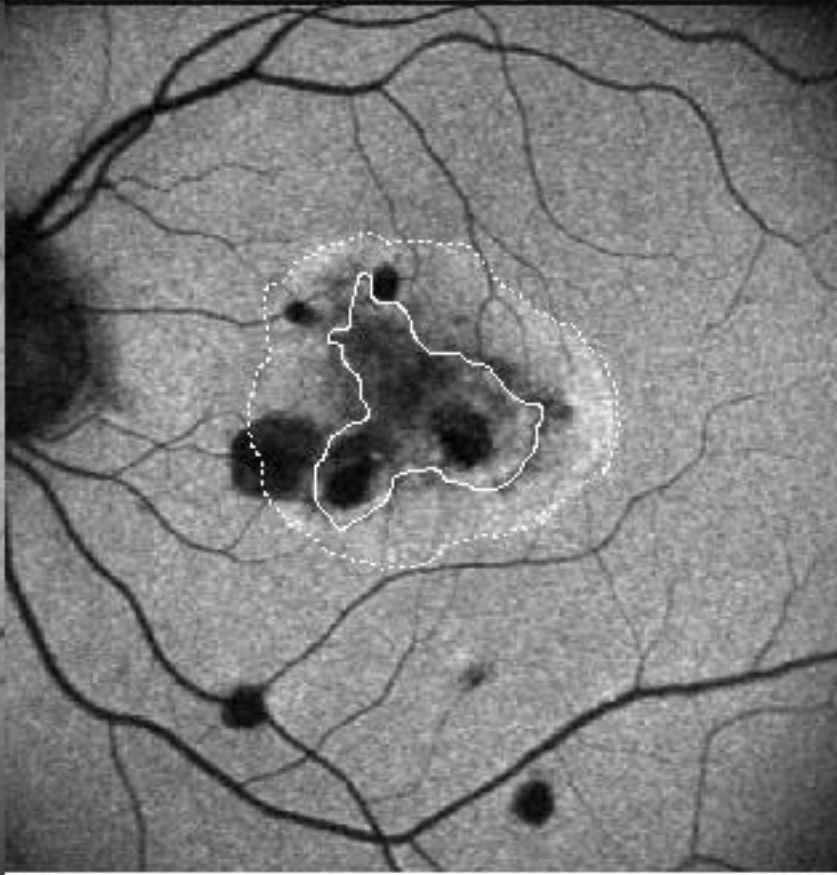
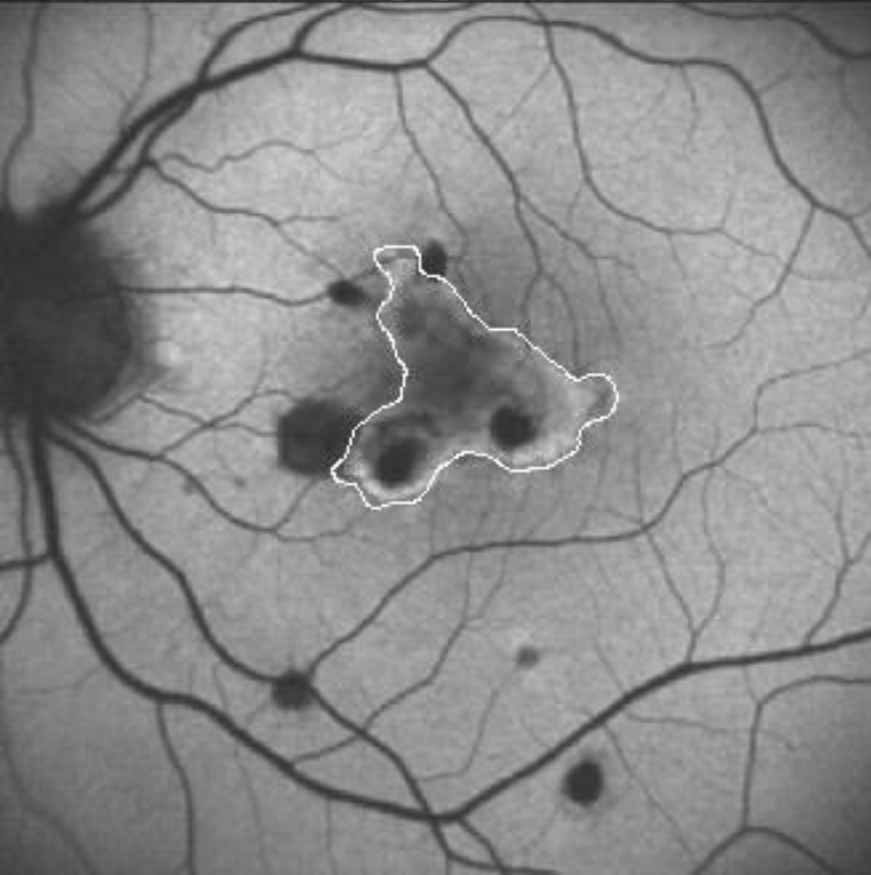
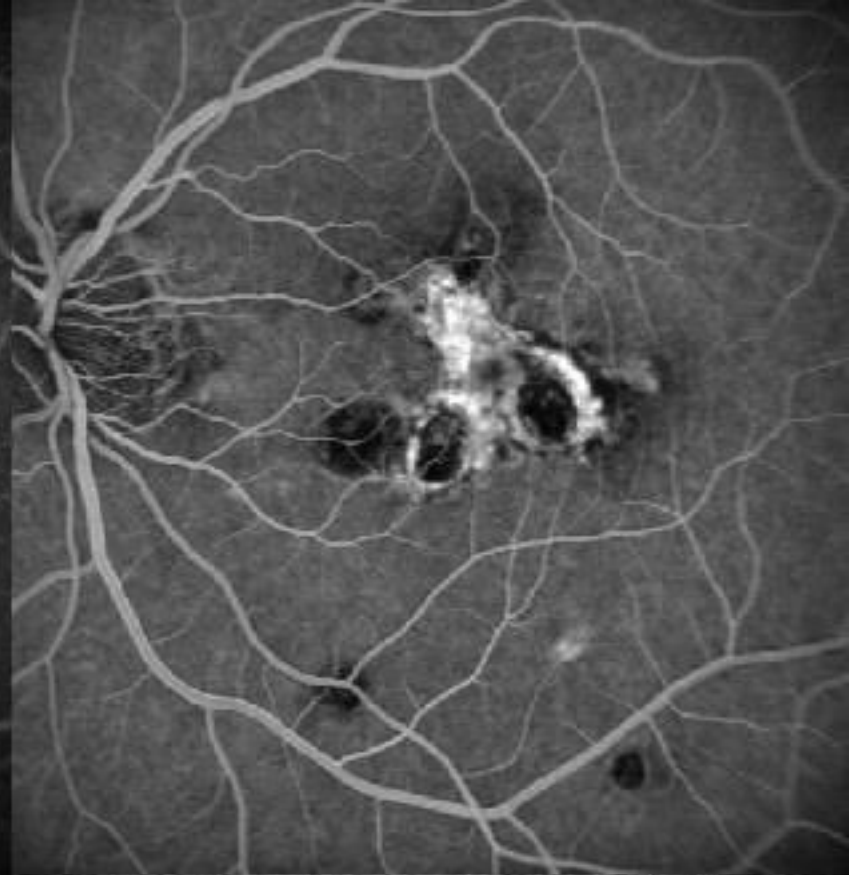
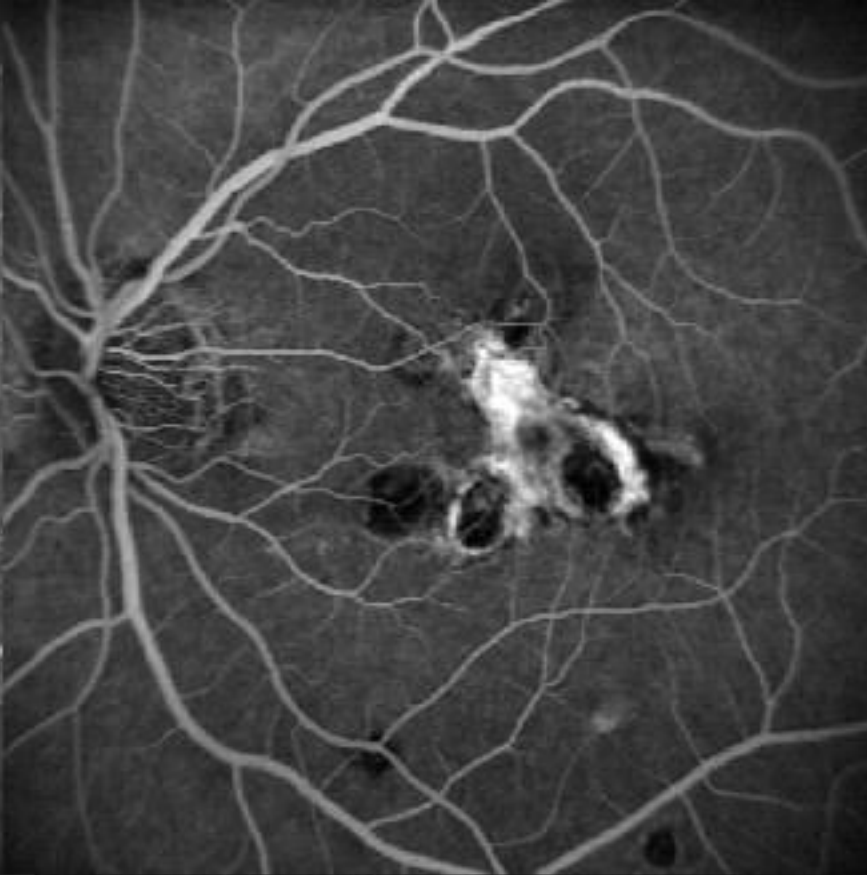
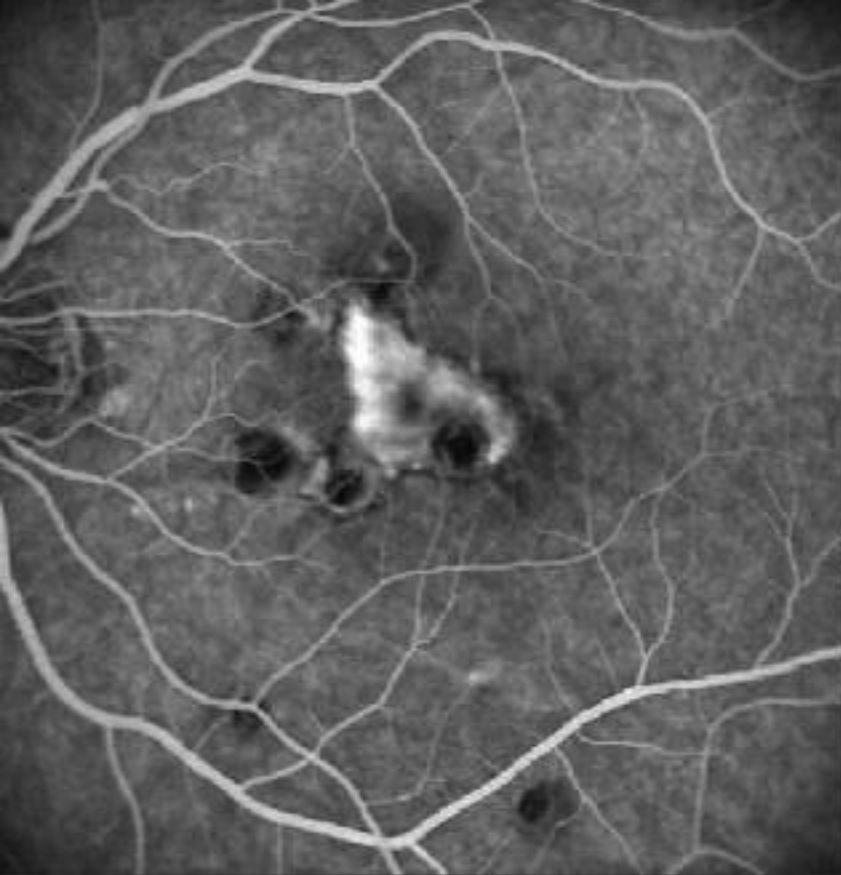
FIGURE LEGENDS

Fig. 1. Top left: FAF of a subfoveal CNV showing a high signal before PDT (the white line delineate the CNV). Bottom left: FA of the same case at baseline. Top center: FAF of the same case 3 months after PDT. The CNV retained the same high autofluorescent response, but a round halo of increased signal exceeding the site of the laser application was detectable (the white line and the dashed line delineate the CNV and the hyperautofluorescent halo, respectively). Bottom center: FA of the same case at the 3-month examination revealing a stabilization of the CNV. Top right: FAF of the same case at the 24-month examination. The CNV displays a uniformly high response (white line). Bottom right: FAF of the same case at the 24-month visit revealing a staining of the lesion.

Fig. 2. Top left: FA of a subfoveal CNV at baseline. Bottom left: FAF of the same case showing a high signal before PDT (white line delineate the CNV). Top center: FA of the same case 3 months after PDT showing a reduction of dye leakage. Bottom center: The CNV retained a high autofluorescent response, but was surrounded by a halo of increased signal which exceeds the area treated with PDT (white line and the dashed line demarcate the CNV and the hyperautofluorescent halo, respectively). Top right: FA of the same case at the 24-month examination. Bottom right: FAF of the same case at the 24-month visit. The CNV reveals an irregular response with some spots of low FAF (white line).

Fig. 3. Top left: FA of a subfoveal CNV at baseline. Top right: FAF of the same case at baseline showing an irregular pattern with a high FAF signal which contains spots of low FAF inside (white line delineate the CNV). Bottom left: FA of a subfoveal CNV at the 24-month examination showing absence of leakage. Bottom right: FAF of the same case at the 24-month examination displaying a low FAF signal.





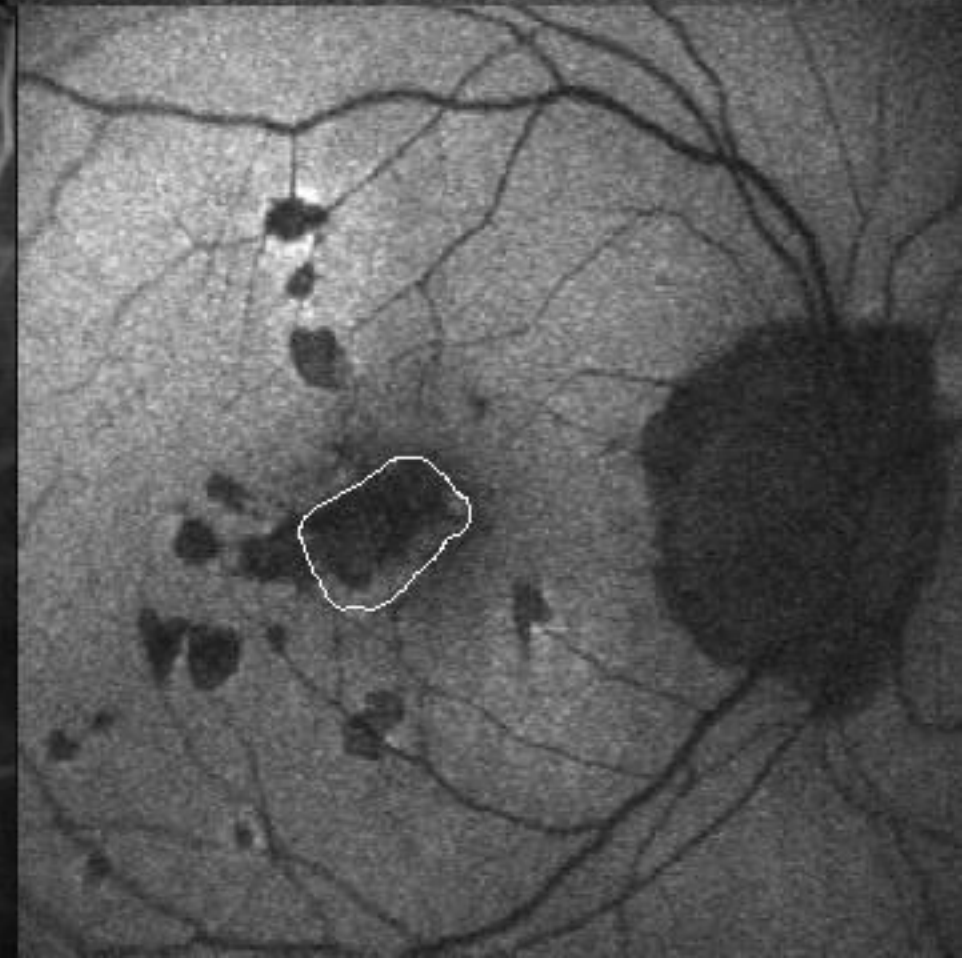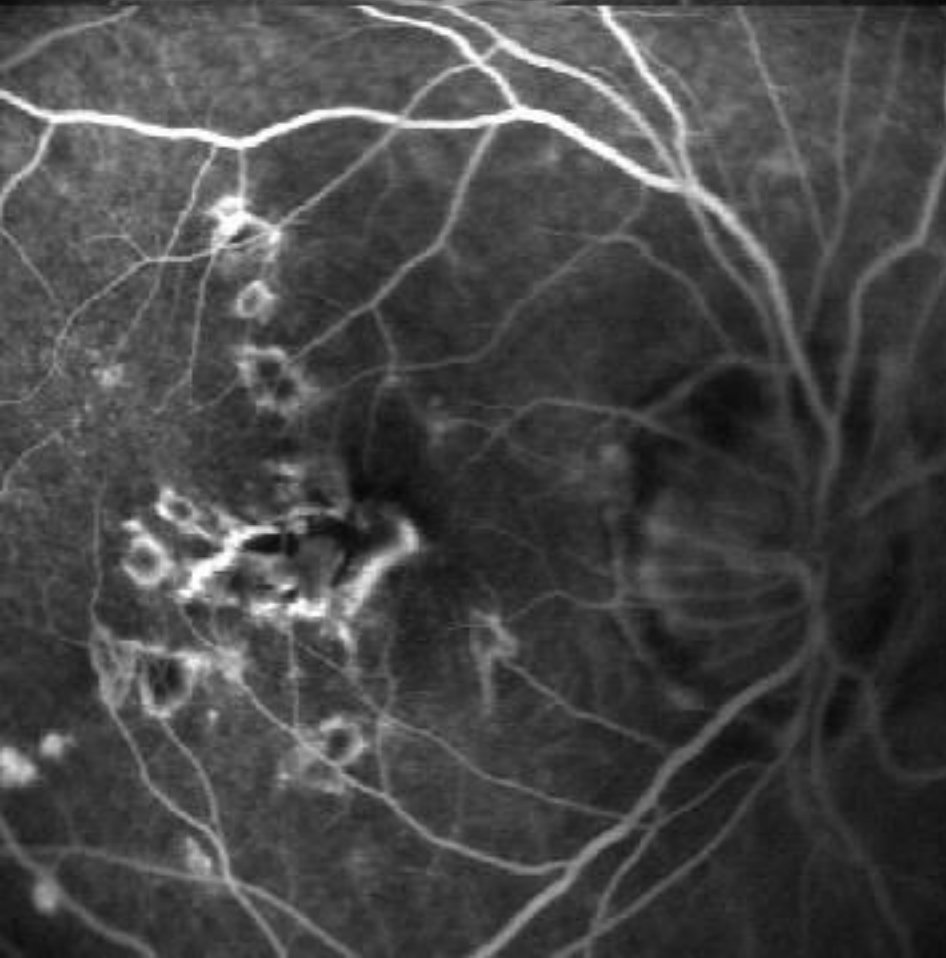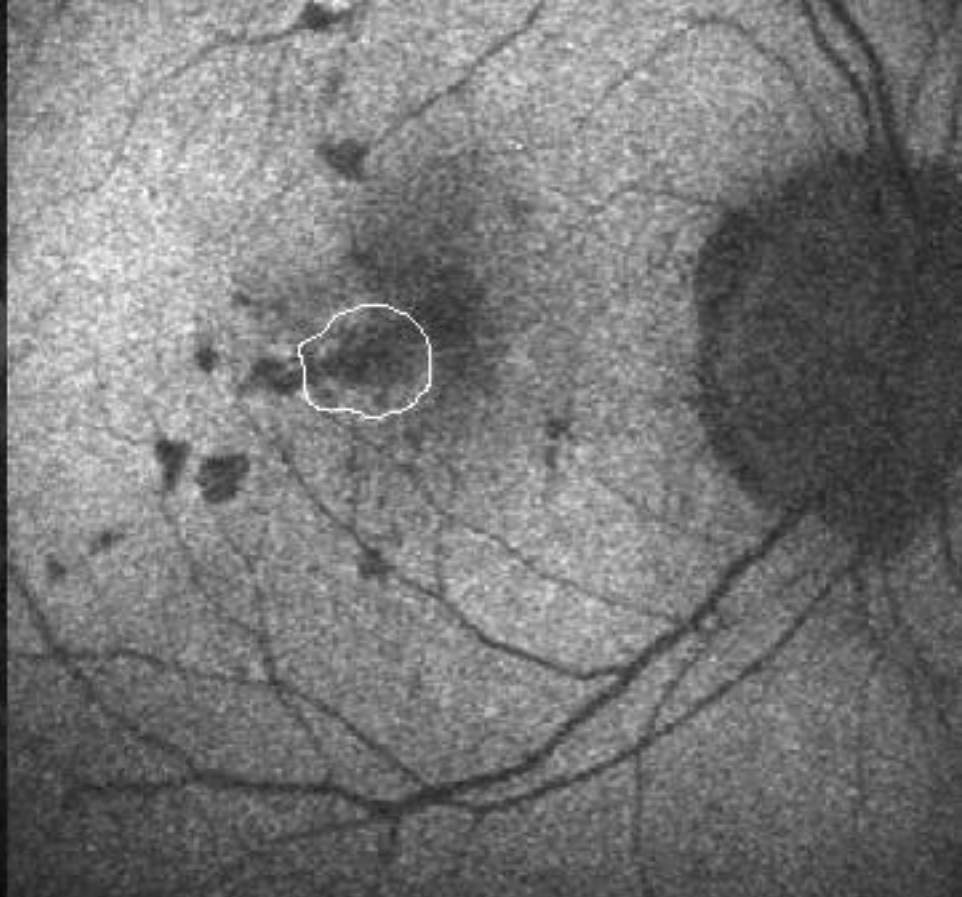
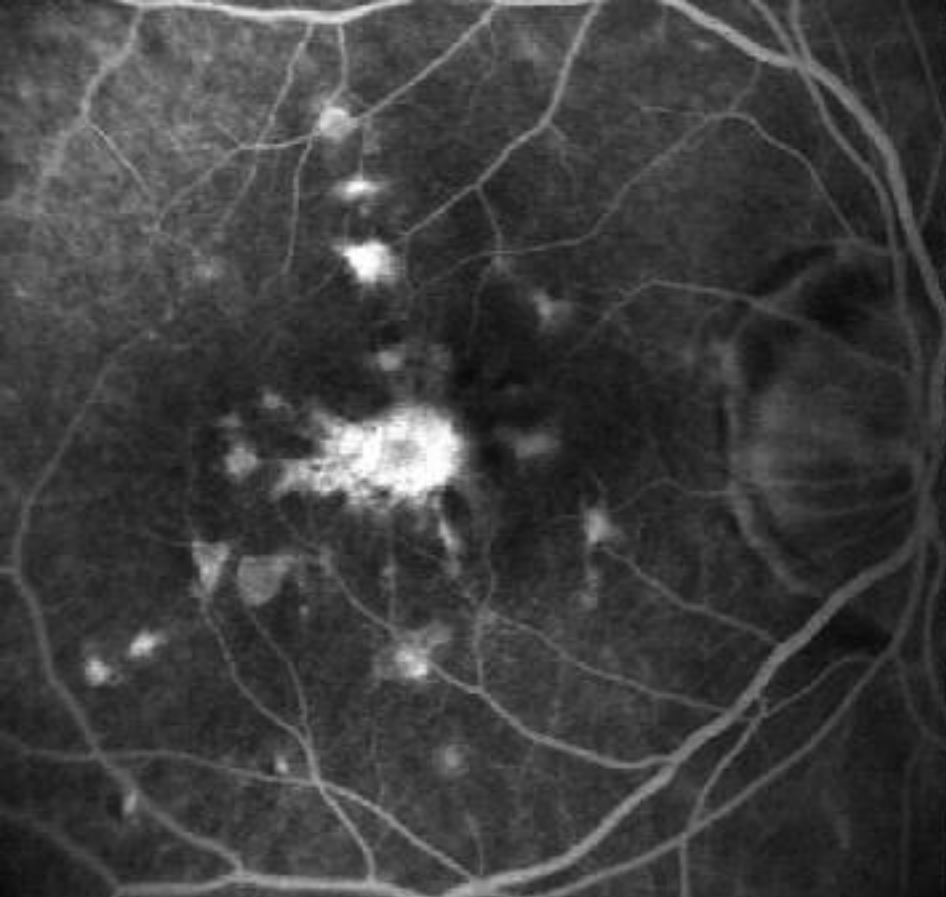
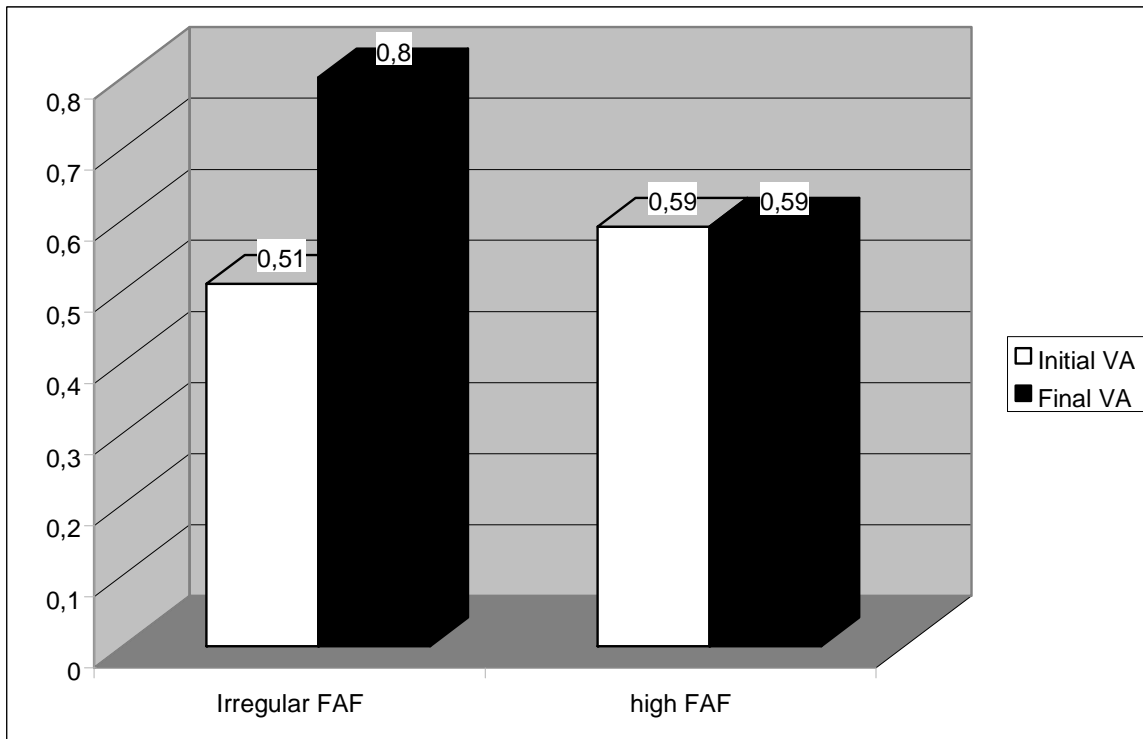


Figure 4. Mean change of visual acuity (logarithm of the minimum angle of resolution [logMAR]) in the subgroups of patients with choroidal neovascularization showing homogeneously high FAF signal and irregular FAF pattern during the 24-month follow-up.



Legend: Statistical analyses showed that there is a statistically significant difference at the end of the follow-up between BCVA values in the eyes retaining a high FAF signal and those displaying an irregular FAF signal ($p < 0.001$). Moreover, at the end of the follow-up a statistically significant deterioration of BCVA was registered in the subgroup with irregular FAF ($p = 0.015$), whereas BCVA did not reveal any statistically significant change in the subgroup retaining a high FAF signal.