



HAL
open science

Ultrasound imaging-based procedure to integrate the dynamic behaviour of the pelvis in total hip arthroplasty planning

Guillaume Dardenne, Chafiaa Hamitouche-Djabou, Eric Stindel, Christian Roux

► To cite this version:

Guillaume Dardenne, Chafiaa Hamitouche-Djabou, Eric Stindel, Christian Roux. Ultrasound imaging-based procedure to integrate the dynamic behaviour of the pelvis in total hip arthroplasty planning. 5th IEEE International Symposium on Biomedical Imaging: from Nano to Macro 2008, May 2008, Paris, France. pp.1187-1190, 10.1109/ISBI.2008.4541214 . hal-00440274

HAL Id: hal-00440274

<https://hal.science/hal-00440274v1>

Submitted on 7 Jul 2022

HAL is a multi-disciplinary open access archive for the deposit and dissemination of scientific research documents, whether they are published or not. The documents may come from teaching and research institutions in France or abroad, or from public or private research centers.

L'archive ouverte pluridisciplinaire **HAL**, est destinée au dépôt et à la diffusion de documents scientifiques de niveau recherche, publiés ou non, émanant des établissements d'enseignement et de recherche français ou étrangers, des laboratoires publics ou privés.



Distributed under a Creative Commons Attribution 4.0 International License

ULTRASOUND IMAGING-BASED PROCEDURE TO INTEGRATE THE DYNAMIC BEHAVIOR OF THE PELVIS IN TOTAL HIP ARTHROPLASTY PLANNING

G. Dardenne^{1,2,3}, C. Hamitouche^{1,2}, E. Stindel^{1,4} and C. Roux^{1,2}

¹ INSERM, U650, Brest, F-29200 France

² ENST Bretagne, GET-ENST, Brest, F-29200 France

³ Université de Bretagne Occidentale, Brest, F-29200 France

⁴ CHU Brest, Service d'Orthopédie-Traumatologie, Brest, F-29200 France

ABSTRACT

One of the main constraint in Total Hip Arthroplasty (THA) is to optimize the position of the acetabular implant in order to avoid postoperative instability. The best orientation of the cup has been studied by several authors in order to avoid it, but for most of them, they don't take into account the dynamic behavior of the pelvis during daily activities. This dynamic acts on the orientation of the acetabulum and therefore, not taking into account this behavior can lead to postoperative instability of the implant in some positions (sitting, standing or supine position). To assess the dynamic of the pelvis and the effects on the acetabular orientation, a rapid, accurate and easy new method has been developed. A functional parameter representing the pelvic flexion is first measured in different position (sitting, standing and supine position). Then, a software allowing us to assess the behavior of an acetabular implant in these positions is used. A study on twenty healthy patients has been carried out and shows that taking into account this method during THA planning might be very crucial to improve postoperative results.

Index Terms— Biomedical imaging, Surgery, Digital control, Prosthetics.

1. INTRODUCTION

The dynamic behavior of the pelvis has an important role for the orientation of the acetabulum during daily activities like the sitting, standing or supine positions. These orientations can make easier, for example, the flexion of the hip in the sitting position or the extension in the standing position. Taking into account this dynamic behavior of the pelvis for Total Hip Replacement (THR) could improve postoperative stability. Several authors have studied this dynamic behavior [1, 2, 3, 4, 5]. However, for all of them, the procedure is difficult, takes a long time and is sometimes invasive due to patient exposure to radiation (radiography or CT scan). The proposed method is based on a calibrated ultrasound (US) probe, on a navigation system (Surgetics® station) and can measure in 3D with accuracy, reproducibility rapidity and without any

radiation exposure the pelvic flexion in several positions. For our study, only three positions are used: the supine, the standing and the sitting positions. Then, the functional orientation (functional anteversion and inclination) of an acetabular implant thanks to the pelvic flexion is estimated. A study on twenty patients was realized.

2. MATERIALS AND METHODS

2.1. Experimental setup

The material used to assess the pelvic flexion and the acetabular implant orientation is composed of a navigation system (Surgetics® station) which uses stereoscopic infrared cameras: two cameras emit infrared signals and receive those sent back by retro reflective markers located on the references that are fixed on the objects we want to track. These trackers are called rigid bodies. Two kinds of trackers are used (fig. 1): reference trackers and a pointer tracker which allows us to digitize 3D targeted structures. A linear ultrasound (US)

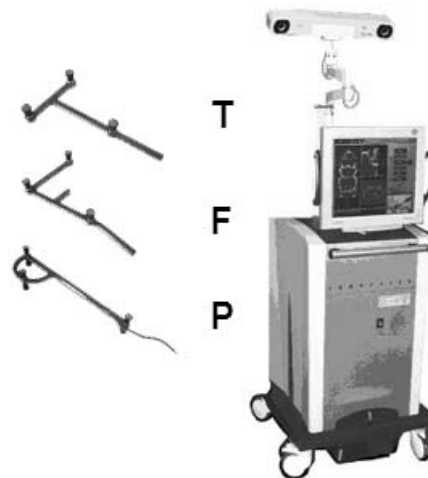


Fig. 1. Rigid bodies (left) and Navigation station (right)

probe HL7.5/40/128D and an US machine EchoBlaster[®] from Telemed[®] is integrated into the navigation system. A rigid body is attached to this US probe in order to obtain its position and orientation in real time. A calibration step has been previously performed in order to obtain the 3D localization of any point located on the US image [6]. This step was carried out thanks to a plane for the simplicity of the procedure [7, 8, 9, 10].

2.2. Obtaining the pelvic flexion

In order to optimize the position of an acetabular implant in THA, a reference plane called Anterior Pelvic Plane (APP) defined by the two anterior superior iliac spines and the pubic symphysis (fig. 2) is used in computer aided THA [11, 12]. To assess the pelvic behavior, the APP is obtained in different

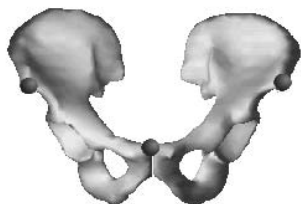


Fig. 2. Definition of the Anterior Pelvic Plane (APP)

positions and the pelvic flexion is measured between the Anterior Pelvic Plane and a reference [1]. This APP is obtained with the calibrated localized US probe. The two anterior superior iliac spines and the pubic symphysis are scanned in a given position by the localized US probe (fig. 3). The three

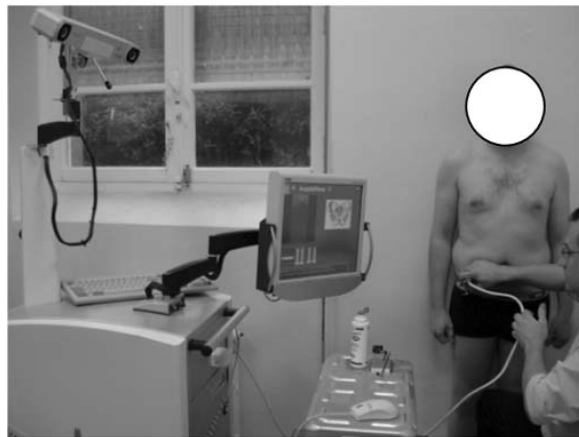


Fig. 3. Procedure allowing us to compute the pelvic flexion for the standing position

US images showing these landmarks are selected (the two iliac spines and the symphysis) and the exact positions of these landmarks on US images are localized manually, for rapidity

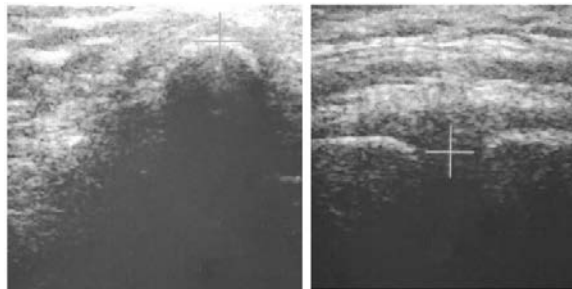


Fig. 4. US images of an iliac spine (left) and of the symphysis (right) and manual detection with a cursor.

reasons (fig. 4). The APP is then built in 3D thanks to the calibration and the pelvic flexion is computed between this plane and a reference. The reference is, in our case, an horizontal plane set in front of the navigation station when the APP is scanned (fig. 5). In the sitting and standing positions,

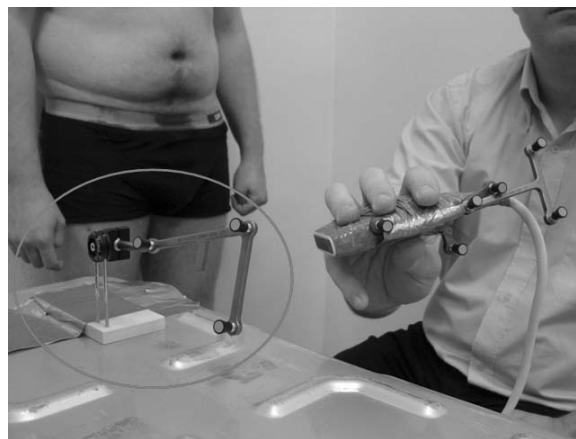


Fig. 5. The reference (surrounded with a circle) and the localized US probe

the pelvic flexion is measured between the APP and a vertical obtained with the plane reference. Concerning the supine position, the angle is directly measured between the APP and the horizontal plane reference.

2.3. Obtaining the functional acetabular orientation

In order to assess the behavior of the acetabular implant for different positions, we have developed a software allowing us to estimate the functional orientation [3] (functional anteversions and inclinations) of a cup in different daily positions of the patient (in our case: standing, sitting and supine positions)(fig. 6). To achieve this task, the pelvic flexion in these positions and the anatomical orientation (anteversion and inclination) of the acetabulum with respect to the vertical frontal plane are needed. The functional anteversion is computed in a transverse plane, parallel to the horizontal reference, between

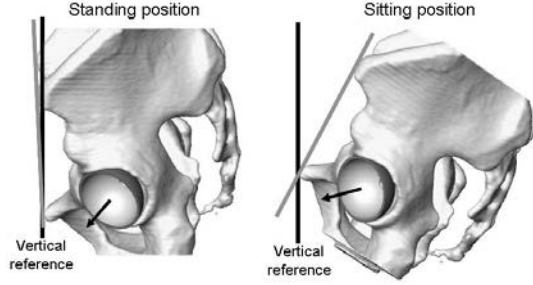


Fig. 6. Orientations of the acetabulum in the standing and sitting positions

the projected vector and the frontal vector. The functional inclination is computed between the vertical reference and the normal vector of the acetabular implant (fig. 7).

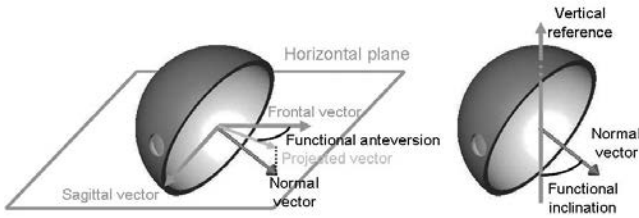


Fig. 7. Functional anteversion (left) and inclination (right).

3. RESULTS

3.1. Reliability of the pelvic flexion measurements

The accuracy of the US probe calibration was assessed and was less than 1mm [7]. The reliability of the procedure which determines the pelvic flexion was also assessed on one patient. This patient was a 24 years old man which weighted 85Kg for 1.8m. Eight measurements of the pelvic flexion were carried out on each position (Table 1).

	Supine (°)	Standing (°)	Sitting (°)
Average flexion	4.9	-4.8	-29.4
Std. Dev.	0.6	1.1	1.2
Min.	3.9	-6.2	-30.1
Max.	5.7	-3.4	-27.5
Max. Variation	1.8	2.8	3.4

Table 1. Reliability of the procedure

3.2. Pelvic flexion measurements

A study was carried out on 20 healthy men with the described procedure in the supine, standing and sitting positions. The

morphological description of the patients are given in the table 2. The results are shown in the table 3. Fifteen minutes

	Age	Height (m)	Weight (Kg)
Average	30	1.79	75
Std. Dev.	7	0.04	9
Min.	16	1.72	62
Max.	41	1.88	90

Table 2. Morphological description of the patients

	Supine (°)	Standing (°)	Sitting (°)
Average	6.8	2.4	-25.2
Std. Dev.	3.5	5.1	5.8
Min.	0.9	-4.8	-39.6
Max.	15.2	15.5	-11.2

Table 3. Pelvic flexion measured on 20 patients

were needed to obtain the pelvic flexion in the three positions for each patient.

3.3. Effects on the acetabular orientation

The procedure used to assess the behavior of an acetabular implant has been described. For our study, the implant is oriented with an anatomical inclination of 45° and an anteversion of 15° with respect to the vertical frontal plane for the 20 patients. Knowing their pelvic flexion in the three positions (sitting, supine and standing), the functional acetabular orientation is computed in these positions. Results are shown in the table 4 and 5. These results are in coherence with those

	Supine (°)	Standing (°)	Sitting (°)
Average	8.2	12.6	34.1
Std. Dev.	3.7	5.2	3.3
Min.	-0.7	-1.1	24.9
Max.	14.1	19.5	40.9

Table 4. Functional anteversion measured on 20 patients.

	Supine (°)	Standing (°)	Sitting (°)
Average	43.7	44.7	55.9
Std. Dev.	0.4	1	3.2
Min.	43.1	43.1	48.8
Max.	44.8	46.4	64.6

Table 5. Functional inclination measured on 20 patients.

of the literature [13] proving their correctness.

4. DISCUSSION

Up to now the pelvic flexion was studied using mainly radiographics [1, 2, 4]. However, the determination of the APP is difficult and most often inaccurate. The symphysis can be actually difficult to localize [3] and 2D projection can lead to inaccurate results. One other author used a digitized arm [5] but this does not take into account the depth of the intervening tissue i.e. the skin and subcutaneous tissue and can lead also to inaccurate results. Nevertheless, concerning our application, the APP is determined in 3D with accuracy, simplicity, rapidity and with no radiation exposure thanks to a procedure based on an 2.5D ultrasound probe and on a navigation station. The results observed concerning the pelvis are similar to those of the literature [1, 2]. There are significant inter-personal variations. However, for a given patient, in a given position, the pelvic flexion is unchanging and reproducible.

This different pelvic flexion following the positions modifies the functional orientation of the acetabulum. This modification can introduce postoperative instabilities. Hence, using this knowledge, a new procedure can be performed to optimize the placement of a hip prosthesis: First, the pelvic flexion is measured preoperatively with the described method. Then, the surgeon can visualize peroperatively the functional orientation of the implant following the positions and its orientation with respect to the APP. The surgeon will therefore obtain postoperative information during the surgery about the implant's behavior if we assume that the postoperative flexion is equal to the preoperative flexion as shown in [1, 2].

5. ACKNOWLEDGMENTS

This work was funded by the ANR (Agence Nationale de la Recherche) with the RNTS (Réseau National des Technologies pour la Santé), and is related to the project "Surgetique Minimale Invasive".

6. REFERENCES

- [1] S. Nishihara, N. Sugano, T. Nishii, K. Ohzono, and H. Yoshikawa, "Measurements of pelvic flexion angle using three-dimensional computed tomography," *Clin. Orthop. and Rel. Res.*, vol. 411, pp. 140–151, 2003.
- [2] A.M. Di Gioia, M.A. Hafez, B. Jaramaz, T.J. Levi-son, and J.E. Moody, "Functional pelvic orientation measured from lateral standing and sitting radiographs," *Clin. Orthop. and Rel. Res.*, vol. 453, pp. 272–276, 2006.
- [3] J.-Y. Lazennec, N. Charlot, M. Gorin, B. Roger, N. Arafati, A. Bissery, and G. Saillant, "Hip-spine relationship : a radio-anatomical study for optimization in acetabular implant cup positioning," *Surg. Radiol. Anat.*, vol. 26, pp. 136–144, 2004.
- [4] T. Ala Eddine, H. Migaud, C. Chantelot, A. Cotten, C. Fontaine, and A. Duquenooy, "Variations of pelvic anteversion in the lying and standing positions of 24 control subjects and implications for ct measurement of position of a prosthetic cup.," *Surg. Radiol. Anat.*, vol. 23, pp. 105–110, 2001.
- [5] E. Mayr, O. Kessler, A. Prassl, F. Rachbauer, M. Krismer, and M. Nogler, "The frontal pelvic plane provides a valid reference system for implantation of the acetabular cup," *Acta orthopaedica*, vol. 76, no. 6, pp. 848–853, 2005.
- [6] L. Mercier, T. Langø, F. Lindseth, and L.D. Collins, "A review of calibration techniques for freehand 3-d ultrasound systems," *Ultrasound in Med. and Biol.*, vol. 31, pp. 143–165, 2005.
- [7] G. Dardenne, J.D. Gil Cano, C. Hamitouche, E. Stindel, and C. Roux, "A new optimization approach for the calibration of an ultrasound probe using a 3d optical localizer," *IEEE Engineering in Medicine and Biology Society*, 2007, pp. 3048–3051.
- [8] R.W. Prager, R.N. Rohling, A.H. Gee, and L. Berman, "Rapid calibration for 3-d freehand ultrasound," *Ultrasound in Med. and Biol.*, vol. 24, pp. 855–869, 1998.
- [9] F. Rousseau, P. Hellier, and C. Barillot, "A fully automatic calibration procedure for freehand 3d ultrasound," *IEEE International Symposium on Biomedical Imaging*, 2002, pp. 985–988.
- [10] F. Rousseau, P. Hellier, and C. Barillot, "Robust and automatic calibration method for 3d freehand ultrasound," *MICCAI*, 2003.
- [11] G.E. Lewinnek, J.L. Lewis, R. Tarr, C.L. Clinton, and J.R. Zimmerman, "Dislocations after total hip-replacement arthroplasties," *J. Bone and Joint Surg. Am.*, vol. 60, pp. 217–220, 1978.
- [12] B. Jaramaz, A.M. Di Gioia, M. Blackwell, and C. Nikou, "Computer assisted measurement of cup placement in total hip replacement," *Clin. Orthop. and Rel. Res.*, vol. 354, pp. 70–81, 1998.
- [13] E. Chen, W. Goertz, and C.A. Lill, "Implant position calculation for acetabular cup placement considering pelvic lateral tilt and inclination," *Computer Aided Surgery*, vol. 11, no. 6, pp. 309–316, 2006.