



**HAL**  
open science

## Fully automatic segmentation of short and long axis cine cardiac MR

Maxim Fradkin, Cybèle Ciofalo, Benoît Mory, Gilion Hautvast, Marcel Breeuwer

► **To cite this version:**

Maxim Fradkin, Cybèle Ciofalo, Benoît Mory, Gilion Hautvast, Marcel Breeuwer. Fully automatic segmentation of short and long axis cine cardiac MR. Society of Cardiovascular Magnetic Resonance 12th Annual Scientific Sessions (SCMR 2009), Jan 2009, Orlando, FL, United States. <http://jcmr-online.com/content/11/S1/P226>, 10.1186/1532-429X-11-S1-P226 . hal-00439383

**HAL Id: hal-00439383**

**<https://hal.science/hal-00439383>**

Submitted on 7 Dec 2009

**HAL** is a multi-disciplinary open access archive for the deposit and dissemination of scientific research documents, whether they are published or not. The documents may come from teaching and research institutions in France or abroad, or from public or private research centers.

L'archive ouverte pluridisciplinaire **HAL**, est destinée au dépôt et à la diffusion de documents scientifiques de niveau recherche, publiés ou non, émanant des établissements d'enseignement et de recherche français ou étrangers, des laboratoires publics ou privés.

# Fully automatic segmentation of short and long axis cine cardiac MR

M. Fradkin, C. Ciofalo, B. Mory, G. Hautvast, M. Breeuwer

## Introduction

Quantitative analysis of cardiac function requires delineation of the left ventricle (LV) in cine cardiac MR (CMR). Typically, this is done using short-axis (SA) images, however, acquisition of several long-axis (LA) views has become quite common. The latter can be used for the accurate and reproducible determination of the basal SA slice, known as one of the major inter-observer variability factors in SA LV measurements [1,2]. Since manual LV delineation is very tedious and time-consuming, automatic segmentation methods, enabling to obtain reproducible LV measurements, are highly desirable. Though many publications proposed such methods, mainly for SA, only very few of them reported acceptable accuracy.

## Purpose

We propose a fully automatic method for delineation of the endo- and epicardial contours in SA and LA cine CMR images in order to provide automatic, accurate quantitative left-ventricular functional assessment.

## Methods

Our segmentation workflow consists of two steps: (1) automatic detection and delineation of the LV myocardium and valve plane in LA image(s); (2) segmentation of SA myocardial contours, using the results of step 1. For modelling the LV, we use ribbon-like template, relying on interpolating splines and defined by a very few nodes; its shape is controlled by nodes' position and the template width at each node (Fig. 1). The template is deformed using *greedy optimization* framework [3]. The optimization criterion comprises three terms: shape, contrast and region. The shape term controls the smoothness of the template as well as its resemblance to a pre-defined shape. The contrast term attracts the template boundaries to the myocardial borders in the image. Finally, the region term imposes homogeneity of the myocardium and the blood-pool regions in the underlying image. The optimization is done in coarse-to-fine manner, by relaxing the deformation type (from rigid to local) and adjusting the influence (weights) of different terms. The deformation framework is exactly the same for both LA and SA, the only difference is in the initial template positioning and deformation parameters.

The initial position of the LA template is derived from the image acquisition geometry, while that for the SA templates is obtained by projecting the LA segmentation contours on the corresponding SA slices.

We quantitatively assessed the performance of the method on a database of 35 cine CMR acquisitions (Philips Gyroscan NT Intera 1.5T, SSFP protocol, TE=1.6ms, TR=3.3ms, flip angle  $50^{\circ}$  for SA and TE=1.5-1.7ms, TR=3.0-3.4ms, flip angle  $55^{\circ}$  for LA). The SA ones included 9 to 14 slices (325 slices in total), and the LA ones 1 to 2 views (40 views in total). The assessment was made by comparing the automatically segmented contours with Gold Standard manual delineations provided by an expert.

## Results

For SA images, the mean positioning error (MPS) was  $1.3 \pm 0.5$ mm for the endocardium and  $1.5 \pm 0.8$ mm for the epicardium, for a pixel size of 1.4-1.8mm. For LA images, the MPS was  $1.3 \pm 0.4$ mm (endocardium) and  $1.1 \pm 0.4$ mm (epicardium), for a pixel size of 1.3-1.8mm. Both results are under one pixel accuracy and comparable with inter- and intra-observer variability. An excellent correlation was found between "manual" and "automatic" LV volumes ( $r=0.98$ ,  $P < 0.001$ ), with mean difference  $-2.5 \pm 7.6$  ml ( $5.5 \pm 3.9\%$ ). Note that all

results were obtained without any user interaction. An example of segmentation results for one patient (8 SA slices and 2 LA views) is shown in Fig. 2. We validated the method for the end diastolic (ED) phase only, since the segmentation of the whole cardiac cycle can be then obtained using automatic propagation of ED contours [4]. In earlier investigations, we already showed that propagation preserves the segmentation accuracy within acceptable ranges while being much faster than phase-by-phase segmentation.

### Conclusion

We presented a robust, accurate and efficient method for the fully automatic delineation of the myocardium contours in LA + SA cine CMR images, which can be used for accurate LV functional assessment.

### References

- [1] Weaver, A., et al.: *Journal of Cardiovascular Magnetic Resonance* 1, pp. 82–83 (2006)
- [2] Anderson, J., et al.:, *The Open General and Internal Medicine Journal* 1, 6–12 (2007)
- [3] Williams, D.J., Shah, M., *CVGIP: Image Understanding* 55(1), 14–26 (1992)
- [4] Hautvast et. al., *IEEE. Trans. Med. Imag.* vol. 25(11), pp. 1472-1482, 2006

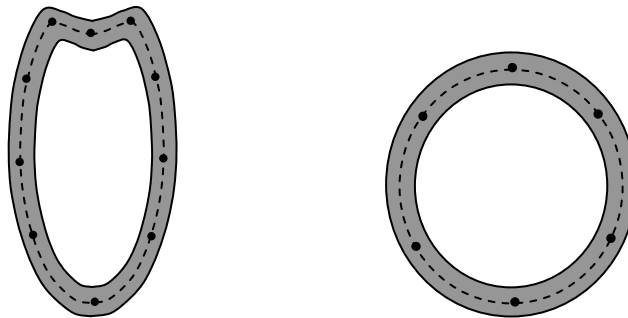


Figure 1: Deformable templates modeling LA (left) and SA (right): centerline (dashed) is defined by a few nodes, the template width (grey ribbon) may vary from node to node.

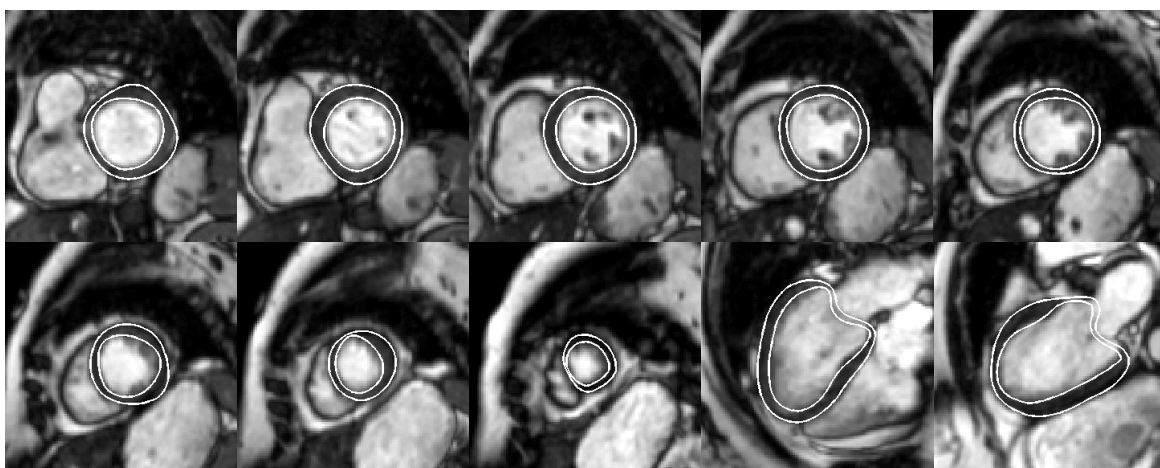


Figure 2: LV segmentation example for one patient: (from left to right, top to bottom): consecutive slices of SA volume from valve to apex; LA 4 chambers and 2 chambers.