



**HAL**  
open science

## Structural Asymmetries in the Infant Language and Sensori-Motor Networks.

Jessica Dubois, Lucie Hertz-Pannier, A. Cachia, J. F. Mangin, D. Le Bihan,  
Ghislaine Dehaene-Lambertz

► **To cite this version:**

Jessica Dubois, Lucie Hertz-Pannier, A. Cachia, J. F. Mangin, D. Le Bihan, et al.. Structural Asymmetries in the Infant Language and Sensori-Motor Networks.. *Cerebral Cortex*, 2008, 19 (2), pp.414-423. 10.1093/cercor/bhn097 . hal-00349645

**HAL Id: hal-00349645**

**<https://hal.science/hal-00349645>**

Submitted on 9 Jun 2021

**HAL** is a multi-disciplinary open access archive for the deposit and dissemination of scientific research documents, whether they are published or not. The documents may come from teaching and research institutions in France or abroad, or from public or private research centers.

L'archive ouverte pluridisciplinaire **HAL**, est destinée au dépôt et à la diffusion de documents scientifiques de niveau recherche, publiés ou non, émanant des établissements d'enseignement et de recherche français ou étrangers, des laboratoires publics ou privés.



Distributed under a Creative Commons Attribution - NonCommercial - NoDerivatives 4.0 International License

## Structural Asymmetries in the Infant Language and Sensori-Motor Networks

J. Dubois<sup>1,2</sup>, L. Hertz-Pannier<sup>2,3,4,5</sup>, A. Cachia<sup>2,6,7,8</sup>, J.F. Mangin<sup>2,9</sup>, D. Le Bihan<sup>2,10</sup> and G. Dehaene-Lambertz<sup>2,11</sup>

<sup>1</sup>CEA, UNAF, CEA/DSV/I2BM/Service Hospitalier Frédéric Joliot, 91403 Orsay, France, <sup>2</sup>IFR49, 75013 Paris, France, <sup>3</sup>CEA, Laboratoire de recherche biomédicale, CEA/SAC/DSV/I2BM/NeuroSpin, 91191 Gif-sur-Yvette, France, <sup>4</sup>AP-HP, Radiologie Pédiatrique, Hôpital Necker-Enfants Malades, 75013 Paris, France, <sup>5</sup>INSERM, U663, 75013 Paris, France; Université Paris, 75013 Paris, France, <sup>6</sup>INSERM-CEA, U797, CEA/DSV/I2BM/Service Hospitalier Frédéric Joliot, 91403 Orsay, France, <sup>7</sup>Université Paris-Sud, 91403 Orsay, France, <sup>8</sup>Université Paris Descartes, 75013 Paris, France, <sup>9</sup>CEA, Laboratoire de neuroimagerie assistée par ordinateur, CEA/SAC/DSV/I2BM/NeuroSpin, 91191 Gif-sur-Yvette, France, <sup>10</sup>CEA/SAC/DSV/I2BM/NeuroSpin, 91191 Gif-sur-Yvette, France and <sup>11</sup>INSERM, U562, CEA/SAC/DSV/I2BM/NeuroSpin, 91191 Gif-sur-Yvette, France

**Both language capacity and strongly lateralized hand preference are among the most intriguing particularities of the human species. They are associated in the adult brain with functional and anatomical hemispheric asymmetries in the speech perception-production network and in the sensori-motor system. Only studies in early life can help us to understand how such asymmetries arise during brain development, and to which point structural left-right differences are the source or the consequence of functional lateralization. In this study, we aimed to provide new in vivo structural markers of hemispheric asymmetries in infants from 1 to 4 months of age, with diffusion tensor imaging. We used 3 complementary analysis methods based on local diffusion indices and spatial localizations of tracts. After a prospective approach over the whole brain, we demonstrated early leftward asymmetries in the arcuate fasciculus and in the cortico-spinal tract. These results suggest that the early macroscopic geometry, microscopic organization, and maturation of these white matter bundles are related to the development of later functional lateralization.**

**Keywords:** development, DTI, infant, language, laterality, maturation, motor, white matter

### Introduction

Among the most intriguing particularities of humans are their language capacity and strongly lateralized hand preference. These behavioral features are sustained by functional hemispheric asymmetries in the speech perception-production network and in the sensori-motor system. They are also associated in the adult brain with structural differences between the left and right hemispheres (for review Toga and Thompson 2003). However such studies cannot disentangle whether structural differences arise from functional asymmetries or whether they are biologically rooted tendencies that lead to specific behavioral features in the human species. Only developmental studies can help us to decipher the temporal relationship between structural and functional asymmetries, by taking advantage of the progressive development during childhood of lateralized functions such as language and handedness. Early infancy is thus an ideally suited time window to search for brain structural asymmetries that would precede the later behavioral expression of the corresponding lateralized functions.

Infants initially use both hands indifferently (Corbetta and Thelen 1999; Ronnqvist and Domellof 2006), then preference

for one hand becomes clear generally from 18 months of age on (Fagard and Marks 2000) and is more and more pronounced during the following years (Ingram 1975a). Lateralization of linguistic capacities is behaviorally assessed with dichotic listening. When different syllables are simultaneously presented to both ears, adults are better able to report the syllables presented in the right ear, which is interpreted as reflecting the left hemisphere advantage to process speech (Kimura 1967). As for handedness, asymmetry becomes more obvious with age and a right-ear advantage is robustly observed in children after 3 years of age (Ingram 1975b). Earlier behavioral signs of lateralization have been looked for in both domains. For example, Ottaviano et al. (1989) observed a right-hand preference in spontaneous activity of full-term newborns, and Bertoncini et al. (1989) reported a right-ear advantage for speech stimuli in neonates. However, these studies are sparse and their results were not always replicated (Best 1988). This can be due to difficulties to obtain behavioral evidence at a young age or to an initial fragile lateralization. The few existing brain imaging studies also suggest some early functional asymmetry (Dehaene-Lambertz, Hertz-Pannier, Dubois, 2006). The amplitude of event-related potentials to auditory stimuli is larger over the left hemisphere than the right in 2-month-old infants (Dehaene-Lambertz 2000), and the hemodynamic response to sentences of the native language is significantly asymmetric in the posterior superior temporal region in neonates (Peña et al. 2003) and 3 month olds (Dehaene-Lambertz et al. 2002; Dehaene-Lambertz, Hertz-Pannier, Dubois, Meriaux, et al. 2006). Thus, although the asymmetry toward the left hemisphere for linguistic and motor tasks becomes more pronounced during childhood, some behavioral and brain imaging studies point out toward early functional differences between the left and right hemispheres.

Are these early functional left-right differences sustained by corresponding structural differences? Actually, macroscopic left-right differences are present from the fetal life on. Post-mortem studies have shown that some cortical gyri, such as the superior frontal gyrus, the superior temporal gyrus and Heschl's gyrus appear in the right hemisphere 1 or 2 weeks earlier than in the left (Chi et al. 1977), and a recent neuroimaging study in preterm newborns has revealed a right temporal sulcus larger than the left (Dubois et al. 2007). By contrast, the *planum temporale* and Heschl's gyrus are larger on the left side in fetuses and infants (Witelson and Pallie 1973; Chi et al. 1977; Galaburda and

Geschwind 1981), as also shown in adults (Hochberg and Le May 1975; Rademacher et al. 1993; Penhune et al. 1996; Rademacher, Morosan, et al. 2001). In neonates, gray and white matter volumes are larger in the left hemisphere, contrarily to adults (Gilmore et al. 2007), and anatomical and physiological asymmetries continue to evolve during childhood and adolescence (Chiron et al. 1997; Paus et al. 1999; Sowell et al. 2002).

To progress beyond gross regional differences into the early asymmetrical local organization of the linguistic and motor networks, we aimed in this study to identify new structural markers of brain asymmetry in infants. Diffusion tensor imaging (DTI) (see for a review Le Bihan et al. 2001) is currently the gold standard to explore white matter organization and maturation in vivo in newborns and children (see for reviews Beaulieu 2002; Neil et al. 2002). Even in weakly myelinated brains, the main fiber tracts are clearly identifiable (Dubois et al. 2006), and DTI indices have been shown to be differentially affected by bundles maturation with age (Table 1; Dubois et al. 2008). A better organization and stronger coherence of fibers in parallel bundles leads to higher fractional anisotropy (FA) and longitudinal diffusivity ( $\lambda_{//}$ ) and to a lower transverse diffusivity ( $\lambda_{\perp}$ ) without change in mean diffusivity ( $\langle D \rangle$ ). Myelination by itself also affects these indices. During “premyelination” stages, the isotropic proliferation of cells, prolongations, intracellular compartments and membranes uniformly reduces all diffusivity indices ( $\langle D \rangle$ ,  $\lambda_{\perp}$ ,  $\lambda_{//}$ ) with no effect on anisotropy. Then, subsequent “true” myelination of fiber fascicles (corresponding to the ensheathment of oligodendroglial processes around the axons) increases FA, associated with lower  $\langle D \rangle$  and  $\lambda_{\perp}$ , and without difference in  $\lambda_{//}$ .

In adults, DTI has highlighted numerous interhemispheric differences (Cao et al. 2003; Park et al. 2004; Fabiano et al. 2005; Gong et al. 2005). Diffusion in both the left arcuate fasciculus and the precentral gyrus contra-lateral to the dominant hand appeared more anisotropic than their counterparts (Buchel et al. 2004), which may imply a higher coherence in tissue organization of these bundles. The auditory-language network delineated by 3D tractography (see for a review Mori and van Zijl 2002) is also asymmetrical (Parker et al. 2005; Powell et al. 2006). We thus evaluated in this study whether structural asymmetries could be detected by DTI in the infant language-related and sensori-motor networks. Left-right differences were assessed in healthy infants from 1 to 4 months of age, with 3 different analysis methods based on local diffusion indices and spatial localization of tracts. We demonstrated early asymmetries of the arcuate fasciculus and the cortico-spinal tract which suggest that the macro- and microscopic structural organization and maturation of these networks underlie the setting up of brain functional lateralization.

## Materials and Methods

### Subjects

Twenty-three healthy full-term infants, born between January 2004 and July 2005 (mean maturational age, that is, chronological age corrected

for the gestational age at birth:  $10.3 \pm 3.8$  weeks, range: 3.9–18.4 weeks; 12 boys, 11 girls), were included in this study after their parents gave written informed consent. Recruitment was based on the civil lists of births in the south districts of Paris: parents of newborns were notified by mail about the study, and, if interested, further details were explained to them by phone. No sedation was used and the infants were spontaneously asleep during magnetic resonance imaging (MRI). Particular care was taken to minimize the noise exposure, by using customized headphones and by covering the magnet bore with a noise protection foam. The study was approved by the regional ethical committee for biomedical research.

### Data Acquisition

DTI acquisition has been reported in a previous paper (Dubois et al. 2006). Briefly, the acquisition was performed on a 1.5T MRI system (Signa LX, GEMS, Milwaukee, WI), using a birdcage head coil and a diffusion weighted-spin echo-echo planar imaging technique ( $b = 700$  s/mm<sup>2</sup>, time echo/time repetition = 89.6 ms/13.8 s, 14–30 encoding orientations diffusion gradient to keep a similar signal-to-noise ratio across subjects, acquisition time = 3 min 40 s to 7 min 20 s). Thirty axial slices covering the whole brain were imaged, with a spatial resolution interpolated to  $0.94 \times 0.94 \times 2.5$  mm<sup>3</sup> at reconstruction (field of view =  $24 \times 24$  cm<sup>2</sup>, matrix =  $256 \times 256$ ). Conventional MR images were acquired with a  $T_2$ -weighted fast spin-echo sequence which yields the best anatomical contrast between gray and white matter in the infants’ brain (spatial resolution  $1.04 \times 1.04 \times 2$  mm<sup>3</sup>).

### Data Postprocessing

Data processing was performed using BrainVISA software for DTI data preparation and white matter tract reconstruction (Cointepas et al. 2003, <http://brainvisa.info/>), and Statistical Parameter Mapping software for image normalization and voxel-based analyses (SPM5, FIL, <http://www.fil.ion.ucl.ac.uk/spm/>).

### Image Preparation

The DW images were corrected for the geometric distortions due to eddy currents (Mangin et al. 2002), and the diffusion tensor was estimated on a voxel-by-voxel basis. Maps of FA and mean ( $\langle D \rangle$ ), transverse ( $\lambda_{\perp}$ ), and longitudinal ( $\lambda_{//}$ ) diffusivities were calculated (Pierpaoli and Basser 1996).

### Creation of FA Template and Image Normalization

To normalize all DTI scalar maps into a common space, we first created, with an optimized procedure, a FA template which was specific to the infants group. Individual  $T_2$ -weighted conventional images were nonlinearly normalized to an anatomical infant template (Dehaene-Lambertz et al. 2002, <http://www.unicog.org/main/pages.php?page=Infants>). The transformation parameters were applied to each corresponding coregistered FA map, and these normalized FA maps were averaged over the group to create a native FA template (spatial resolution:  $2 \times 2 \times 2$  mm<sup>3</sup>), which retains existing left-right differences. To create a FA template that includes these differences, all native FA maps ( $N$ ) and corresponding FA maps flipped on the left-right axis ( $F$ ) were subsequently nonlinearly normalized to the native template, and the resulting maps were averaged. For the analyses, both native and flipped individual FA maps were normalized to this final FA template, and the resulting transformations were applied to diffusivity maps ( $\langle D \rangle$ ,  $\lambda_{\perp}$ ,  $\lambda_{//}$ ) in each infant.

### Bundles Tractography

The arcuate fasciculus and the cortico-spinal tract were reconstructed in each infant by tractography using a nonlinear algorithm based on the regularization of a particle trajectory (Perrin et al. 2005; Dubois et al. 2008). A mask to exclude voxels belonging to the cortex or cortico-spinal fluid was defined (FA smaller than 0.15 or  $\langle D \rangle$  higher than  $2.10^{-3}$  mm<sup>2</sup>/s), and different segments of the tracts were identified (Dubois et al. 2006) by using regions of interest (detailed below) that were both tractography seeds, regions of selection and regions of split.

The study of the arcuate fasciculus required some methodological adaptations because of its particularly low maturation in the infant

**Table 1**

Model of relationships between asymmetries of white matter microstructure and diffusion indices during brain development (also see Dubois et al. 2008): side A is compared with side B

A-B asymmetries	FA	$\langle D \rangle$	$\lambda_{\perp}$	$\lambda_{//}$
Higher organization	$FA_A > FA_B$	—	$\lambda_{\perp A} < \lambda_{\perp B}$	$\lambda_{//A} > \lambda_{//B}$
Advanced “pre”-myelination	—	$\langle D \rangle_A < \langle D \rangle_B$	$\lambda_{\perp A} < \lambda_{\perp B}$	$\lambda_{//A} < \lambda_{//B}$
Advanced “true” myelination	$FA_A > FA_B$	$\langle D \rangle_A < \langle D \rangle_B$	$\lambda_{\perp A} < \lambda_{\perp B}$	—



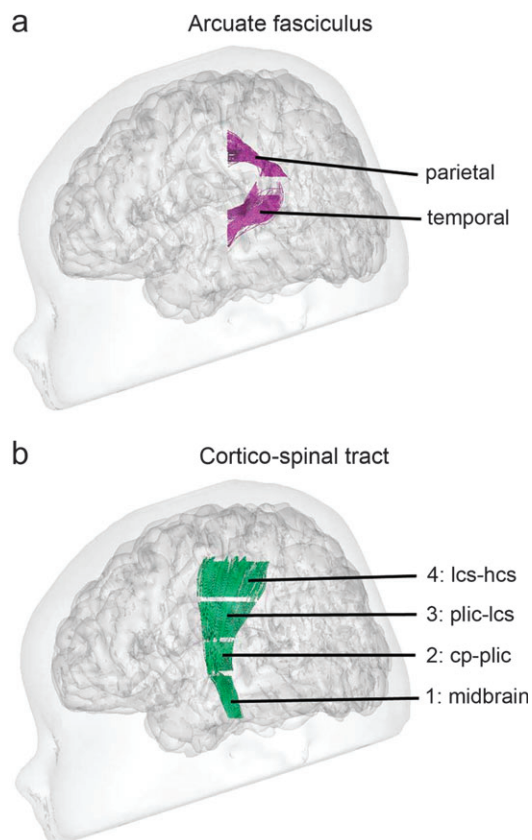
brain. First, the fasciculus could not be tracked continuously between the fronto-parietal and temporal lobes in all infants, because of the sharp curvature and low anisotropy of the parieto-temporal loop fibers at these ages. Such a limitation has been described in children from 6 to 17 years old (Eluvathingal et al. 2007). Second, it was not possible to reconstruct consistently the frontal portion of the tract, because of insufficient diffusion anisotropy in this age range (Zhang et al. 2007). Hence, 3 tractography seeds were placed in the parietal and temporal lobes, and at the level of the parieto-temporal loop, which resulted in 2 segments (parietal and temporal, Fig. 1a).

By contrast, the cortico-spinal tract was isolated as a whole, using tractography seeds localized at the level of the cerebral peduncles, the posterior limb of the internal capsule, and the low and high centrum semiovale. Four segments were studied (Fig. 1b): segment 1 in the midbrain below the cerebral peduncles, segment 2 between the cerebral peduncles and the posterior limb of the internal capsule, segment 3 between the posterior limb of the internal capsule and the low centrum semiovale, and segment 4 between the low and the high centrum semiovale.

Individual binary masks of the arcuate fasciculus and cortico-spinal tract were generated by considering all voxels crossed by tracked fibers, and masks were flipped on the left-right axis. Then both the native and flipped masks were normalized using the transformations created for the corresponding FA maps.

### Study of Interhemispheric Asymmetries

As a first approach, we used a whole brain “voxel-based” analysis of FA index to examine where structural asymmetries, if any, were present (Analysis A). Similar analyses conducted for diffusivities ( $\langle D \rangle$ ,  $\lambda_{\perp}$ , and  $\lambda_{\parallel}$ ) were performed but are not presented, as equivalent results were



**Figure 1.** Localization of the studied fascicles segments. Bundles reconstructed by tractography, showing the parietal and temporal portions of the arcuate fasciculus (a) and the 4 segments of the cortico-spinal tract (b), are superimposed to the cortical surface and head of a 15.7-week-old infant. Abbreviations: cp: cerebral peduncles, plic: posterior limb of the internal capsule, lcs/hcs: low/high centrum semiovale.

obtained for FA and  $\lambda_{\parallel}$ , and no asymmetry was found for  $\langle D \rangle$  and  $\lambda_{\perp}$ . As asymmetries observed with Analysis A could be related to genuine left-right differences in tracts microstructure, but also to residual differences in the localization or geometry of the tracts, still present despite normalization, we conducted 2 complementary analyses focused on the arcuate fasciculus and cortico-spinal tract isolated by tractography: we first compared their localization and geometry on both sides using a voxel-based analysis of the reconstructed segments (Analysis B), and then analyzed the left-right differences of diffusion indices (FA,  $\langle D \rangle$ ,  $\lambda_{\perp}$ ,  $\lambda_{\parallel}$ ) as measured within the tracts (Analysis C).

### Whole Brain Voxel-Based Analysis of FA Asymmetry (Analysis A)

An asymmetry map between the normalized native and flipped FA maps  $(N - F)/(N + F)$  was calculated for each infant and smoothed with a 5-mm Gaussian filter. The filter size was adapted according to the small size of cerebral structures in infants and to the image spatial resolution. Interhemispheric asymmetries were evaluated by testing the nullity of these maps over the group with a one-tailed paired  $t$ -test on a voxel-by-voxel basis. The analysis mask (volume: 156 513 voxels) excluded voxels with low FA ( $<0.15$ ) or high  $\langle D \rangle$  ( $>2.10^{-3}$  mm<sup>2</sup>/s). Statistical thresholds were considered at the voxel level at  $P_{\text{FDR-corr}} < 0.05$  after correction for multiple comparisons with “false discovery rate” (FDR) approach, and at the cluster level at  $P_{\text{corr}} < 0.001$  (clusters of at least 55 voxels).

### Voxel-Based Analysis of the Asymmetry of Tracts Localization and Geometry (Analysis B)

To study the localization and geometry of the arcuate fasciculus and the cortico-spinal tract on both sides across infants, we performed a voxel-based analysis on the corresponding normalized tract segments. This isolates the tracts from surrounding tissue and avoids partial volume effects. An asymmetry map between the normalized native and flipped tract maps  $(N - F)/(N + F)$  was computed in each infant for all segments, and we tested the nullity of these maps over the infants group (one-tailed paired  $t$ -test, statistical thresholds: at the voxel level after FDR correction  $P_{\text{FDR-corr}} < 0.05$ , at the cluster level  $P_{\text{FDR-corr}} < 0.001$ , clusters of at least 10 voxels). As the analysis mask was the sum of all individual tract masks, its volume depended on the tract segment (arcuate fasciculus: 2472 and 1317 voxels for temporal and parietal segments respectively; cortico-spinal tract: 526, 754, 648, and 1336 voxels for segment 1, 2, 3, and 4, respectively).

To provide a visual outline of the tracts localization and geometry over the group, we calculated their probability maps, which correspond to the average of the normalized tract masks over the infants group (Ciccarelli et al. 2003). The probability  $P$  in each voxel thus means that this voxel belongs to the tract in (total number of infants)  $\times P$  infants (Burgel et al. 2006). Furthermore, left-right differences in the tracts volumes were evaluated over the group through asymmetry ratios  $(L - R)/(L + R)$  (one-tailed paired  $t$ -test,  $P < 0.05$  after correction for multiple comparisons with FDR approach).

### Analysis of Diffusion Indices Asymmetry within the Tracts (Analysis C)

To analyze differences in the tracts microstructure, we computed the diffusion indices (FA,  $\langle D \rangle$ ,  $\lambda_{\perp}$ ,  $\lambda_{\parallel}$ ) in each infant tract segment (Glenn et al. 2003; Dubois et al. 2006), and an asymmetry ratio  $(L - R)/(L + R)$  was computed for each index (FA,  $\langle D \rangle$ ,  $\lambda_{\perp}$ ,  $\lambda_{\parallel}$ ). We tested the nullity of this ratio over the infants group using a one-tailed paired  $t$ -test ( $P < 0.05$  after correction for multiple comparisons with FDR approach).

### Age-Related Effects

Because the brain is rapidly growing and diffusion indices are dramatically changing during infancy (Dubois et al. 2006), we also studied whether asymmetries between the left and the right hemispheres evolved with age. Using analyses similar to above for asymmetry maps and ratios, we computed age-related linear regressions for all left-right differences (difference maps between normalized native and flipped maps  $(N - F)$  for Analyses A and B, or differences between left and right volumes or diffusion indices  $(L - R)$  for Analysis C). Contrarily to asymmetry maps and ratios, such differences are not normalized for interindividual variability, related notably to age. As no significant effect

of age was observed in any case, these analyses are not further considered.

## Results

The voxel-based analysis of FA asymmetry over the whole brain (Analysis A) revealed 7 significantly asymmetrical clusters (Table 2, Fig. 2). We will consider in turn the arcuate fasciculus, the cortico-spinal tract, and finally the other clusters.

### Asymmetry of the Arcuate Fasciculus

On Analysis A, the highest  $t$  value was observed in the temporal white matter where FA was higher on the left side (Fig. 2*a*, cluster no. 1 of 309 voxels,  $t = 17.12/P_{\text{FDR-corr}} < 0.001$ ). Another cluster, more dorsal and posterior, was also asymmetrical but with higher FA on the right side (Fig. 2*b*, cluster no. 3 of 133 voxels,  $t = 8.26/P_{\text{FDR-corr}} < 0.001$ ). The superposition of these clusters over the arcuate fasciculus probability map showed that the first cluster was located inside the tract, whereas the second one was located on its superior aspect (Fig. 2*a,b*). Such close localizations with effects of opposite sign suggested that the left and right temporal segments of the arcuate fasciculus might not be perfectly realigned by the normalization process.

Indeed, the superposition of the left and right probability maps visually showed that the localization and geometry of the temporal segment of the arcuate fasciculus was different between both hemispheres (Fig. 3*a*). The left fasciculus was more posterior and significantly larger (left/right volumes:  $1310 \pm 367 \text{ mm}^3/822 \pm 372 \text{ mm}^3$ ;  $t = 4.75/P < 0.001$ ). Moreover, the presence of 2 branches in the temporal segment on axial views was more frequent on the left side than on the right (15/23 and 5/23, respectively).

This asymmetry in localization and geometry of the temporal segment was subsequently confirmed by the voxel-based analysis conducted on the bundle masks (Analysis B), which showed an extended left fasciculus in comparison with the right (Fig. 3*b*; cluster of 79 voxels,  $t = 6.42/P_{\text{FDR-corr}} = 0.002$ ). This cluster had the same localization than cluster 1 in Analysis A (Fig. 2*a*), but was smaller. Conversely, no left-right difference was observed for the parietal part of the arcuate fasciculus.

Finally, the analysis of diffusion indices over the arcuate fasciculus segments (Analysis C, Table 3, Fig. 4*a*) showed a higher FA in the left parietal segment, which suggests either a higher organization of the fibers or an advanced “true” myelination (Table 1). In the left temporal segment,  $\langle D \rangle$ , and  $\lambda_{\parallel}$  were higher, relying probably on a delay in the “pre”-myelination stages on that side (Table 1).

### Asymmetry of the Cortico-Spinal Tract

The voxel-based analysis of FA asymmetry (Analysis A) also revealed that the left cortico-spinal tract between the cerebral peduncles and the posterior limb of the internal capsule, had a higher anisotropy than its right counterpart (Fig. 2*c*, cluster no. 7 of 69 voxels,  $t = 5.21/P_{\text{FDR-corr}} = 0.008$ ). This cluster was precisely located in the fascicle reconstructed by tractography (Fig. 2*c*).

The voxel-based analysis on tract localization (Analysis B) did not detect asymmetry for any segment of the cortico-spinal tract, suggesting that these tracts have the same geometry in both hemispheres.

The analysis of diffusion indices (Analysis C) in the 4 segments uncovered several asymmetries (Table 3, Fig. 4*b*), which can reflect asymmetries in the tract organization and maturation (Table 1). In the midbrain segment, FA was higher and  $\lambda_{\perp}$  was lower in the left hemisphere, which suggests either a higher organization of the fibers or an advanced “true” myelination. In the left segment between the cerebral peduncles and the posterior limb of the internal capsule, FA was higher and  $\langle D \rangle$  and  $\lambda_{\perp}$  were lower, which is likely to rely on an advanced “true” myelination. In the following segment, below the low centrum semiovale,  $\langle D \rangle$  was lower on the left, as the result of an advance in the first stages of myelination or in the “true” myelination. No asymmetry was observed in the most superior segment, between the low and high centrum semiovale. To sum up, a more advanced maturation stage was observed in the left cortico-spinal tract between the midbrain and the low part of centrum semiovale.

### Other Asymmetries in the Developing Brain

The voxel-based analysis of FA (Analysis A) showed 4 other significant asymmetrical regions (Fig. 2*d*). The clusters with higher FA were located in the left deep frontal white matter (cluster no. 2 of 405 voxels,  $t = 9.22/P_{\text{FDR-corr}} < 0.001$ ), the left anterior part of the calcarine fissure (cluster no. 4 of 67 voxels,  $t = 6.83/P_{\text{FDR-corr}} = 0.001$ ), the left thalamus ventral or anterior ventral nucleus (cluster no. 5 of 58 voxels,  $t = 6.47/P_{\text{FDR-corr}} = 0.001$ ) and the right anterior insula (cluster no. 6 of 78 voxels,  $t = 5.74/P_{\text{FDR-corr}} = 0.004$ ).

## Discussion

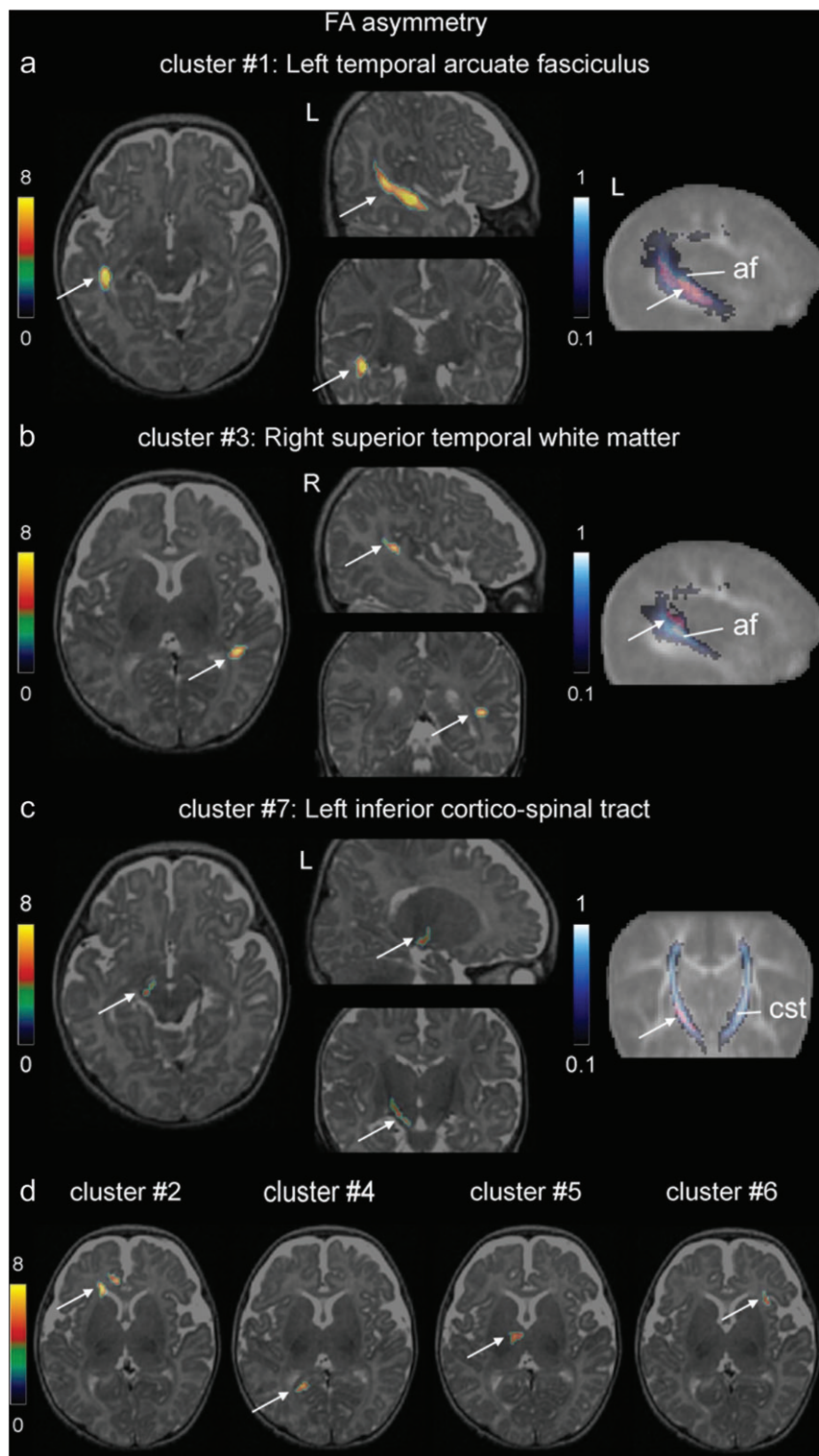
In this in vivo DTI study of the developing brain, we highlighted interhemispheric structural asymmetries in different cerebral areas, but most notably in 2 white matter networks that sustain asymmetrical functions in human adults, the language-related and sensori-motor networks. Both a global comparison using

**Table 2**

Whole brain voxel-based analysis of FA asymmetry (Analysis A)

Cluster	Hemispheric side	Localization	Cluster level: no. of voxels	Voxel level: $t$ value ( $P_{\text{FDR-corr}}$ )
1	L	Temporal arcuate fasciculus	309	17.12 (<0.001)
2	L	Frontal white matter	405	9.22 (<0.001)
3	R	Superior temporal white matter	133	8.26 (<0.001)
4	L	Anterior calcarine fissure	67	6.83 (0.001)
5	L	Anterior thalamus	58	6.47 (0.001)
6	R	Anterior insula	78	5.74 (0.004)
7	L	Inferior cortico-spinal tract	69	5.21 (0.008)

Note: The statistically asymmetrical clusters ( $P_{\text{FDR-corr}} < 0.05$  at the voxel level,  $P_{\text{corr}} < 0.001$  at the cluster-level, clusters of at least 55 voxels), which have a higher FA in the left (L) or right (R, italic font) hemisphere, are outlined in order of significance, with their localization, number of voxels,  $t$  value at local maxima, with  $P$  value in parenthesis after correction for multiple comparisons with FDR approach.

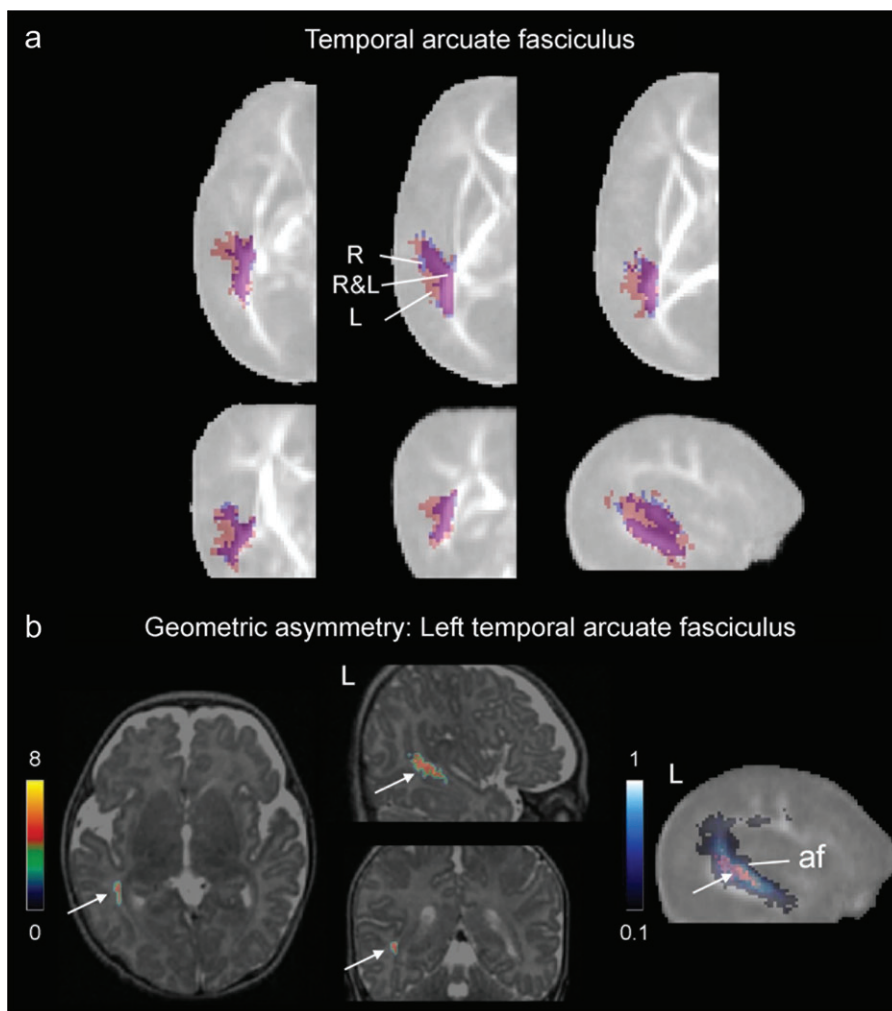


**Figure 2.** Whole brain voxel-based analysis of FA asymmetry (Analysis A). Asymmetrical regions with higher FA (Table 2) are shown at the level of the left temporal arcuate fasciculus (a), right superior temporal white matter (b), left inferior cortico-spinal tract (c) and the other clusters (d). For each localization in (a–c), the 3 left images show the statistically asymmetrical clusters superimposed to the anatomical images of a 8.6-week-old infant (the color bar represents the  $t$  value from 0 to 8), and, for a better delineation, the right image shows the cluster of interest (in red) superimposed to the FA template and to the corresponding bundle probability map (arcuate fasciculus [af], or cortico-spinal tract [cst], in blue scale from 0.1 to 1). (d) Clusters are superimposed to axial anatomical images.

voxel-based analysis of FA and specific comparisons of localization and of DTI indices on the individualized tracts revealed left–right differences in these 2 networks already

during the first postnatal weeks, with no evolution in the amplitude of these differences during the considered time period (3.9–18.4 weeks).





**Figure 3.** Geometric asymmetry of the temporal arcuate fasciculus (Analysis B). (a) The masks of bundle probability maps of the left (pink) and flipped-right (blue) temporal segments of the arcuate fasciculus are superimposed to the FA template. Most left and right regions overlap (purple), but the left fasciculus is larger than the right. (b) For the voxel-based analysis of tract localization asymmetry, the 3 left images show the region of the temporal arcuate fasciculus with significant leftward asymmetry (the color bar represents the  $t$  value from 0 to 8). For a better delineation, the right image shows this significant cluster (in red) superimposed to the FA template and to the arcuate fasciculus (af) probability map (in blue scale from 0.1 to 1).

**Table 3**

Analysis of diffusion indices asymmetries within the tracts (Analysis C)

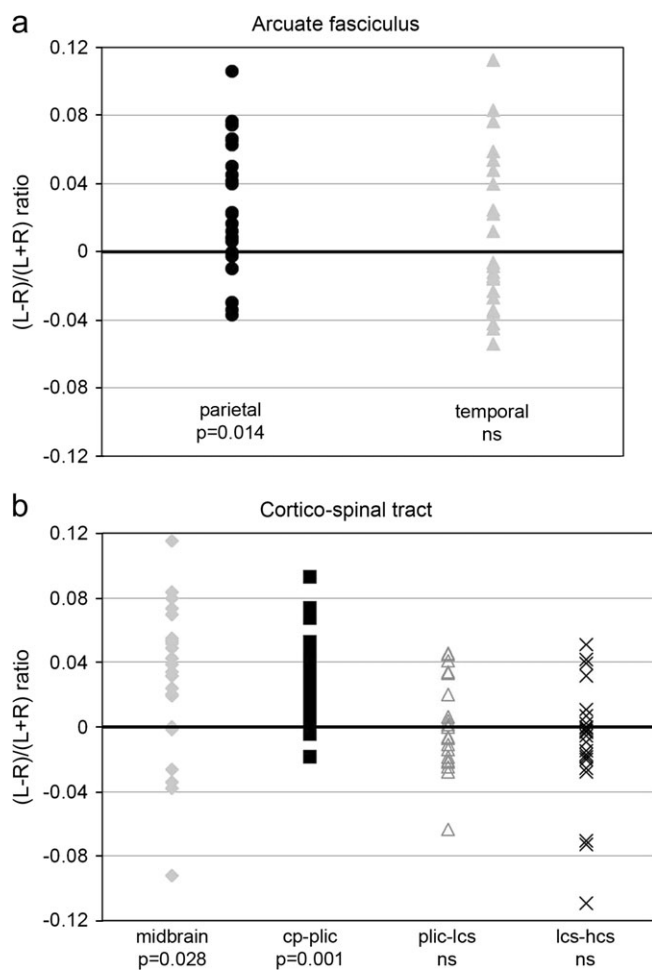
Tract segment	Diffusion indices asymmetries			
	FA	$\langle D \rangle$	$\lambda_{\perp}$	$\lambda_{\parallel}$
		Arcuate fasciculus		
Parietal segment	L, $t = 3.35$ , $P = 0.014$	R, $t = -1.16$ , ns	R, $t = -1.37$ , ns	R, $t = -0.35$ , ns
Temporal segment	L, $t = 1.09$ , ns	L, $t = 2.59$ , $P = 0.045$	L, $t = 0.93$ , ns	L, $t = 3.28$ , $P = 0.014$
		Cortico-spinal tract		
Segment 1 (midbrain)	L, $t = 2.91$ , $P = 0.028$	R, $t = -0.25$ , ns	R, $t = -2.66$ , $P = 0.043$	L, $t = 2.26$ , ns
Segment 2 (cp-plc)	L, $t = 5.33$ , $P = 0.001$	R, $t = -3.29$ , $P = 0.014$	R, $t = -4.96$ , $P = 0.001$	L, $t = 1.54$ , ns
Segment 3 (plc-lcs)	L, $t = 0.28$ , ns	R, $t = -3.41$ , $P = 0.014$	R, $t = -1.18$ , ns	R, $t = -2.16$ , ns
Segment 4 (lcs-hcs)	R, $t = -0.94$ , ns	L, $t = 0.18$ , ns	L, $t = 0.82$ , ns	R, $t = -0.90$ , ns

Note: The statistical significance ( $t$  and  $P$  values) of asymmetries for the 4 diffusion indices quantified on average over the fascicle segments (arcuate fasciculus and cortico-spinal tract) is outlined (at the level of  $P < 0.05$  after FDR correction, ns: not significant). A positive  $t$  value corresponds to a higher index in the left hemisphere, and a negative one to a higher index in the right hemisphere (italic font). Abbreviations: cp: cerebral peduncles, plc: posterior limb of the internal capsule, lcs/hcs: low/high centrum semiovale.

### Arcuate Fasciculus Asymmetry and Development of the Language-Related Network

All analyses on arcuate fasciculus localization, geometry, and diffusion indices revealed an asymmetry in the temporal region of the arcuate fasciculus, reflecting interhemispheric differ-

ences in the macro- and microstructure. In addition, higher FA was observed in the left parietal segment of the fasciculus (Analysis C), which was not detected with the whole brain voxel-based approach (Analysis A) probably because the latter compared all left and right voxels of the brain, whereas a robust



**Figure 4.** FA asymmetry within tract segments (Analysis C). Asymmetry ratios in FA are presented for the segments of the arcuate fasciculus (a) and the cortico-spinal tract (b), with statistical significance of the one-tailed paired *t*-tests (see Table 3, ns: not significant). Abbreviations: cp: cerebral peduncles, plic: posterior limb of the internal capsule, lcs/hcs: low/high centrum semiovale.

averaging of the indices over the segment may be needed to uncover subtle differences.

In the whole brain voxel-based analysis of FA asymmetry (Analysis A), the most asymmetrical cluster, detected in the left temporal region of the arcuate fasciculus, appeared very similar to the results observed in adults (Buchel et al. 2004). However, in our study, this asymmetry may reflect the combined effects of higher longitudinal diffusivity (Analysis C) and of left-right differences in tract anatomical localization and geometry (Analysis B), as probability maps revealed a more posterior and larger left segment.

The early macroscopic asymmetry in the temporal arcuate fasciculus is probably related to asymmetries of the superior temporal sulcus, sylvian fissure, and *planum temporale* observed in the fetal and newborn brain (Witelson and Pallie 1973). During prenatal life, right sulci, among which the superior temporal sulcus, usually appear before their left counterpart (Chi et al. 1977). Furthermore, the surface of the right superior temporal sulcus is larger in preterm newborns (Dubois et al. 2007), the sylvian fissure is shorter and steeper on the right (Sowell et al. 2002), and the *planum temporale* is larger on the left side already in fetuses (Witelson and Pallie 1973; Chi et al. 1977). Thus, in the developing brain, the

superior and posterior temporal regions are at the epicenter of major left-right differences.

Beyond macroscopic geometrical asymmetries, we also observed left-right differences in the microstructure of the arcuate fasciculus. In the left temporal segment, higher  $\langle D \rangle$ , and  $\lambda_{//}$  (Analysis C) suggested a delayed “pre”-myelination stage on that side. This contrasts with the higher FA detected in the left parietal segment of the tract, which is rather related to a higher organization of parallel fibers than to an advanced “true” myelination, as this region matures slowly during early childhood (Pujol et al. 2006; Zhang et al. 2007) until late adolescence (Paus et al. 1999). These assumptions on the mechanisms underlying asymmetries should nevertheless be confirmed over a larger cohort of infants as congruent results were not obtained over all diffusion indices (Table 1). Our observations are however in agreement with a recent study, which showed a higher FA in the left fronto-temporal segment and right fronto-parietal segment of the fasciculus in children between 6 and 17 years old (Eluvathingal et al. 2007).

In summary, the asymmetry of the arcuate fasciculus is already present in early life, in terms of localization, organization, and maturation. Do these early structural asymmetries of the arcuate fasciculus sustain the developing functional lateralization of language perception? Although many DTI studies have underlined asymmetries of the arcuate fasciculus in adults, with a more extensive connectivity on the left side (Nucifora et al. 2005; Parker et al. 2005; Powell et al. 2006; Catani et al. 2007; Vernooij et al. 2007), the correlations with functional lateralization are still controversial (Powell et al. 2006; Vernooij et al. 2007). Dichotic listening (Bertoncini et al. 1989) and functional brain imaging studies in infants (Dehaene-Lambertz 2000; Dehaene-Lambertz et al. 2002; Peña et al. 2003; Dehaene-Lambertz, Hertz-Pannier, Dubois, Meriaux, et al. 2006) suggest that speech processing is biased toward the left hemisphere early on. Furthermore, the left frontal area, although immature, is already activated by speech perception at this age especially when short-term verbal memory is solicited by the experimental task (Dehaene-Lambertz, Hertz-Pannier, Dubois, Meriaux, et al. 2006). These findings suggest an early efficient temporo-parieto-frontal connection through the left arcuate fasciculus. The particular organization and maturation of the left fasciculus may thus sustain the progressive development of the speech perception-production network.

#### Cortico-Spinal Tract Asymmetry and Development of Sensori-Motor Functions

Although the whole cortico-spinal tract appeared to have a strictly similar geometry, size and localization on both sides (Analysis B), higher FA was revealed in the left relative to the right inferior region between the cerebral peduncles and the posterior limb of the internal capsule (Analyses A and C). In the midbrain and in the segment between the internal capsule and the low centrum semiovale, the analysis of DTI indices within the tract (Analysis C) also detected asymmetries which were not detected with the FA voxel-based method (Analysis A), probably because of lower sensitivity of this technique to subtle differences, as discussed for the arcuate fasciculus. Because the cortico-spinal tract reconstructed by tractography was larger than the image spatial resolution, and because similar tract volumes were observed in the left and right hemispheres, asymmetries of diffusion indices cannot be attributed to



asymmetrical tract thickness triggering different partial volume effects between the tract and surrounding tissue.

Asymmetries in the 3 lower segments of the cortico-spinal tract concern different diffusion indices and can be explained by various biophysical phenomena as outlined in Table 1: higher fibers organization or advanced “true” myelination in the left midbrain, advanced “true” myelination between the left cerebral peduncles and posterior limb of the internal capsule, and advanced “pre-” or “true” myelination in the left centrum semiovale. As the tract is made of continuous fibers, the cause of the asymmetries at different levels of the tract is likely to be the same and related to an advanced myelination on the left in comparison with the right.

It is interesting to note that asymmetry may have a specific spatial spread over the cortico-spinal tract, as we respectively detected 1) an asymmetry in FA, but not in  $\langle D \rangle$  in the midbrain, 2) asymmetries in  $\langle D \rangle$  and FA between the cerebral peduncles and the internal capsule, 3) only an asymmetry in  $\langle D \rangle$  between the internal capsule and the low centrum semiovale, and 4) no asymmetry in the upper portion of the tract. Post-mortem studies have described that the myelination sequence extends between the third trimester of gestation and the first postnatal months in the cortico-spinal tract (Brody et al. 1987; Kinney et al. 1988). Furthermore, because myelination progresses from the neuron body to the periphery (McCart and Henry 1994) and starts in sensory pathways before motor pathways (Yakovlev and Lecours 1967), changes in white matter intensity are observed in  $T_1$ -weighted MRI images in the midbrain and posterior limb of the internal capsule before the centrum semiovale and subcortical white matter (McArdle et al. 1987). As we showed in a previous paper that mean diffusivity reflects white matter maturation earlier than FA (Dubois et al. 2008), our present results likely suggest that the maturation of the somatosensory fibers in the cortico-spinal tract is observed in this age range, and that the asymmetry in myelination in favor of the left side progresses from the inferior to the superior regions: myelination on the right begins to catch up the left one in the midbrain, where no more asymmetry in  $\langle D \rangle$  was observed, whereas the asymmetry is only starting above the posterior limb of the internal capsule, where only an asymmetry in  $\langle D \rangle$  was observed.

Previous studies already described structural asymmetries of the cortico-spinal tract in the more mature brain. In children from 6 to 17 years old, FA measured over the whole tract is higher on the left side (Eluvathingal et al. 2007). In adults, significant differences in DTI indices (higher FA and lower  $\langle D \rangle$  on the left) have been observed at the level of the posterior limb of the internal capsule (Westerhausen et al. 2007). The cortico-spinal tract also appears thicker (Rademacher, Burgel, et al. 2001) and the subcortical white matter more anisotropic in the precentral region contra-lateral to the predominant hand (Buchel et al. 2004), but the overall DTI-based relative fiber density is not different between both hemispheres (Nucifora et al. 2005).

It is not possible to conclude whether this observed advance of maturation in the left cortico-spinal tract is at the origin of behavioral asymmetry. Although individual children do not show reliable evidence of hand preference in voluntary movements before the second postnatal year, some studies have revealed a slight right preference for spontaneous movements at a group level from the last trimester of gestation on (Hepper et al. 1991), but these results have not been

consistently reproduced. This right side preference might be related to structural differences between the left and right sensori-motor cortical organization, and/or to an asymmetrical position within the womb which frees the right side (Hepper et al. 2005), and/or to an environment in which heavily right handed biased parents favor one side (Leconte and Fagard 2004). Using functional MRI (fMRI), Erberich et al. (2006) found no difference between ipsi- and contra-lateral responses during passive hand stimulations in newborns, contrarily to older infants who display asymmetrical responses favoring the contra-lateral side. In this study, we did not observe an increase of structural asymmetry in the 15-weeks age range studied, suggesting no obvious change at least during the first postnatal weeks, in contrast with functional asymmetry. More data are needed in order to understand the relationship between these different behavioral, functional and structural markers. Be that as it may, our results confirm an indisputable early structural asymmetry in the human sensori-motor network, which is present before a robust asymmetrical use of the right hand.

### *Other Asymmetries of the Developing Brain*

Using the whole brain voxel-based analysis in FA, other cerebral regions were found to be significantly asymmetrical in infants, but we here focused on the language-related and sensori-motor networks. Further analyses should be considered to precise the localization of these regions, their functional implication and significance in the developing brain, and to understand the underlying mechanisms of such asymmetries in terms of maturation, organization or geometry processes.

### *Methodological Issues*

In this study, complementary methods of asymmetries analysis in local diffusion indices and fascicles localization were used in order to reach a reliable interpretation of the interhemispheric differences of the arcuate fasciculus and cortico-spinal tract. Each method presented distinct advantages and drawbacks.

The FA voxel-based analysis (Analysis A) was used to underline interhemispheric asymmetries without a priori hypotheses on their anatomical localization (Barnea-Goraly et al. 2005). However, the DTI normalization procedure is still controversial (Jones et al. 2005) and challenging in infants because of brain growth. Here we used a special procedure optimized for the infants group, based on the creation of a specific FA template, which enabled to globally take into account macroscopic interhemispheric differences, such as frontal and occipital petalias. The insufficient realignment of the left and right arcuate fascicles by the normalization process probably results from 3 factors. First, the tract was larger, with 2 branches, on the left side. Second, the localization of the posterior part of the sylvian fissure is asymmetrical, i.e. more superior on the right side in adults and children (Sowell et al. 2002), implying a posterior shift of the left temporal region, including the arcuate fasciculus. Third, immature white matter bundles with low FA are difficult to realign precisely, as close FA values in both the tract and the surrounding tissues result in a low local contrast in the FA template. On the contrary, the normalization was sufficient to precisely realign the cortico-spinal tract, because of its stable localization in the brain central regions and its relatively high FA compared with surrounding tissue. In this perspective, applying more refined registration approaches like Tract-Based Spatial Statistics (Smith et al. 2006; Anjari et al. 2007) could have been

considered in the developing brain, but limitations related to the asymmetrical tract size would have probably remained. Such issue thus underlined the necessity to correlate complementary methods before interpreting asymmetry results from FA voxel-based analysis.

The voxel-based analysis of tract localization and geometry (Analysis B) was used to outline the 3D macroscopic asymmetry of the tracts. The individual analysis of diffusion indices within the tracts (Analysis C) seemed most sensitive for the detection of asymmetries. However, the tractography method, which requires manual drawing of regions for seed placement and tract selection, is time-consuming and user-dependent. Moreover, it focuses on specific bundles and asymmetries in the frontal arcuate fasciculus could not be evaluated because this tract segment was not reliably reconstructed in all infants.

Consequently, all 3 methods were complementary for the study of brain asymmetries, and provided a reliable evaluation of the interhemispheric differences in the immature arcuate fasciculus and cortico-spinal tract. Whereas this study cannot disentangle whether these structural asymmetries are the cause or consequence of the developing functional asymmetries, it will serve as a basis for further correlations with later functional scores.

## Conclusion

In this DTI study in infants, we demonstrated early interhemispheric leftward asymmetries in the microstructure and maturation of both the arcuate fasciculus and cortico-spinal tract, in addition to macroscopic left-right differences in the former. These results provide new and unique data which support the hypothesis that the development of functional lateralization of language-related and sensori-motor networks during infancy and childhood is related to early structural processes that take place in the immature brain before sustained exposure to environmental stimulations.

## Funding

McDonnell foundation and ANR for financial support to G.D.L.

## Notes

We thank C. Poupon, F. Lethimonnier, D. Rivière, Y. Cointepas, and M. Perrin for support on DTI acquisition and postprocessing, Mr Brunet from Ravier-Touzard Company for designing a baby bouncer chair specifically adapted to the head coil, F. Brunelle for its support. *Conflict of Interest*: None declared.

Address correspondence to Jessica Dubois, PhD, U663 Hôpital Necker-Enfants malades, 149 rue de Sèvres, 75015 Paris, France. Email: jessica.dubois@centraaliens.net.

## References

Anjari M, Srinivasan L, Allsop JM, Hajnal JV, Rutherford MA, Edwards AD, Counsell SJ. 2007. Diffusion tensor imaging with tract-based spatial statistics reveals local white matter abnormalities in preterm infants. *Neuroimage*. 35:1021-1027.

Barnea-Goraly N, Menon V, Eckert M, Tamm L, Bammner R, Karchemskiy A, Dant CC, Reiss AL. 2005. White matter development during childhood and adolescence: a cross-sectional diffusion tensor imaging study. *Cereb Cortex*. 15:1848-1854.

Beaulieu C. 2002. The basis of anisotropic water diffusion in the nervous system—a technical review. *NMR Biomed*. 15:435-455.

Bertoncini J, Morais J, Bijeljac-Babic R, McAdams S, Peretz I, Mehler J. 1989. Dichotic perception and laterality in neonates. *Brain Lang*. 37:591-605.

Best CT. 1988. The emergence of cerebral asymmetries in early human development: a literature review and a neuroembryological model. In: Molfese D, Segalowitz SJ, editors. *Brain lateralization in children*. New York: The Guilford Press.

Brody BA, Kinney HC, Kloman AS, Gilles FH. 1987. Sequence of central nervous system myelination in human infancy. I. An autopsy study of myelination. *J Neuropathol Exp Neurol*. 46:283-301.

Buchel C, Raedler T, Sommer M, Sach M, Weiller C, Koch MA. 2004. White matter asymmetry in the human brain: a diffusion tensor MRI study. *Cereb Cortex*. 14:945-951.

Burgel U, Amunts K, Hoemke L, Mohlberg H, Gilsbach JM, Zilles K. 2006. White matter fiber tracts of the human brain: Three-dimensional mapping at microscopic resolution, topography and intersubject variability. *Neuroimage*. 29:1092-1105.

Cao Y, Whalen S, Huang J, Berger KL, DeLano MC. 2003. Asymmetry of subinsular anisotropy by in vivo diffusion tensor imaging. *Hum Brain Mapp*. 20:82-90.

Catani M, Allin MP, Husain M, Pugliese L, Mesulam MM, Murray RM, Jones DK. 2007. Symmetries in human brain language pathways correlate with verbal recall. *Proc Natl Acad Sci USA*. 104:17163-17168.

Chi JG, Dooling EC, Gilles FH. 1977. Left-right asymmetries of the temporal speech areas of the human fetus. *Arch Neurol*. 34:346-348.

Chiron C, Jambaque I, Nabbout R, Lounes R, Syrota A, Dulac O. 1997. The right brain hemisphere is dominant in human infants. *Brain*. 120:1057-1065.

Ciccarelli O, Toosy AT, Parker GJ, Wheeler-Kingshott CA, Barker GJ, Miller DH, Thompson AJ. 2003. Diffusion tractography based group mapping of major white-matter pathways in the human brain. *Neuroimage*. 19:1545-1555.

Cointepas Y, Poupon C, Maroy R, Riviere D, Le Bihan D, Mangin JF. 2003. A freely available Anatomist/BrainVISA package for analysis of diffusion MR data. Proceedings of the 9<sup>th</sup> HBM Scientific Meeting, New York, USA. *Neuroimage*. 19:S810.

Corbetta D, Thelen E. 1999. Lateral biases and fluctuations in infants' spontaneous arm movements and reaching. *Dev Psychobiol*. 34:237-255.

Dehaene-Lambertz G. 2000. Cerebral specialization for speech and non-speech stimuli in infants. *J Cogn Neurosci*. 12:449-460.

Dehaene-Lambertz G, Dehaene S, Hertz-Pannier L. 2002. Functional neuroimaging of speech perception in infants. *Science*. 298:2013-2015.

Dehaene-Lambertz G, Hertz-Pannier L, Dubois J. 2006. Nature and nurture in language acquisition: anatomical and functional brain-imaging studies in infants. *Trends Neurosci*. 29:367-373.

Dehaene-Lambertz G, Hertz-Pannier L, Dubois J, Meriaux S, Roche A, Sigman M, Dehaene S. 2006. Functional organization of perisylvian activation during presentation of sentences in preverbal infants. *Proc Natl Acad Sci USA*. 103:14240-14245.

Dubois J, Benders M, Cachia A, Lazeyras F, Ha-Vinh Leuchter R, Zizonenko SV, Borradori-Tolsa C, Mangin JF, Hüppi PS. 2007. Mapping the early cortical folding process in the preterm newborn brain. *Cereb Cortex*. 18:1444-1454.

Dubois J, Dehaene-Lambertz G, Perrin M, Mangin JF, Cointepas Y, Duchesnay E, Le Bihan D, Hertz-Pannier L. 2008. Asynchrony of the early maturation of white matter bundles in healthy infants: quantitative landmarks revealed non-invasively by diffusion tensor imaging. *Hum Brain Mapp*. 29:14-27.

Dubois J, Hertz-Pannier L, Dehaene-Lambertz G, Cointepas Y, Le Bihan D. 2006. Assessment of the early organization and maturation of infants' cerebral white matter fiber bundles: a feasibility study using quantitative diffusion tensor imaging and tractography. *Neuroimage*. 30:1121-1132.

Eluvathingal TJ, Hasan KM, Kramer L, Fletcher JM, Ewing-Cobbs L. 2007. Quantitative diffusion tensor tractography of association and projection fibers in normally developing children and adolescents. *Cereb Cortex*. 17:2760-2768.

Erberich SG, Panigrahy A, Friedlich P, Seri I, Nelson MD, Gilles F. 2006. Somatosensory lateralization in the newborn brain. *Neuroimage*. 29:155-161.

- Fabiano AJ, Horsfield MA, Bakshi R. 2005. Interhemispheric asymmetry of brain diffusivity in normal individuals: a diffusion-weighted MR imaging study. *Am J Neuroradiol*. 26:1089-1094.
- Fagard J, Marks A. 2000. Unimanual and bimanual tasks and the assessment of handedness in toddlers. *Dev Sci*. 3:137-147.
- Galaburda AM, Geschwind N. 1981. Anatomical asymmetries in the adult and developing brain and their implications for function. *Adv Pediatr*. 28:271-292.
- Gilmore JH, Lin W, Prastawa MW, Looney CB, Vetsa YS, Knickmeyer RC, Evans DD, Smith JK, Hamer RM, Lieberman JA, et al. 2007. Regional gray matter growth, sexual dimorphism, and cerebral asymmetry in the neonatal brain. *J Neurosci*. 27:1255-1260.
- Glenn OA, Henry RG, Berman JJ, Chang PC, Miller SP, Vigneron DB, Barkovich AJ. 2003. DTI-based three-dimensional tractography detects differences in the pyramidal tracts of infants and children with congenital hemiparesis. *J Magn Reson Imaging*. 18:641-648.
- Gong G, Jiang T, Zhu C, Zang Y, Wang F, Xie S, Xiao J, Guo X. 2005. Asymmetry analysis of cingulum based on scale-invariant parameterization by diffusion tensor imaging. *Hum Brain Mapp*. 24:92-98.
- Hepper PG, Shahidullah S, White R. 1991. Handedness in the human fetus. *Neuropsychologia*. 29:1107-1111.
- Hepper PG, Wells DL, Lynch C. 2005. Prenatal thumb sucking is related to postnatal handedness. *Neuropsychologia*. 43:313-315.
- Hochberg FH, Le May M. 1975. Arteriographic correlates of handedness. *Neurology*. 25:218-222.
- Ingram D. 1975a. Motor asymmetries in young children. *Neuropsychologia*. 13:95-102.
- Ingram D. 1975b. Cerebral speech lateralization in young children. *Neuropsychologia*. 13:103-105.
- Jones DK, Symms MR, Cercignani M, Howard RJ. 2005. The effect of filter size on VBM analyses of DT-MRI data. *Neuroimage*. 26:546-554.
- Kimura D. 1967. Functional asymmetry of the brain in dichotic listening. *Cortex*. 3:163-178.
- Kinney HC, Brody BA, Kloman AS, Gilles FH. 1988. Sequence of central nervous system myelination in human infancy 2: Patterns of myelination in autopsied infants. *J Neuropathol Exp Neurol*. 47:217-234.
- Le Bihan D, Mangin JF, Poupon C, Clark CA, Pappata S, Molko N, Chabriat H. 2001. Diffusion tensor imaging: concepts and applications. *J Magn Reson Imaging*. 13:534-546.
- Leconte P, Fagard J. 2004. Influence of object spatial location and task complexity on children's use of their preferred hand depending on their handedness consistency. *Dev Psychobiol*. 45:51-58.
- Mangin JF, Poupon C, Clark C, Le Bihan D, Bloch I. 2002. Distortion correction and robust tensor estimation for MR diffusion imaging. *Med Image Anal*. 6:191-198.
- McArdle CB, Richardson CJ, Nicholas DA, Mirfakhraee M, Hayden CK, Amparo EG. 1987. Developmental features of the neonatal brain: MR imaging. Part 1, Gray-white matter differentiation and myelination. *Radiology*. 162:223-229.
- McCart RJ, Henry GH. 1994. Visual corticogeniculate projections in the cat. *Brain Res*. 653:351-356.
- Mori S, van Zijl PC. 2002. Fiber tracking: principles and strategies—a technical review. *NMR Biomed*. 15:468-480.
- Neil JJ, Miller J, Mukherjee P, Hüppi PS. 2002. Diffusion tensor imaging of normal and injured developing human brain—a technical review. *NMR Biomed*. 15:543-552.
- Nucifora PG, Verma R, Melhem ER, Gur RE, Gur RC. 2005. Leftward asymmetry in relative fiber density of the arcuate fasciculus. *Neuroreport*. 16:791-794.
- Ottaviano S, Guidetti V, Allemand F, Spinotoli B, Seri S. 1989. Laterality of arm movement in full-term newborn. *Early Hum Dev*. 19:3-7.
- Park HJ, Westin CF, Kubicki M, Maier SE, Niznikiewicz M, Baer A, Frumin M, Kikinis R, Jolesz FA, McCarley RW, et al. 2004. White matter hemisphere asymmetries in healthy subjects and in schizophrenia: a diffusion tensor MRI study. *Neuroimage*. 23:213-223.
- Parker GJ, Luzzi S, Alexander DC, Wheeler-Kingshott CA, Ciccarelli O, Lambon Ralph MA. 2005. Lateralization of ventral and dorsal auditory-language pathways in the human brain. *Neuroimage*. 24:656-666.
- Paus T, Zijdenbos A, Worsley K, Collins DL, Blumenthal J, Giedd JN, Rapoport JL, Evans AC. 1999. Structural maturation of neural pathways in children and adolescents: in vivo study. *Science*. 283:1908-1911.
- Peña M, Maki A, Kovacic D, Dehaene-Lambertz G, Koizumi H, Bouquet F, Mehler J. 2003. Sounds and silence: an optical topography study of language recognition at birth. *Proc Natl Acad Sci USA*. 100:11702-11705.
- Penhune VB, Zatorre RJ, MacDonald JD, Evans AC. 1996. Interhemispheric anatomical differences in human primary auditory cortex: probabilistic mapping and volume measurement from magnetic resonance scans. *Cereb Cortex*. 6:661-672.
- Perrin M, Poupon C, Cointepas Y, Rieul B, Golestani N, Pallier C, Rivière D, Constantinesco A, Le Bihan D, Mangin JF. 2005. Fiber tracking in q-ball fields using regularized particle trajectories. *Inf Process Med Imaging*. 19:52-63.
- Pierpaoli C, Basser PJ. 1996. Toward a quantitative assessment of diffusion anisotropy. *Magn Reson Med*. 36:893-906.
- Powell HW, Parker GJ, Alexander DC, Symms MR, Boulby PA, Wheeler-Kingshott CA, Barker GJ, Noppeney U, Koeppe MJ, Duncan JS. 2006. Hemispheric asymmetries in language-related pathways: a combined functional MRI and tractography study. *Neuroimage*. 32:388-399.
- Pujol J, Soriano-Mas C, Ortiz H, Sebastián-Gallés N, Losilla JM, Deus J. 2006. Myelination of language-related areas in the developing brain. *Neurology*. 66:339-343.
- Rademacher J, Caviness VS, Jr, Steinmetz H, Galaburda AM. 1993. Topographical variation of the human primary cortices: implications for neuroimaging, brain mapping, and neurobiology. *Cereb Cortex*. 3:313-329.
- Rademacher J, Burgel U, Geyer S, Schormann T, Schleicher A, Freund HJ, Zilles K. 2001. Variability and asymmetry in the human precentral motor system. A cytoarchitectonic and myeloarchitectonic brain mapping study. *Brain*. 124:2232-2258.
- Rademacher J, Morosan P, Schormann T, Schleicher A, Werner C, Freund HJ, Zilles K. 2001. Probabilistic mapping and volume measurement of human primary auditory cortex. *Neuroimage*. 13:669-683.
- Ronnqvist L, Domellöf E. 2006. Quantitative assessment of right and left reaching movements in infants: a longitudinal study from 6 to 36 months. *Dev Psychobiol*. 48:444-459.
- Smith SM, Jenkinson M, Johansen-Berg H, Rueckert D, Nichols TE, Mackay CE, Watkins KE, Ciccarelli O, Cader MZ, Matthews PM, et al. 2006. Tract-based spatial statistics: voxelwise analysis of multi-subject diffusion data. *Neuroimage*. 31:1487-1505.
- Sowell ER, Thompson PM, Rex D, Kornsand D, Tessner KD, Jernigan TL, Toga AW. 2002. Mapping sulcal pattern asymmetry and local cortical surface gray matter distribution in vivo: maturation in perisylvian cortices. *Cereb Cortex*. 12:17-26.
- Toga AW, Thompson PM. 2003. Mapping brain asymmetry. *Nat Rev Neurosci*. 4:37-48.
- Vernooij MW, Smits M, Wielopolski PA, Houston GC, Krestin GP, van der Lugt A. 2007. Fiber density asymmetry of the arcuate fasciculus in relation to functional hemispheric language lateralization in both right- and left-handed healthy subjects: a combined fMRI and DTI study. *Neuroimage*. 35:1064-1076.
- Westerhausen R, Huster RJ, Kreuder F, Wittling W, Schweiger E. 2007. Corticospinal tract asymmetries at the level of the internal capsule: is there an association with handedness? *Neuroimage*. 37:379-386.
- Witelson SF, Pallie W. 1973. Left hemisphere specialization for language in the newborn. Neuroanatomical evidence of asymmetry. *Brain*. 96:641-646.
- Yakovlev PI, Lecours AR. 1967. The myelogenetic cycles of regional maturation in the brain. In: Minowski A, editor. Regional development of the brain in early life. Oxford: Blackwell. p. 3-69.
- Zhang J, Evans A, Hermoye L, Lee SK, Wakana S, Zhang W, Donohue P, Miller MI, Huang H, Wang X, et al. 2007. Evidence of slow maturation of the superior longitudinal fasciculus in early childhood by diffusion tensor imaging. *Neuroimage*. 38:239-247.