



HAL
open science

Measurement of the liver stiffness with two imaging techniques: magnetic resonance elastography and ultrasound elastometry.

S.F. Bensamoun, L. Wang, Laurent Robert, F. Charleux, J.P. Latrive, M.C.
Ho Ba Tho

► To cite this version:

S.F. Bensamoun, L. Wang, Laurent Robert, F. Charleux, J.P. Latrive, et al.. Measurement of the liver stiffness with two imaging techniques: magnetic resonance elastography and ultrasound elastometry.. J. Magn. Reson. Imaging, 2008, 28, pp.1287-1292. 10.1002/jmri.21523 . hal-00336358

HAL Id: hal-00336358

<https://hal.science/hal-00336358>

Submitted on 31 Oct 2022

HAL is a multi-disciplinary open access archive for the deposit and dissemination of scientific research documents, whether they are published or not. The documents may come from teaching and research institutions in France or abroad, or from public or private research centers.

L'archive ouverte pluridisciplinaire **HAL**, est destinée au dépôt et à la diffusion de documents scientifiques de niveau recherche, publiés ou non, émanant des établissements d'enseignement et de recherche français ou étrangers, des laboratoires publics ou privés.

Measurement of Liver Stiffness With Two Imaging Techniques: Magnetic Resonance Elastography and Ultrasound Elastometry

Sabine F. Bensamoun, PhD,^{1*} Lu Wang, MS,¹ Ludovic Robert, Mr,²
Fabrice Charleux, MD,² Jean-Paul Latrive, MD,³ and Marie-Christine Ho Ba Tho, PhD¹

Purpose: To cross-validate the magnetic resonance elastography (MRE) technique with a clinical device, based on an ultrasound elastometry system called Fibroscan.

Materials and Methods: Ten healthy subjects underwent an MRE and a Fibroscan test. The MRE technique used a round pneumatic driver at 60 Hz to generate shear waves inside the liver. An elastogram representing a map of the liver stiffness was generated allowing for the measurement of the average liver stiffness inside a region of interest. The Fibroscan technique used an ultrasound probe (3.5 MHz) composed of a vibrator that sent low-frequency (50 Hz) shear waves inside the right liver lobe. The probe acts as an emitter-receptor that measures the velocity of the waves propagated inside the liver tissue.

Results: The mean shear stiffness measured with the MRE and Fibroscan techniques were 1.95 ± 0.06 kPa and 1.79 ± 0.30 kPa, respectively. A higher standard deviation was found for the same subject with Fibroscan.

Conclusion: This study shows why MRE should be investigated beyond the Fibroscan. The MRE technique provided elasticity of the entire liver, meanwhile the Fibroscan provided values of elasticity locally.

Key Words: magnetic resonance elastography; Fibroscan; liver; cross-validation

J. Magn. Reson. Imaging 2008;28:1287–1292.
© 2008 Wiley-Liss, Inc.

THE QUANTIFICATION OF hepatic fibrosis is of major importance during chronic diseases of the liver, among which the therapeutic indications and the diagnosis

depend on it widely. The histological examination, obtained by biopsy, was for a long time considered the preferred reference examination, allowing an evaluation of the fibrosis. However, the limits of the biopsy (rarely arising but sometimes serious complications, invasive and possibly painful procedure, variability of interobservers, fluctuations in samples) led to a search for and the development of noninvasive alternative methods that are more easily repeatable. The measurement of indirect markers (prothrombin rate and platelet) or direct (hyaluronic acid) can be used but their performance is sometimes limited. The mixture of several biological markers to estimate a score of fibrosis provides satisfactory but still imperfect results, notably for the intermediate stages of fibrosis. Among the different proposed tests the Fibrotest, validated for chronic hepatitis C, was the most studied. The FibroMeters are of more recent development and several types are proposed according to the etiology of the chronic hepatic disease (virus, alcohol, metabolic syndrome). The results are expressed in a score with equivalence in stage METAVIR (histological stage) and in area, allowing an estimate of the percentage of fibrosis developed in the liver. The lack of reliable noninvasive results shows that there is a need for noninvasive techniques.

Recently, elastometry or Fibroscan based on transient elastography has been clinically used to measure the level of liver stiffness with a modified ultrasound probe (1). The distorted samples, underlined for the histological examination of the liver, are lesser because this ultrasound technique investigates a volume ≈ 100 times superior to that of the fragment obtained by biopsy. Several studies showed that ultrasound-based transient elastography technique is an alternative technique to liver biopsy to detect cirrhosis (2). Moreover, liver stiffness, measured with the Fibroscan, was correlated with the fibrosis stage, confirmed with biological markers and histological analysis (3–5). However, obesity and hepatic steatosis are still a limit for the Fibroscan technique because the waves are rapidly (6) attenuated in the presence of subcutaneous tissue. The simplicity of the method and its performance quickly facilitated its clinical development during the various

¹Biomechanics and Bioengineering Laboratory, UMR CNRS 6600, Université de Technologie de Compiègne, Compiègne, France.

²Centre d'Imagerie Médicale Avancée, Compiègne, France.

³Centre hospitalier de Compiègne, service gastro-entérologie et hépatologie, Compiègne, France.

*Address reprint requests to: S.B., Université de Technologie de Compiègne (UTC), Centre de Recherches de Royallieu, Laboratoire de Biomécanique et Bioingénierie, UMR CNRS 6600, BP 20529, Rue Personne de Roberval, 60205 Compiègne cedex, France.
E-mail: sabine.bensamoun@utc.fr

Received March 10, 2008; Accepted June 18, 2008.

DOI 10.1002/jmri.21523

Published online in Wiley InterScience (www.interscience.wiley.com).

chronic liver diseases. The combination of elastometry and biological markers allows, when there is concordance, an increase in the performance of these noninvasive methods.

Another imaging technique, called magnetic resonance elastography (MRE), still in clinical research, is able to measure the stiffness of different soft tissues (7–9). Studies demonstrate that the MRE technique is a feasible method to stage liver fibrosis and diagnose cirrhosis (10–12). In addition, the MRE technique was applied to a knockout animal model of liver fibrosis demonstrating the potential of the MRE technique to track and to evaluate the methods of treatment, and to validate future therapies for patients with liver diseases (13). MRE allows for the study of the totality of the hepatic gland, and is not limited by the existence of obesity, and could constitute a complementary or alternative technique, notably when MRI is indicated, to depict liver diseases.

The purpose of this study was to cross-validate the MRE technique with a routinely used clinical device, the Fibroscan technique.

MATERIALS AND METHODS

Participants

Ten healthy volunteers (five men, five women, age 33.5 ± 10.1 , range 25–55, body mass index [BMI] 24.21 ± 2.60) underwent an MRE scan followed by a Fibroscan exam. The study was approved by the Institutional Review Board and written informed consent was obtained.

Experimental Setup for MRE

The experimental setup was designed similar to a previous study (13) and is briefly summarized here. During the MRE experiment the subjects were imaged in the supine position with a 1.5T Signa MRI scanner (General Electric, Milwaukee, WI) and the body coil was used. An acoustic driver (diameter: 16 cm) was placed on the abdomen over the liver (Fig. 1b). One extremity of the driver was connected to a large active loudspeaker that generates acoustic waves at 60 Hz inside the liver.

A gradient-echo sequence was used to obtain a coronal image of the liver. To determine the best images representing the entire hepatic gland, two series of parallel slices (thickness: 10 mm) across the liver were drawn and axial images were obtained (Fig. 2a). Two presaturation bands were placed on each side of the selected slices to avoid flux artifacts. MRE images (Fig. 2b) were obtained with a motion-sensitized gradient echo sequence, collected at four time offsets (phase offsets) between the start of the motion and the motion-encoding gradients. Each scan took 16 seconds (32 discarded acquisitions at the beginning of the sequence) to acquire and during each time of acquisition the subject held his/her breath to avoid motion of the liver caused by displacement of the diaphragm.

The acquisition matrix was 256×64 (which was interpolated to 256×256), the flip angle was 30° , the field of view was 34 cm, the received bandwidth was 15.63 kHz, the frequency direction was R/L, and the

signal-to-noise ratio (SNR) was 100%. The TR was 100 msec and the TE corresponded to the minimum echo time (26.8 msec) that allowed for motion encoding.

Image Processing and Data Analysis

The entire shear stiffness (μ) of the liver was measured inside a region of interest (ROI) of the elastogram (Fig. 2c), which was generated by a direct inversion algorithm (14), using the formula $\mu = \rho \cdot (f \cdot \lambda)^2$, where ρ is the density of hepatic tissue (rough estimation: 1000 kg/m^3), f is the acoustic wave frequency (60 Hz), and λ is the wavelength propagating inside the liver.

Experimental Setup With Fibroscan Technique

The experimental setup was designed similar to a previous study (13) and is briefly summarized here. During the Fibroscan experiment the subjects laid down with the right arm in maximal abduction. An ultrasound probe (3.5 MHz) was placed between intercostal spaces (Fig. 1a). A vibrator located on the probe sent low-frequency (50 Hz) shear waves inside the right lobe. The probe is an emitter-receptor that measures the velocity of the waves propagated inside the liver tissue.

Image Processing and Data Analysis

The signal recorded during the ultrasound test is represented through an elastogram reflecting the depth of propagation as a function of the acquisition time (Fig. 3). The liver stiffness (Young's modulus) is represented by the slope of the straight line. Young's modulus was calculated as an average of 10 validated measurements. The acquisitions are defined as valid when the shape of the signal recorded during the ultrasound test shows a crimp behavior reflecting the hepatic tissue. The waves were propagated at a depth of 60 mm and Young's modulus was calculated with the following equation: $E = 3\mu$.

Statistical Analysis

T-tests were performed with the software Statgraphics 5.0 (Sigma Plus, Bethesda, MD) in order to compare the liver stiffness measured with the 2D MRE and the Fibroscan techniques ($P < 0.05$).

RESULTS

Figure 4 shows the shear stiffness obtained with both imaging techniques for each subject. The average shear stiffness (μ) of the entire liver, measured with the MRE technique on both acquired slices, was 1.95 ± 0.06 kPa. Young's modulus measured with the Fibroscan technique was 5.37 ± 0.90 kPa. Considering that the hepatic tissue was homogeneous and has an isotropic behavior, the shear stiffness (μ) obtained with the Fibroscan should be ($\mu = E/3$) 1.79 ± 0.30 kPa. We can conclude that the shear modulus obtained with the MRE and Fibroscan techniques are in the same range and no significant difference was found between the liver stiffness measured with either imaging technique.

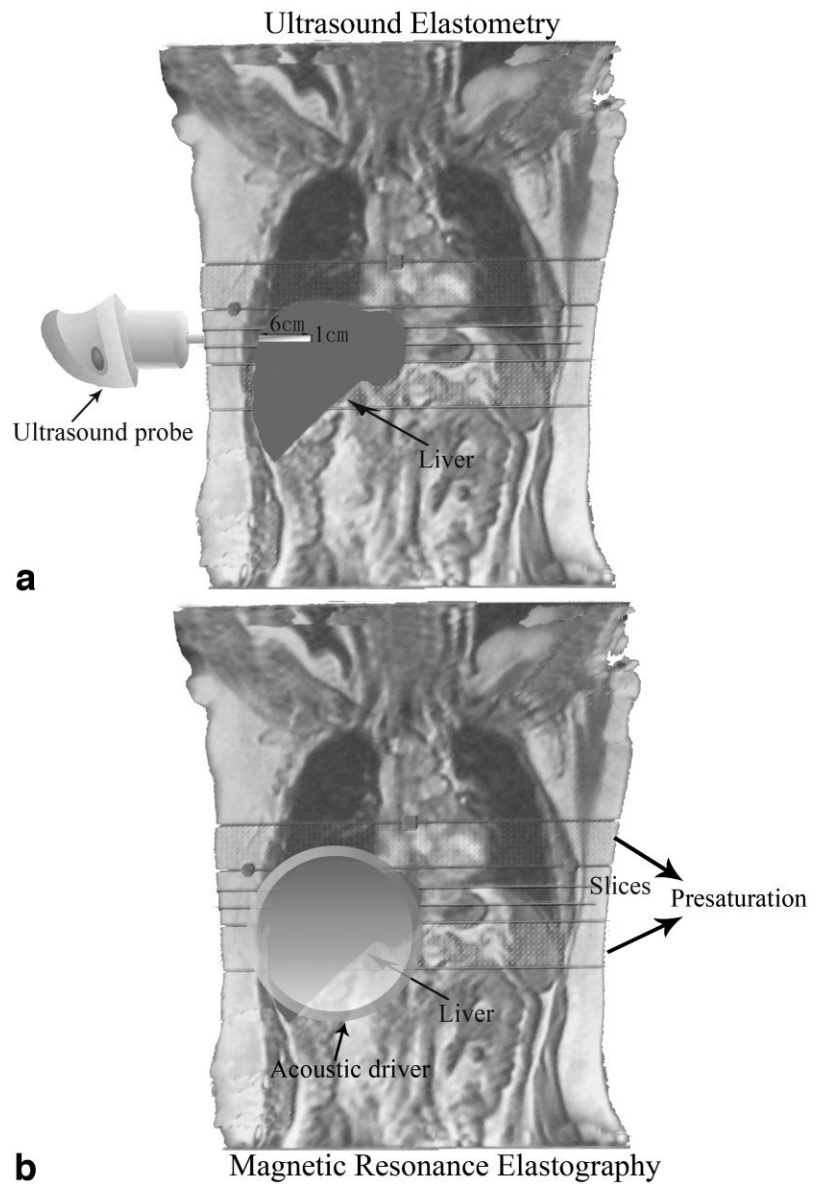


Figure 1. Position of the ultrasound probe (a) and acoustic driver (b) used for the ultrasound elastometry and MRE techniques, respectively.

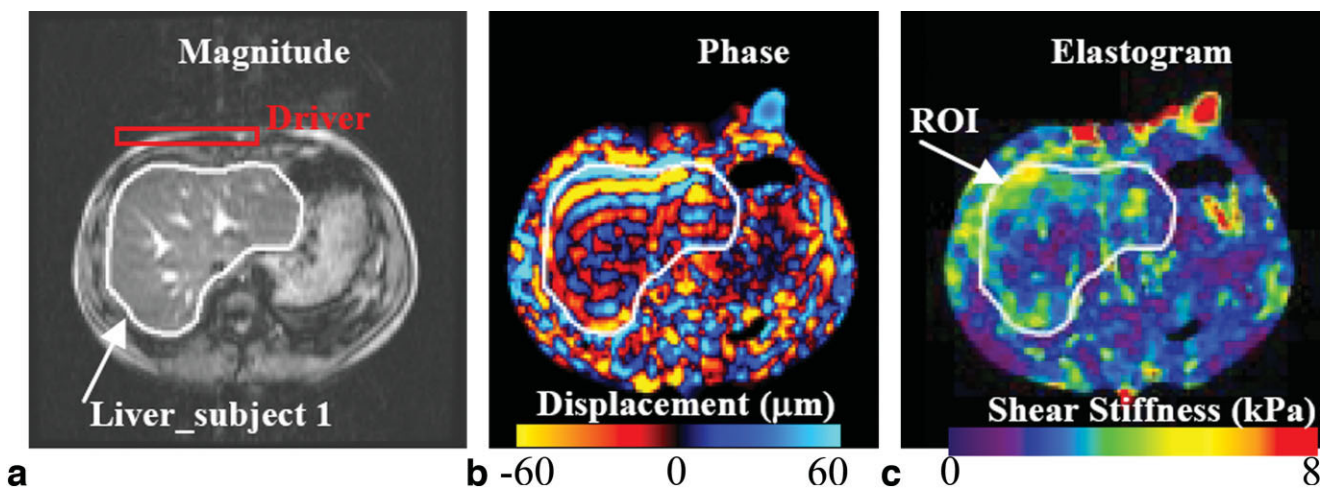


Figure 2. a: Anatomical image of the liver tissue. b: Phase image. c: Elastogram with ROI where the shear stiffness is measured.

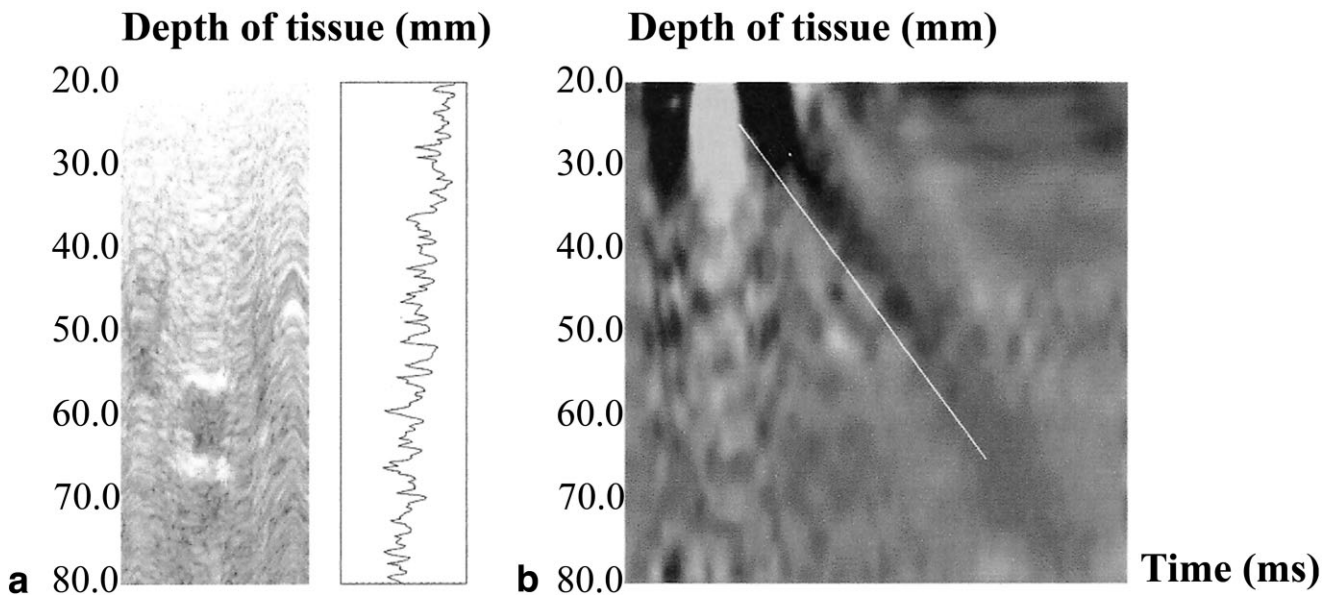


Figure 3. **a:** Signal recorded during the ultrasound test. **b:** Elastogram representing the depth of propagation depending of the acquisition time. The Young modulus is represented by the slope of the straight line.

MRE liver stiffnesses measured inside the region of interest (Fig. 2c) were in the same range (2.1 ± 0.3 kPa) as the literature for healthy subjects (13). Moreover, in one healthy subject (#7) tested with the MRE technique the presence of cysts inside the bladder was found. Figure 5b,c shows the shear waves circle this obstacle. This result demonstrated the sensitivity of the wave to

the intrinsic structure of the hepatic tissue and the advantage of the MRI acquisition to visualize the entire hepatic gland, allowing for the depiction of abnormal structures.

Among the group of subjects tested with the Fibrosan, two supposed healthy volunteers had a Young modulus superior to the normal (6 kPa) reference. The

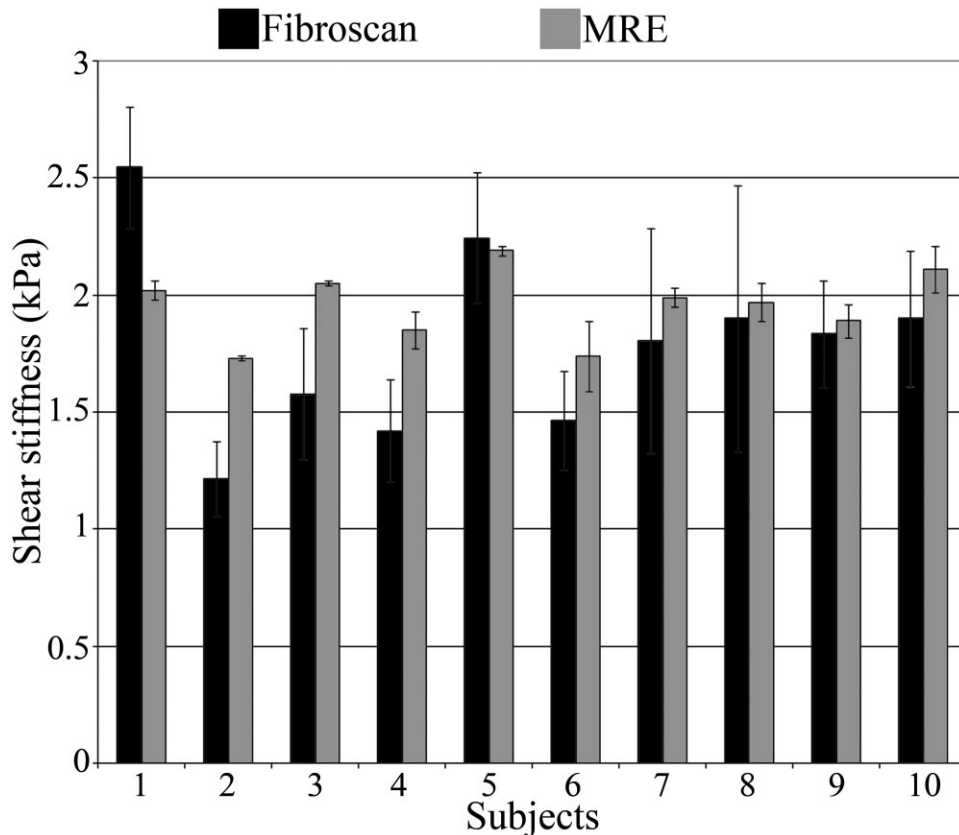


Figure 4. Comparison between stiffnesses obtained with the MRE and Fibrosan techniques

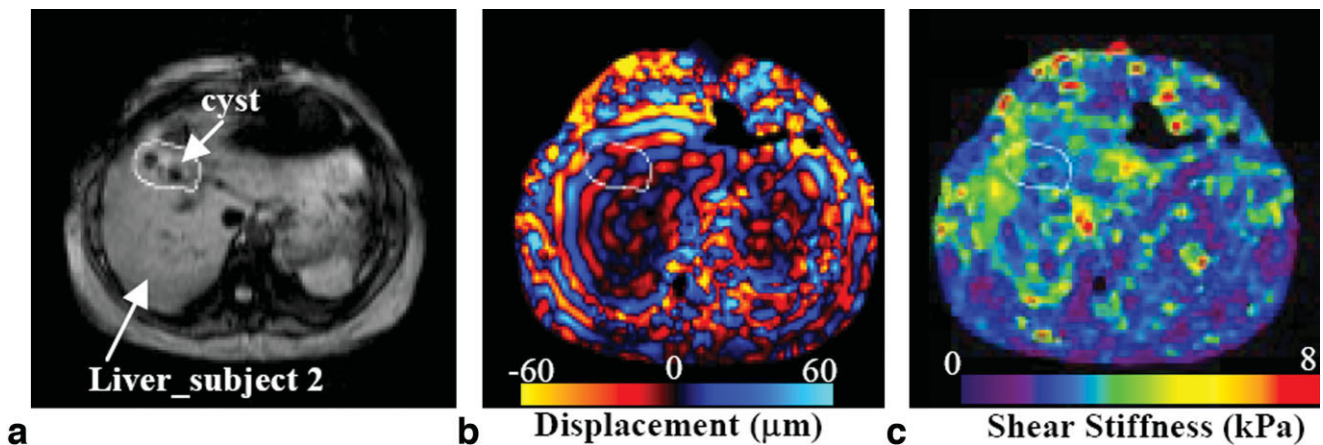


Figure 5. a: Anatomical image of the liver tissue with the presence of cysts inside the bladder. b: Phase image showing the shear waves circle the cysts. c: Elastogram with ROI where the shear stiffness is measured.

Young modulus recorded for subject #1 and subject #3 was 7.7 ± 0.79 kPa and 8.4 ± 1.67 kPa (range, 5.3–9.5 kPa), respectively. Consequently, the high stiffness measured for subject #1 and subject #3 led the physician in charge of this ultrasound test to prescribe a blood test to validate the Fibroscan result and to identify any cause of liver disease. It was expected that a modification in the amount of prothrombin or hepatic serology would be found. Contrary to expectation, the results of the blood test were satisfactory. To verify the result obtained with the first Fibroscan, subjects #1 and #3 underwent another Fibroscan. The stiffness measured for subject #3 was back to normal (4.73 ± 0.84 kPa; Fig. 4), while subject #1 still had liver stiffness (6.7 kPa) above the normal rate (6 kPa).

As a result, two different expert physicians realized the Fibroscan test on both volunteers and the Young modulus measured for subject #3 was very different (3.7 kPa) between these two operators. Moreover, the large range of stiffness (subject #3: 5.3–9.5 kPa) recorded with the Fibroscan technique could influence the diagnosis of liver fibrosis. Figure 4 shows a higher standard deviation with the ultrasound elastometry technique compared to the MRE technique, which is not influenced by such parameters (operator, placement of the probe, etc). This result shows that sometimes the Fibroscan could be unreliable.

The total imaging time of acquisition for both techniques was approximately the same. The Fibroscan method needs to measure 10 valid values to have a correct stiffness. These 10 values could take time to record whether the subject has a small intercostal space or abundant subcutaneous tissue. The operator must take time to find an area to place the probe in order to have a correct propagation of the wave inside the liver. The setup of the MRE technique may be longer but once the MRI and MRE sequences are running the stresses obtained with the Fibroscan are not present with the MRE technique. The reproducibility performed on subjects #1, #3, and #5 with both techniques is less for the MRE technique: 0.33 kPa (ultrasound elastometry) and 0.08 kPa (MRE).

DISCUSSION

This study is the first to compare the MRE and Fibroscan techniques on the same subjects. The originality of this study was first to attest the feasibility of MRE to measure liver stiffness and second to show why MRE should be investigated beyond the Fibroscan. The feasibility was proven with similar liver stiffnesses measured between both methods, which demonstrates the capability of the MRE technique to measure liver stiffness.

However, a greater variation of stiffness was found with the Fibroscan compared with the MRE technique. This variation may be related to the thickness of subcutaneous fat above the ribs the blood flow circulation. In addition, the shift of the probe during the exam using Fibroscan may influence the direction of the wave pressure and consequently the liver stiffness measurement. This demonstrates the sensitivity of the Fibroscan technique to local measurements (due to the focalized transducer) which can only evaluate a fragment of hepatic tissue. This large range of stiffness obtained for the same subject may influence the diagnosis of the fibrosis, which should be confirmed with an additional exam. Moreover, patients with ascites or obesity are excluded from the Fibroscan because the shear waves are not clearly propagated due to thick subcutaneous tissues. Conversely, MRE can be performed for different kinds of patients, even with obesity, ascite, etc.

The MRE technique should be investigated further because MRE can evaluate the morphology of the entire hepatic gland and detect possible anomalies, such as liver injury or portal hypertension, within the same examination. Finally, the MRE technique provided elasticity of the entire liver, while the Fibroscan technique provided values of elasticity locally.

REFERENCES

1. Cobbold JF, Morin S, Taylor-Robinson SD. Transient elastography for the assessment of chronic liver disease: ready for the clinic? *World J Gastroenterol* 2007;13:4791–4797.

2. Talwalkar JA, Kurtz DM, Schoenleber SJ, West CP, Montori VM. Ultrasound-based transient elastography for the detection of hepatic fibrosis: systematic review and meta-analysis. *Clin Gastroenterol Hepatol* 2007;5:1214–1220.
3. Coco B, Oliveri F, Maina AM, et al. Transient elastography: a new surrogate marker of liver fibrosis influenced by major changes of transaminases. *J Viral Hepat* 2007;14:360–369.
4. Takeda T, Yasuda T, Nakayama Y, et al. Usefulness of noninvasive transient elastography for assessment of liver fibrosis stage in chronic hepatitis C. *World J Gastroenterol* 2006;12:7768–7773.
5. Pinzani M, Vizzutti F, Arena U, Marra F. Technology insight: noninvasive assessment of liver fibrosis by biochemical scores and elastography. *Nat Clin Pract Gastroenterol Hepatol* 2008;5:95–106.
6. Kim KM, Choi WB, Park SH, et al. Diagnosis of hepatic steatosis and fibrosis by transient elastography in asymptomatic healthy individuals: a prospective study of living related potential liver donors. *J Gastroenterol* 2007;42:382–388.
7. Kruse SA, Rose GH, Glaser KJ, et al. Magnetic resonance elastography of the brain. *Neuroimage* 2008;39:231–237.
8. Ringleb SI, Bensamoun SF, Chen Q, Manduca A, An KN, Ehman RL. Applications of magnetic resonance elastography to healthy and pathologic skeletal muscle. *J Magn Reson Imaging* 2007;25:301–309.
9. Bensamoun SF, Ringleb SI, Chen Q, Ehman RL, An KN, Brennan M. Thigh muscle stiffness assessed with magnetic resonance elastography in hyperthyroid patients before and after medical treatment. *J Magn Reson Imaging* 2007;26:708–713.
10. Rouvière O, Yin M, Dresner MA, et al. MR elastography of the liver: preliminary results. *Radiology* 2006;240:440–448.
11. Huwart L, Peeters F, Sinkus R, et al. Liver fibrosis: non-invasive assessment with MR elastography. *NMR Biomed* 2006;19:173–179.
12. Lewin M, Pujol-Robert A, Boëlle PY, et al. Diffusion-weighted magnetic resonance imaging for the assessment of fibrosis in chronic hepatitis C. *Hepatology* 2007;46:658–665.
13. Yin M, Woollard J, Wang X, et al. Quantitative assessment of hepatic fibrosis in an animal model with magnetic resonance elastography. *Magn Reson Med* 2007;58:346–353.
14. Manduca A, Oliphant TE, Dresner MA, et al. Magnetic resonance elastography: non-invasive mapping of tissue elasticity. *Med Image Anal* 2001;5:237–254.