



HAL
open science

Resection of Selected Invasive Suamous Cell Carcinoma of the Pyriform Sinus by Means of the Lateral Pharyngotomy Approach: the Partial Lateral Pharyngectomy

Floyd Christopher Holsinger, Mehdi Motamed, Dominique Garcia, Daniel Brasnu, Madeleine Ménard, Ollivier Laccourreya

► **To cite this version:**

Floyd Christopher Holsinger, Mehdi Motamed, Dominique Garcia, Daniel Brasnu, Madeleine Ménard, et al.. Resection of Selected Invasive Suamous Cell Carcinoma of the Pyriform Sinus by Means of the Lateral Pharyngotomy Approach: the Partial Lateral Pharyngectomy. *Head & Neck*, 2006, 28, pp.705-11. hal-00198673

HAL Id: hal-00198673

<https://hal.science/hal-00198673>

Submitted on 22 Oct 2021

HAL is a multi-disciplinary open access archive for the deposit and dissemination of scientific research documents, whether they are published or not. The documents may come from teaching and research institutions in France or abroad, or from public or private research centers.

L'archive ouverte pluridisciplinaire **HAL**, est destinée au dépôt et à la diffusion de documents scientifiques de niveau recherche, publiés ou non, émanant des établissements d'enseignement et de recherche français ou étrangers, des laboratoires publics ou privés.



Distributed under a Creative Commons Attribution - NonCommercial 4.0 International License

Lateral pharyngotomy

Ollivier Laccourreye (1)*, Alexandre Villeneuve (1), François Rubin (1), F. Christopher Holsinger (2).

Services d'Otorhinolaryngologie et de Chirurgie Cervico-Faciale

(1) Université Paris Descartes Sorbonne Paris Cité, HEGP, APHP, Assistance Publique des Hôpitaux de Paris, Paris, France

(2) Department of Otorhinolaryngology Head Neck Surgery, Stanford University, Palo Alto, CA, USA.

*** Corresponding author:**

E-mail: ollivier.laccourreye@aphp.fr (Ollivier Laccourreye)

Service ORL, HEGP, 20-40 Rue Leblanc, 75015 Paris, France

Disclosure of Interest:

The authors declare that they have no conflicts of interest concerning this article

Abstract.

Based on a review of the medical literature, the authors document the key technical points, variants, technical errors to avoid and main functional results of lateral pharyngotomy for resection of cancers originating from the lateral oro and/or hypo-pharynx.

Key-words: pharyngotomy, oropharynx, hypopharynx, cancer.

Introduction.

Etymologically, lateral pharyngotomy means sectioning the lateral wall of the pharynx. This approach was first described in 1929 by the British surgeon William Trotter (Figure 1) [1], then modified by several authors, and is recommended in head-and-neck oncology for resecting tumors originating in the hypopharynx (posterior hypopharyngeal wall, lateral pharyngeal wall, lateral aspect of the pyriform sinus) or oropharynx (lateral tongue base, subtonsillar region, glossotonsillar sulcus) [2-14]. With the increasing incidence of oropharyngeal squamous cell carcinoma due to chronic latent infection of the human papilloma virus, there has been renewed interest in this mandible-sparing surgical approach in the last 10 or so years [5-16] – especially in light of growing awareness of the late sequelae of radiotherapy. The present technical note details the key points and technical refinements of this conservative surgical approach as well as the errors to avoid together with the reported functional results.

Technique.

The patient is intubated and a nasogastric tube is inserted. Tracheotomy is performed with a horizontal incision adjacent to the 3rd/4th tracheal ring, separate from the cervicotomy performed from the tip of the mastoid apophysis to Sedillot's triangle, 1 centimeter behind on the anterior edge of the ipsilateral sternocleidomastoid muscle.

The surgical field is exposed after ipsilateral jugulocarotid neck dissection (levels II-IV), performed according to preoperative lymph-node status. The anatomic landmarks comprise: greater horn of the hyoid bone, greater horn of the thyroid cartilage, carotid axis including the origins of the lingual and superior thyroid arteries, and lateral edge of the subhyoid muscles (Figure 2). The hypoglossal nerve is located above the greater horn of the

hyoid bone. The superior thyroid artery is isolated at its origin just cranial to the carotid bulb or external carotid artery (Figure 2). The superior laryngeal nerve is located medially from the bifurcation between the external artery and its second branch (the lingual artery) (Figure 2). Here, in depth, the superior laryngeal nerve runs as a bisector between the two arteries and, after a short inward course, joins the superior laryngeal vessels, which it touches before entering the pre epiglottic space (Figure 2).

The main difficulty in lateral pharyngotomy lies in choosing the entry point. It must be far enough away from the tumor to enable visually guided resection with safe margins. The entry at a safe level is greatly facilitated by deep tattooing (with ink) of the mucosal and muscular periphery of the resection area when performing the preoperative diagnostic endoscopy. Depending on tumor location, four anatomical obstacles are encountered: the hypoglossal nerve, superior laryngeal nerve, lingual artery and superior thyroid artery (Figure 2). Locating and preserving the two nerves, by isolation and bridging (Figure 3) ahead of the opening step is a key to avoiding postoperative complications. Sparing the lingual artery is not mandatory but enables to use a set-back tongue flap for reconstruction if tumor resection involves the ipsilateral tongue base [17]. The superior laryngeal artery is classically transected along with the superior thyroid artery (Figures 3-5), to provide wide exposure of the pharyngeal wall at larynx level. If, however, a pediculated ipsilateral subhyoid muscle flap is considered for closure, the superior thyroid vascular pedicle must imperatively be conserved, sectioning only the superior laryngeal vascular pedicle [18].

After adequate exposure is achieved, the approach depends on 3 possible situations:

1) For tumors on the lateral wall of the pyriform sinus and/or lateral oropharyngeal wall (caudal to the inferior aspect of the tonsillar pillar), the safest entry point is in the inferior

aspect of the ipsilateral vallecula. For easy access, exposure should be extended by using an electrocautery knife to release the digastric muscle tendon, stylohyoid muscles and ligaments, mylohyoid muscle and infrahyoid muscles respectively from the superior and inferior edges of the greater horn of the hyoid bone. Transection the greater horn at the level of the lesser horn (Figures 3, 4) and backward traction then provides visualization of the mucosa of the vallecula immediately overlying the lateral part of the pre-epiglottic space. Horizontal backward incision of the mucosa provides visualization of the exact tumor location and extent. The infrahyoid muscles are then released from the pre epiglottic fossa and separated from the posterior third of the lateral aspect of the thyroid cartilage lamina by incising the external perichondrium horizontally at the superior edge of the thyroid cartilage and vertically forward of the inferior constrictor muscle insertion (Figure 5). The posterior third of the thyroid cartilage lamina, corresponding to the projection of the pyriform sinus, is then incised, using an oscillating saw, to form a cartilage triangle with a superior base. The tip on the inferior edge of the lateral pharyngotomy is located at the level of the previously sectioned lesser horn (Figure 5). In the lower part of the exposure, the junction between the inferior edge of the thyroid lamina and the lesser horn is sectioned, away from the inferior laryngeal nerve and ipsilateral cricothyroid muscle fiber insertion (Figures 5). Anteriorly, the pharyngeal wall of the pyriform sinus is sectioned along the cartilage thyroid lamina section. Resection spares the previously isolated superior laryngeal nerve, which is bridged outside of the surgical specimen (Figures 4,5). Then, under direct visualization, the inferior constrictor muscles are incised vertically behind the posterior edge of the ipsilateral thyroid cartilage plate (Figure 5).

2) In tumor originating from the tongue-base and/or glossotonsillar fold, the posterior digastric belly and stylohyoid muscles and ligament are sectioned from the lesser horn of the hyoid bone and inclined backward, providing visualization of the styloglossus muscle

insertion in the tongue base (Figures 3,4). The facial artery is isolated, sectioned and ligated at its entry into the posterior part of the submaxillary space, enabling the ipsilateral submaxillary gland to be pushed forward (Figures 3,4). The mylohyoid muscle insertion on the posterior third of the greater horn of the hyoid bone is sectioned (Figures 3,4). The first branch of the lingual artery, issuing from its superior side, is ligated and sectioned (Figure 4). Lateral pharyngotomy is then performed on the posterior edge of the greater horn of the hyoid bone, using an 11-mm cold blade, for 1 cm through the medial constrictor muscle fibers. The hyoid bone is then sectioned at the junction between the lesser and greater horns. The lateral pharyngotomy is then extended horizontally inward to the inferior edge of the greater horn, providing visualization of the whole tongue base and ipsilateral glossotonsillar fold. This step may require isolating the ipsilateral hypoglossal nerve, conserved as a bridge, as done with the superior laryngeal nerve (Figures 3,4). If visualization is restricted, the field can be enlarged, either by partially resecting the mandibular angle [8], or by incising the oral floor forward after dissecting the ipsilateral Ib area and connecting the resulting incision in the oral cavity to the pharyngotomy as such [9]. This approach can also be very easily associated in the upper part (at the styloglossus muscle level) to a transoral lateral oropharyngectomy [19], if the tonsillar fossa has to be resected to achieve safe margins.

3) In posterior pharyngeal wall tumor, it is not necessary to section the greater horn of the hyoid bone or release the sub- and supra-hyoid muscles from the hyoid bone. Using a hook at the end of the greater horn of the thyroid cartilage, the assistant applies traction to rotate and raise the larynx. Lateral pharyngotomy is then performed on the posterior edge of the greater horn of the thyroid cartilage, using an 11-mm cold blade. The risk here is of getting lost in the inferior constrictor muscle fibers, and this muscle plane should be punctured perpendicularly, using the full length of the blade. Under visual control, the lateral pharyngotomy is then enlarged upward so as to visualize the whole of the affected posterior

pharyngeal wall while respecting the great hypoglossal nerve, lingual artery and superior laryngeal nerve, only the last of which is usually isolated (Figure 6). The posterior pharyngeal wall is then released from the prevertebral plane and traction is exerted to allow resection remote from the tumor, while sparing the superior laryngeal nerve.

Except in lateral pharyngotomy for posterior pharyngeal wall tumor, closure is performed either by simply approximating the remaining pharyngeal wall and suturing it down to the tongue base, vallecula and lateral wall of the pyriform sinus covered by the conserved ipsilateral infra-hyoid muscles, or, if this is not possible, using various local flaps, pediculated remote flaps or free flaps [6,9-11,13,17,18]. In posterior pharyngeal wall tumor, depending on defect size, 3 attitudes are possible: release of the remaining end of the posterior pharyngeal wall from the vertebral plane and suture onto the remaining lateral pharyngeal wall, directed healing in first line after suture of the conserved lateral pharyngeal wall to the prevertebral aponeurosis, or use of a flap.

The procedure ends with the usual check for hemostasis, placement of a wound drainage catheter, subcutaneous, cutaneous closure, and non-compressive dressing while a cuffed tracheostomy canula is inserted

Discussion.

“Modern” lateral pharyngotomy differs from the approach described by William Trotter in 1929 [1] (Figure 1) in that the topography of the transpharyngeal incision is adapted to tumoral topography, preferably guided by tattooing the resection contour during diagnostic endoscopy. Most important, the current concept of the operation preserves the ipsilateral hypoglossal and superior laryngeal nerves as well as mandibular continuity.

Sparing the ipsilateral great hypoglossal and superior laryngeal nerves is a recognized key-point for swallowing, as they coordinate the sensation and propulsion of the food bolus within the oropharynx and hypopharynx under laryngeal occlusion [20]. Studies of functional results in lateral pharyngotomy for cancer of pharyngeal origin highlight the benefit of conserving these nerves. In the largest published cohort, of 91 patients with invasive squamous cell carcinoma of the lateral oropharynx treated by lateral pharyngotomy, with follow-up of at least 5 years or until death, the authors reported postoperative onset of severe swallowing disorder and inhalation pneumopathy in only 6.3% and 4.3% of cases respectively, with only 1 permanent gastrostomy [13]. They also highlighted the rarity of salivary fistula, noted in 4.3% of cases, but emphasized the severity of potential complications, incurring the only perioperative death from surgical causes [13]. Results are similar whether the pharyngotomy was at the hypopharynx [6,7,12] or greatly extended by combining incision of the pharynx, hypopharynx and oral floor or transoral resection of the tonsillar region [8-11], highlighting the importance of the steps involved in locating, isolating and conserving the great hypoglossal and superior laryngeal nerves (Figures 2-4). It also seems that performing a flap at closure does not jeopardize these functional results so long as a half-base of the mobile tongue is conserved [9-12]; the set-back tongue flap, with conserved ipsilateral lingual artery, described by Schechter et al. in 1980 [17], is of great interest here. Finally, the functional results of lateral pharyngotomy in terms of swallowing are altogether comparable to those of chemoradiation [21,22]. Conserving mandibular integrity is another very important point in favor of “modern” lateral pharyngotomy. The literature confirms the functionally deleterious nature of mandibulotomy in “conservative” surgery for oropharyngeal cancer, with severe local complications in one in five cases, over and above dental issues, fusion defects, restricted oral opening and malocclusion, the rate and severity of all of which are increased by postoperative radiation therapy [23,24]. Simple resection of the mandibular

angle, without mandibulotomy, as described by Cocek et al. [8] to improve visualization of tumor margins, seems not to induce the complications incurred by mandibulotomy.

Acknowledgments: The authors thank the Progrès 2000 association for technical support.

References.

- 1 Trotter W. Operations for malignant disease of the pharynx. *British Journal of Surgery* 1929;16:485-495.
- 2 Harris PF, Rosenfeld L, Ward PH. Lateral pharyngotomy approach for lesions of the base of the tongue, pharynx and larynx. *South Med J* 1968; 61:1276-80.
- 3 Stern SJ. Anatomy of the lateral pharyngotomy approach. *Head Neck* 1992;14: 153-156.
- 4 Byers R.M. Anatomic correlates in head neck surgery. The lateral pharyngotomy. *Head Neck* 1994;16:460-463.
- 5 Ogura JH, Watson RK, Jurema AA. Partial pharyngectomy and neck dissection for posterior hypopharyngeal cancer. Immediate reconstruction with preservation of voice. *Laryngoscope*. 1960;70:1523-1534.
- 6 Steinhart H, Constantinidis J, Iro H. Larynx preserving surgery in carcinomas of the posterior hypopharyngeal wall by reconstruction with a free flap. *HNO* 1998; 46:135-139.
- 7 Holsinger FCh, Motamed M, Garcia D, Brasnu D, Ménard M, Laccourreye O. Resection of selected invasive squamous cell carcinoma of the pyriform sinus mean of the lateral pharyngotomy approach: the partial lateral pharyngectomy. *Head Neck* 2006;28:705-711.

- 8 Cocek A, Pru I, Hahn C, Hahn A. Lateral pharyngotomy extended by resection of the mandibular angle an alternative approach to the surgical treatment of oropharyngeal (tonsillar) cancers. *Acta Oto-Laryngologica* 2009;129:318-323
- 9 Laccourreye O, Seccia V, Ménard M, Garcia D, Vacher Ch, Holsinger FCh. Extended lateral pharyngotomy for selected squamous cell carcinoma of the lateral tongue base. *Ann Otol Rhinol Laryngol* 2009;118:428-434.
- 10 Bozec A, Poissonnet G, Chamorey E, et al. Transoral and cervical approach without mandibulotomy for oropharynx cancer with fasciocutaneous radial forearm free flap reconstruction. *Ann Otolaryngol Chir Cervicofac* 2009;126:182-189.
- 11 Masuda M, Fukushima J, Kadota H, Kamizono K, Ejima M, Taura M. Mandible preserving pull-through oropharyngectomy for advanced oropharyngeal cancer: a pilot study. *Auris Nasus Larynx* 2011;38:392-397.
- 12 Lim YC, Jeong HM, Shin HA, Choi EC. Larynx-preserving partial pharyngectomy via lateral pharyngotomy for the treatment of small (T1~2) hypopharyngeal squamous cell carcinoma. *Clin Exp Otorhinolaryngol* 2011;4:44-48.
- 13 Laccourreye O, Benito J, Ménard M, Garcia D, Malinvaud D, Holsinger FCh. Lateral pharyngotomy in patients with selected squamous cell carcinoma of the lateral oropharynx. Part I : How. *Laryngoscope* 2013;123:12-17.
- 14 Laccourreye O, Benito J, Garcia D, Ménard M, Bonfils P, Holsinger FCh. Lateral pharyngotomy for selected invasive squamous cell carcinoma of the lateral oropharynx - Part II : When and Why ? *Laryngoscope* 2013;123:18-22.
- 15 Remmert C, Mansour N, Hofauer B' et al. Pharyngotomy in head and neck squamous cell carcinoma: functional and oncological aspects. *Acta Otolaryngol* 2017;137:1281-1287.

- 16 Bertolin A, Ghirardo G, Lionello M, Giacomelli L, Lucioni M, Rizzotto G. Lateral pharyngotomy approach in the treatment of oropharyngeal carcinoma. *Eur Arch Otorhinolaryngol* 2017;274:2573-2580.
- 17 Schechter GL, Sly DE, Roper AL 2nd, Jackson RT, Bumatay J. Set-back tongue flap for carcinoma of the tongue base. *Arch Otolaryngol* 1980;106:668-671.
- 18 Deganello A, Leemans CR. The infrahyoid flap: a comprehensive review of an often overlooked reconstructive method. *Oral Oncol* 2014;50:704-710.
- 19 Rubin F, Laccourreye O, Weisntein GS, Holsinger F Ch. Transoral lateral oropharyngectomy. *Eur Ann Otorhinolaryngol Head Neck Dis* 2017;134:419-422.
- 20 Jafari S, Prince RA, Kim DY, Paydarfar D. Sensory regulation of swallowing and airway protection: a role for the internal superior laryngeal nerve in humans. *J Physiol* 2003;550:287-304.
- 21 Nguyen NP, Franck MA, Moltz CC, et al. Analysis of factors influencing aspiration risk following chemoradiation for oropharyngeal cancer. *Br J Radiol* 2009;82:675-680.
- 22 Shiley SG, Hargunani CA, Skoner JM, Holland JM, Wax MK. Swallowing function after chemoradiation for advanced stage oropharyngeal cancer. *Otolaryngol Head Neck Surg* 2006;134:455-459.
- 23 Parsons JT, Mendenhall WM, Stringer SP, et al. Squamous cell carcinoma of the oropharynx: surgery, radiation therapy or both. *Cancer* 2002;94:2967-2980.
- 24 Diaz-Molina J, P, Rodrigo JP, Alvarez-Marcos C, Llorente JL, Costales M, Suarez C. Oncological results after surgical treatment of squamous cell cancer of the lateral wall of the oropharynx. *Laryngoscope* 2011;121:1449-1454.

Legends for Figures

Figure 1: Trotter's total lateral pharyngotomy (from Trotter W. Operations for malignant disease of the pharynx. British Journal of Surgery 1929;16:485-95).

Figure 2: Surgical field and main anatomic structures, with the 4 neurovascular elements barring access to the pharynx: great hypoglossal nerve, lingual artery, superior thyroid artery and superior laryngeal nerve.

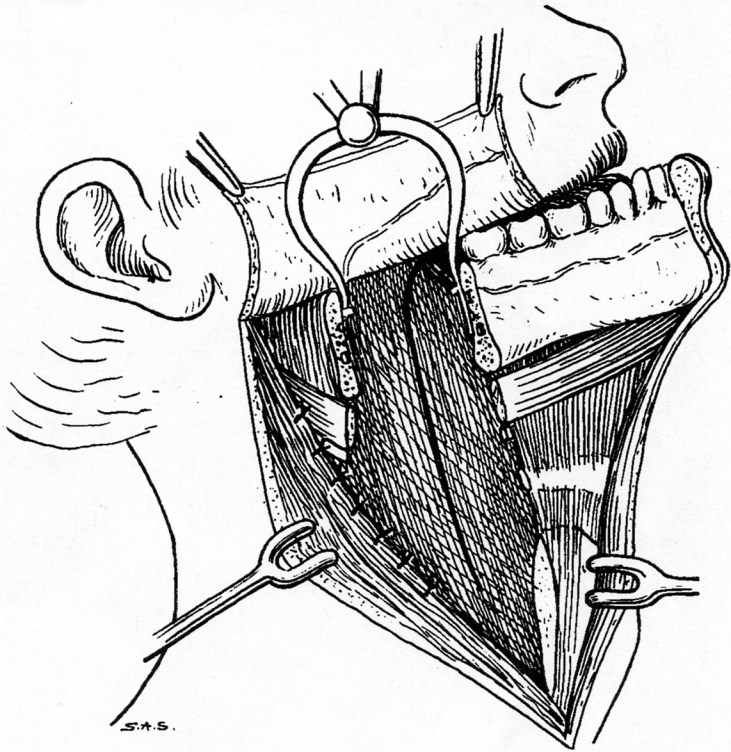
Figure 3: The 3 main neurovascular structures (hypoglossal nerve, lingual artery, superior laryngeal nerve), the thyroid and superior laryngeal pedicles having been ligated and sectioned. The posterior belly of the digastric muscle, mylohyoid muscle and infra-hyoid muscle are released from respectively the superior and inferior edges of the greater horn of the hyoid bone. The subhyoid muscles are separated from the pre epiglottic space and posterior third of the thyroid cartilage plate by incising the lateral perichondrium.

Figure 4: Isolation by forceps of the 3 main neurovascular structures (great hypoglossal nerve, lingual artery, superior laryngeal nerve) and separation of the lateral pharyngeal wall from the jugulocarotid vascular plane. Scissors pointing toward to prevertebral plane.

Figure 5: The 3 possible entry points: 1) through the hyoid bone, at the junction between the lesser and greater horns; 2) through the thyroid cartilage; 3) through the constrictor muscles, at the posterior edge of the thyroid wing. Dotted lines indicate possible resection of the whole lateral pharyngeal wall, from the back of the pyriform sinus below up to the inferior pole of the tonsil, where the styloglossus muscle is sectioned.

Figure 6: Anatomic dissection on fresh cadaver, visualizing a lateral pharyngotomy for posterior pharyngeal wall cancer, performed at the posterior edge of the thyroid wing, indicated by 2 Halsted forceps, with scissors pointing toward the posterior pharyngeal wall (1) while pushing back the superior laryngeal nerve (2) isolated and bridged, the forceps gripping the epiglottis. Above, and not isolated: lingual artery (3) and great hypoglossal nerve (4),

crossing above the internal (5) and external (6) carotid arteries. The superior thyroid artery (7) is preserved. The digastric muscle tendon (8) is not released from the greater horn of the hyoid bone; likewise, the infrahyoid muscles (9) are not released from the pre epiglottic space (10).



S.A.S.

