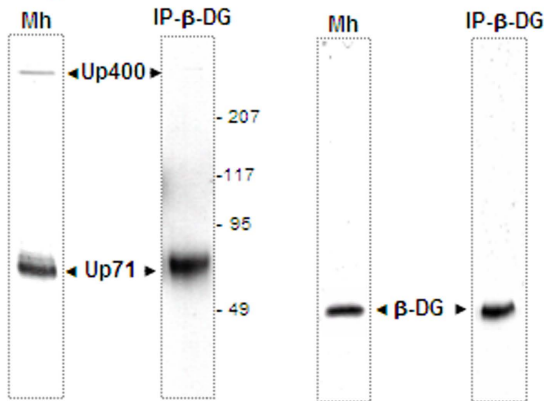


## A) Diaphragm



## B) Tibialis anterioris

